

World Small Animal Veterinary Association Global Dental Guidelines

Authors:

Brook A. Niemiec DAVDC, DEVDC, FAVD (USA), Jerzy Gawor DAVDC, DEVDC, FAVD (Poland), Ana Nemec DAVDC, DEVDC (Slovenia), David Clarke DAVDC (Australia), Cedric Tutt, DEVDC (South Africa), Marco Gioso DAVDC (Brazil), Paulo Stegall DACVAA (Canada), Marge Chandler DACVN, DACVIM, DECVIM-CA (UK), Gottfried Morgenegg (Switzerland), Rod Jouppi (Canada), Kymberley Stewart (Canada)

Abstract

Dental, oral, and maxillofacial diseases are by far the most common problem facing small animal practice. These conditions create significant pain, as well as localized and potentially systemic infection. As such, the World Small Animal Veterinary Association believes that un- and under treated dental disease poses a significant animal welfare concern. Dentistry is an area of veterinary medicine which is still widely ignored and is subject to many myths and misconceptions. Effective teaching of veterinary dentistry in the veterinary school is the key to progression in this field of veterinary medicine.

These guidelines were developed to provide veterinarians with the information required to understand best practices for dental therapy and create realistic minimum standards of care. Using the three-tiered continuing education system of WSAVA, the guidelines make global equipment and therapeutic recommendations and highlight the anaesthetic and welfare requirements for small animal patients. Collaborating on this document are veterinary dentists from 5 continents as well as members of the WSAVA Pain Management, Nutrition, and Welfare guideline committees.

This document contains information on common oral pathology and treatment, periodontal therapy, extractions, and dental radiography and radiology. Also included is an easily implementable and repeatable scoring system for dental health. Further, we have sections on anaesthesia and pain management for dental procedures, home dental care, nutritional information, and recommendations on the role of the universities in improving veterinary dentistry. Included is a discussion of the deleterious effects of anesthesia-free (AFD) or non-anesthetic dentistry (NAD), which is ineffective at best and damaging at worst. Throughout the document the negative effects of undiagnosed and/or treated dental disease on the health and well-being of our patients, and how this equates to an animal welfare issue, is discussed.

Introduction

The World Small Animal Veterinary Association (WSAVA) is an ‘association of associations’ with over 200,000 small animal veterinarians globally represented by over 101 member associations. Global guidelines on pain management, vaccine selection and usage, the recognition, diagnosis and treatment of hepatic, gastrointestinal, and renal disease, and nutrition all have been released by the WSAVA to guide and assist practitioners as the global voice of the small animal veterinary community. Utilizing guidelines assists the entire healthcare team to understand, embrace, and enact practice standards to improve quality of care for all patients.

Like those before it, the Global Dental Standardization Guidelines committee was established to develop a universally relevant document that would take into consideration the world-wide differences in educational background, access to equipment and drugs, as well as treatment modalities of its members. Uniquely, this guidelines committee encompasses members from incredibly diverse veterinary specialties, which truly emphasizes the multimodal approach that dental health deserves. Authors representing advanced training in dentistry, nutrition, anaesthesia, analgesia, and animal welfare have come together to each highlight the importance of dental disease treatment and prevention for our patients from various area of veterinary care.

The WSAVA sincerely hopes these guidelines will empower members of the global healthcare team to recognize and treat dental disease, further promote and guide inclusion of dentistry in the veterinary university curriculum, and increase the level of confidence in the need for proper veterinary dental care for patients world-wide.

Use of this document

Dental disease knows no geographical boundaries, and as such the guidelines were developed to assist practitioners from around the world. The only limiting factors are awareness of its prevalence or impact on our patient’s health and welfare, education on the subject, and a commitment to include dental assessment in every physical examination. These guidelines were created with easy to implement fundamentals at their core. Their purpose is to guide the general practitioner towards successful detection, diagnosis and therapy of the most common dental conditions. This is not intended as a text to teach technique nor as a replacement for clinical judgment. While continued research is required in all areas represented in these guidelines, a distinct effort has been made to provide peer reviewed evidence-based recommendations in all areas. Each section contains an extensive reference list should the practitioner require additional information. There is additional reference material available on the WSAVA website (www.wsava.org).

Tiering where appropriate should be used to guide the practitioner to minimum acceptable practices in their represented countries, but is by no means meant to recommend an interested practitioner stop there in their provision of service, or pursuit of educational goals. Acknowledgement of the vast differences in the availability of analgesic and anaesthetic drugs is made, and practitioners are guided to the Global Pain Council’s guidelines (2013) available in JSAP and on the WSAVA website for further guidance.

Table of Contents:

Section 1: Oral anatomy and Common Pathology

- a) **Oral and Dental anatomy and physiology**
- b) **Periodontal Disease**
- c) **Common disorders of the teeth**
- d) **Tooth Resorption**
- e) **Maxillofacial Trauma**
- f) **Oral Tumors**
- g) **Malocclusions**

Section 2: Animal Welfare issues concerning dental health

Section 3: Anesthesia and Pain management

Section 4: Oral Examination and Recording

Section 5: Periodontal Therapy

- a) **Basic Periodontal Therapy**
- b) **Dental Homecare**
 - a. **Active**
 - b. **Passive**

Section 6: Dental Radiology

Section 7: Dental Extractions

Section 8: The University's role in dental education

Section 9: Necessary equipment

Section 1: Oral Anatomy and Common Pathology

Oral and Dental anatomy and physiology

Knowledge and understanding of oral and dental anatomy and physiology, as well as basic embryology, is key to understanding disease processes and other abnormalities of the oral cavity and teeth. In addition, it is important for planning appropriate diagnostic procedures and therapy.

Bones of the maxilla and mandible

The upper jaw consists of paired maxillae and incisive bones. Their alveolar processes contain alveoli for the incisor (incisive bone), canine, premolar and molar teeth (maxillary bone). The lower jaw is formed by the two mandibles which are joined at the symphysis. Each mandible has a body with the alveoli for incisor, canine, premolar and molar teeth, and a ramus consisting of the angular, coronoid and condylar processes. The condylar process of the mandibular ramus articulates with the temporal bone at the temporomandibular joint. (Evans and de Lahunta 2013, Lewis and Reiter 2010)

There are six clinically important foramina in the jaws:

- maxillary foramen: directly dorsal to the caudal aspect of the maxillary fourth premolar tooth; this is the entrance for the infraorbital nerve and blood vessels into the infraorbital canal,
- infraorbital foramen: dorsal to the interdental space of the third and fourth maxillary premolar tooth; this is where the infraorbital nerve and blood vessels exit the infraorbital canal,
- mandibular foramen: on the medial surface of the mandibular ramus; this is the caudal opening of the mandibular canal and serves as the entrance for the inferior alveolar nerve and blood vessels into the mandibular canal,
- caudal, middle and rostral mental foramina: these are the rostral openings of the mandibular canal. The caudal one exits at the level of the mesial root of the mandibular third premolar, the middle at the mesial root of the second premolar, and the rostral at the second incisor teeth. The caudal and middle foramina may coalesce into one. (Evans and de Lahunta 2013, Lewis and Reiter 2010)

Innervation, blood supply and muscles of mastication

Innervation of the maxillofacial region, oral cavity and tongue is provided by the trigeminal nerve (V), facial nerve (VII), glossopharyngeal nerve (IX), vagus (X) and hypoglossal nerve (XII). Blood supply comes through the maxillary artery. The branches of the maxillary artery which are most commonly encountered during oral and maxillofacial surgery are the minor palatine artery, infraorbital artery, descending palatine artery (this later gives rise to the major palatine and sphenopalatine arteries) and inferior alveolar artery. (Evans and de Lahunta 2013, Lewis and Reiter 2010)

There are four groups of muscles of mastication – masseter, temporal, lateral and medial pterygoid, and digastricus. Apart from the digastricus, which opens the mouth, the other three muscle groups close the mouth. (Evans and de Lahunta 2013, Lewis and Reiter 2010)

Saliva

Oral fluid (mixed saliva) is formed by secretions of the major salivary glands (parotid gland, mandibular gland, sublingual gland and zygomatic gland in the dog, plus a lingual molar salivary gland in the cat), minor glands, desquamated oral epithelial cells, microorganisms and their byproducts, food debris, and serum components and inflammatory cells from the gingival crevice. Normal production of saliva is of extreme importance for oral health. (Lewis and Reiter 2010, Nanci 2008)

Lymph drainage

There are three lymph centers draining the oral cavity, head and neck. These are the parotid mandibular (with buccal lymph nodes) and retropharyngeal lymph centers. Pathways of lymphatic drainage are unpredictable, but the main lymph draining center for the head is the retropharyngeal lymph center, which consists of a medial and sometimes a lateral lymph node. (Skinner et al. 2016, Evans and de Lahunta 2013, Lewis and Reiter 2010)

Oral cavity proper and dentition

The limits of the oral cavity proper are the hard and soft palate dorsally, the dental arcades and teeth rostrally and laterally, and the floor of the oral cavity consisting of the tongue and ventral oral mucosa. The teeth are located in the upper and lower dental arches, each consisting of two quadrants.

When using the modified Triadan system to describe the dentition in an adult animal, the right maxilla is quadrant one, left maxilla is quadrant two, left mandible is quadrant three, and right mandible is quadrant four. The dental formula of a dog is $2x I 3/3 : C 1/1 : P 4/4 : M 2/3 = 42$. In puppies the dental formula is $2x i 3/3 : c 1/1 : p 3/3 = 28$, in adult cats $2x I 3/3 : C 1/1 : P 3/2 : M 1/1 = 30$, and kittens $2x 3/3 : c 1/1 : p 3/2 = 26$.

The occlusion describes how the teeth meet and six points should be evaluated – incisor, canine, premolar, and caudal premolar/molar teeth occlusion, as well as head symmetry, and the presence/position of the individual teeth. (AVDC Nomenclature Committee 2017, Verstraete 2011, Lewis and Reiter 2010)

Dogs and cats have diphyodont (two generations of teeth), anelodont (teeth do not grow continuously), brachyodont (roots are longer than crowns and crowns are fully covered by enamel) dentition. Permanent incisor teeth are small single-rooted teeth. Canine teeth are the largest single-rooted teeth. The apex of the mandibular canine tooth lies lingual to the mental foramen and occupies a large portion of the mandible. There is only a thin plate of bone between the root of the maxillary canine tooth and the nasal cavity, therefore this is a common location for oronasal fistulation.

In dogs, the premolar teeth vary in size and number of roots. First premolar teeth (maxillary and mandibular) are small, single-rooted teeth, the maxillary fourth premolar tooth is a large three-rooted tooth, and the rest of the premolar teeth are two-rooted. Roots of individual maxillary premolar and molar teeth are close to the infraorbital canal, nasal cavity and orbit. Maxillary molar teeth in the dog are three rooted with a flat occlusal surface palatally. The mandibular first molar is a large two rooted tooth with roots close to the mandibular canal (AVDC Nomenclature Committee 2017, Verstraete 2011, Lewis and Reiter 2010). In small dogs, the mandibular first molar tooth is proportionally larger relative to the mandibular height compared to larger dogs (Gioso *et al.* 2001). The mandibular second and third molar teeth are similar, with the second having two roots and the third one root.

In cats, the the maxillary second premolar tooth is a small, single-rooted tooth (rarely two-rooted). The maxillary third premolar tooth is a two-rooted (possibly three-rooted) tooth, and there is a larger three-rooted maxillary fourth premolar tooth. The mandible bears only two (third and fourth) premolar teeth with two roots each, which lie close to the mandibular canal.

There is a small single-rooted or two-rooted maxillary molar tooth and a large two-rooted mandibular molar tooth in the cat. For the most part, the two-rooted teeth are symmetrical with roots being relatively the same size. A notable exception to this is the mandibular first molar, which has a large mesial and very small distal root. (Niemic BA 2014)

Deciduous teeth are smaller, slimmer and sharper compared to the permanent teeth, however they have proportionally longer roots. (Verstraete 2011, Lewis and Reiter 2010)

Structure of the teeth and tooth supporting apparatus

The majority of the (adult) tooth is comprised of dentin, which is formed by odontoblasts at the periphery of the pulp. Primary dentin is formed during tooth development, while secondary dentin is laid down after root formation is complete and signifies normal aging of the tooth. Tertiary dentin is formed as an attempt at repair. The central portion of the tooth (pulp cavity) is occupied by dental pulp. Dental pulp contains nerves, blood and lymphatic vessels, connective tissue and odontoblasts. Dental pulp communicates in dogs and cats with the periodontal ligament at the apical delta and lateral canals in adult animals. In young animals, the apical opening is large and it closes into an apical delta in the process of apexogenesis. The coronal portion of the tooth is covered by enamel, which is the hardest and most mineralized tissue in the body. Enamel is formed by ameloblasts only prior to the tooth eruption. (Verstraete 2011, Lewis and Reiter 2010, Nanci 2008, Pashley and Liewehr 2006) Enamel thickness varies from 0.1mm-1mm in cats and dogs. (Crossley 1995) The root of the tooth is covered by cementum, which is mineralized connective tissue similar to bone, formed by cementoblasts. (Verstraete 2011, Lewis and Reiter 2010, Nanci 2008, Pashley and Liewehr 2006)

The tooth supporting apparatus is the periodontium, which consists of the gingiva, periodontal ligament, cementum and alveolar bone. Gingiva is divided into attached and free parts. The gingival sulcus is the area between the tooth and the free gingiva and it's normal depth is 0 – 1 mm in cats and 0 – 3 mm in dogs. The floor of the gingival sulcus is formed by junctional epithelium. Below it lies the major connective tissue attachment of the tooth – the periodontal ligament. The periodontal ligament is anchored into the cementum on one side and the alveolar bone on the other and thus holds the tooth in the alveolus. (Verstraete 2011, Lewis and Reiter 2010, Wolf et al. 2005)

Key Points:

- Knowledge and understanding of oral and dental anatomy, physiology, and basic embryology is the key to understanding disease processes and other abnormalities of the maxillofacial region, oral cavity and teeth
- Proper diagnostic techniques and treatment are impossible to achieve without excellent basic anatomy and physiology knowledge
- Basic anatomy and physiology knowledge includes knowledge of the structure and function of the maxillofacial bones, muscles of mastication, innervation and vascularisation, lymph drainage, salivary glands, oral cavity proper and dentition (including structure of the teeth and tooth supporting apparatus)

References

- AVDC Nomenclature Committee (2017) Dental and periodontal anatomy. http://www.avdc.org/Nomenclature/Nomen-Dental_Anatomy#toothanatomy [accessed 12 February 2017].
- Crossley, D.A. (1995) Tooth enamel thickness in the mature dentition of domestic dogs and cats- preliminary study. *Journal of Veterinary Dentistry* 12(3): 111-113.
- Evans, H.E., de Lahunta, A. (2013) Miller's anatomy of the dog. 4th edn. Elsevier Saunders, St. Louis. 80-113, 197-200, 428-456, 541-545, 708-730.
- Gioso, M.A., Shofer, F., Barros, P.S., Harvey, C.E. (2001) Mandible and mandibular first molar tooth measurements in dogs: relationship of radiographic height to body weight. *Journal of Veterinary Dentistry* 18(2): 65-68.
- Lewis, J.R., Reiter, A.M. (2010) Anatomy and physiology. In: Small animal dental, oral & maxillofacial disease. Ed B.A. Niemiec. CRC Press, Taylor & Francis Group, Boca Raton. 9-38.
- Nanci, A. (2008) Ten Cate's oral histology. Development, structure and function. 7th edn. Mosby Elsevier, St. Louis. pp 1-15, 141-318.
- Niemiec BA: Dental Extractions Made Easier. San Diego, Practical Veterinary Publishing, 2014.
- Pashley, D.H., Liewehr, F.R. (2006) Structure and functions of the dentin-pulp complex. In: Pathways of the pulp. 9th edn. Eds S. Cohen and K.M. Hargreaves. Mosby Elsevier, St. Louis. pp.460-513.
- Verstraete, F.J.M. (2011) Small animal dentistry syllabus VSR413 – Winter 2011. Department of surgical and radiological sciences, School of veterinary medicine, University of California-Davis, Davis. 4-14, 22-31.
- Wolf, H.F., Rateitschak, E.M., Rateitschak, K.H., Hassel, T.M. (2005) Color atlas of Dental Medicine: Periodontology. 3rd edn. Thieme, Stuttgart. 7-20.
- Skinner, O.P., Boston, S.E., Souza, C.H. (2016) Patterns of lymph node metastasis identified following bilateral mandibular and medial retropharyngeal lymphadenectomy in 31 dogs with malignancies of the head. *Veterinary and Comparative Oncology* doi: 10.1111/vco.12229

Periodontal Disease

Introduction

Periodontal disease is by far the number one health problem in small animal patients. (Lund Em *et al.* 1999; University of Minn 1996). By two years of age, 70% of cats and 80% of dogs have some form of periodontal disease (Wiggs RB & Lobprise HB 1997, Marshall 2014). Small and toy breed dogs are particularly susceptible (Hoffmann TH & Gaengler P 1996).

Despite its prevalence, periodontal disease is grossly underdiagnosed. This is partially due to lack of education, but mostly because there are few to no outward clinical signs. Therefore, therapy typically comes very late in the course of disease, if ever. Consequently, periodontal disease may also be the most undertreated disease in our patients. This lack of diagnosis and prompt therapy is concerning as unchecked periodontal disease has numerous local and potentially systemic consequences. Local consequences include oronasal fistulas, class II perio-endo lesions, pathologic fractures, ocular problems, osteomyelitis, and possibly an increased incidence of oral cancer (Niemic BA 2012, DeBowes LJ 2010, Niemic BA 2010). Systemic diseases, which have been linked to periodontal disease, include renal, hepatic, pulmonary, and cardiac diseases, osteoporosis, arthritis, adverse pregnancy effects, and diabetes (Niemic BA 2012).

Pathogenesis

Periodontal disease is generally described in two stages: gingivitis and periodontitis. Gingivitis is the initial, reversible stage in which the inflammation is confined to the gingiva. The gingival inflammation is created by microorganisms in the dental plaque and may be reversed with a thorough dental prophylaxis and consistent homecare (DeBowes LJ 2010; Loe H *et al* 1965; Silness J & Low H 1964). Periodontitis is the later stage and is defined as an inflammatory disease of the deeper supporting structures of the tooth (periodontal ligament, cementum and alveolar bone) caused by microorganisms (Armitage GC 1999; Novak MJ 2006, DeBowes LJ 2010). The inflammation results in the progressive destruction of the periodontal tissues, leading to attachment loss (Wiggs RB & Lobprise HB 1997). This can be observed as gingival recession, periodontal pocket formation, or both. Furthermore, periodontal bone loss is irreversible without advanced regenerative surgery (Shoukry M *et al* 2007; DeBowes LJ 2010). Although the bone loss is irreversible, it is possible to arrest its progression but more difficult to maintain periodontally diseased teeth. It is important to note that periodontal attachment (i.e. bone) loss may be present with or without active inflammation.

Periodontal disease is initiated by oral bacteria which adhere to the teeth in a substance called plaque (Quirynen M *et al* 2006; Wiggs RB & Lobprise HB 1997, Lindhe J *et al* 1975; Boyce EN 1995). Plaque is a biofilm which is made up almost entirely of oral bacteria, contained in a matrix composed of salivary glycoproteins and extracellular polysaccharides (Quirynen M *et al* 2006; Socransky SS 2000; DuPont GA 1997). Plaque will attach to clean teeth within 24 hours if not disturbed. Periodontal disease is initiated not by increasing numbers of bacteria, but in the shift from a gram positive to gram negative population. It is this change in bacterial species that results in the initiation of gingivitis (Quirynen M *et al* 2006). Although the disease process is histologically similar between humans and dogs, differences between human and canine dental plaque formation and composition have recently been described. (Holcombe *et al.* 2014)

However, the oral microbiome will return to normal within a few days if a plaque control regimen is established, resulting in the resolution of gingivitis (Loe H et al 1965; Silness J & Low H 1964). Plaque and calculus may contain up to 100,000,000,000 (10^{12}) bacteria per gram (Socransky SS et al 2000, Quirynen M et al 2006). More importantly, bacteria within a biofilm are 1,000 to 1,500 times more resistant to antibiotics and concentrations of antiseptics up to 500,000 times that which would kill singular bacteria (Williams JE 1995; Quirynen M et al 2006, Socransky SS et al 2000; Elder MJ et al 1995).

Plaque on the visible tooth surface is known as supragingival plaque (Quirynen M et al 2006; Wiggs RB & Lobprise HB 1997). Once it extends under the free gingival margin and into the area known as the gingival sulcus (between the gingiva and the teeth or alveolar bone), it is called subgingival plaque (Quirynen M et al 2006; Niemiec BA 2008). Supragingival plaque likely affects the pathogenicity of the subgingival plaque in the early stages of periodontal disease. However once the periodontal pocket forms, the effect of the supragingival plaque and calculus is minimal (Quirynen M et al 2006). Therefore, control of supragingival plaque alone is ineffective in controlling the progression of periodontal disease (Westfelt E et al 1998, Niemiec BA 1998, DeBowes LJ 2010).

Calculus (or tartar) is plaque which has secondarily become mineralized by the minerals in saliva. Calculus in and of itself is relatively non-pathogenic, providing mostly an irritant effect (Hinrichs JE 2006; Wiggs RB & Lobprise HB 1997, Niemiec BA 2008). The bacteria in the subgingival plaque excrete toxins and metabolic products which create inflammation of the gingival and periodontal tissues (Wiggs RB & Lobprise HB 1997; Harvey CE & Emily PP 1993). This inflammation causes damage to the gingival tissues and initially results in gingivitis. Eventually, the inflammation can lead to periodontitis, i.e. the destruction of the attachment between the periodontal tissues and the teeth. In addition to directly creating tissue damage, the bacterial metabolic byproducts also elicit an inflammatory response from the animal. White blood cells and other inflammatory mediators migrate out of the periodontal soft tissues and into the periodontal space due to increased vascular permeability and increased space between the crevicular epithelial cells. When released into the sulcus, these enzymes will cause further inflammation of the delicate gingival and periodontal tissues. The progression of periodontal disease is determined by the virulence of the bacteria combined with the host response (Nisengard RJ et al 2006). It is the host response that often damages the periodontal tissues (Lang NP 2002; Thoden Van Velzen SK et al 1984; Scannapieco FA et al 2004).

The inflammation produced by the combination of the subgingival bacteria and the host response damages the soft tissue attachment of the tooth, and decreases the bony support via osteoclastic activity. This causes loss of periodontal attachment of the tooth in an apical direction (towards the root tip). The end stage of periodontal disease is tooth loss; however, the disease will have created significant problems prior to tooth exfoliation.

Clinical Features

Normal gingival tissues are coral pink in color (allowing for normal pigmentation), and have a thin edge, with a smooth and regular texture. (Figure 1) In addition, there should be no demonstrable plaque or calculus. Normal sulcal depth in a dog is 0 to 3mm and in a cat, is 0 to 0.5mm (Wiggs RB & Lobprise HB 1997, DeBowes LJ 2010, Bellows J 2004).

The first outward clinical sign of gingivitis is erythema of the gingiva, which is followed by edema and halitosis (Fiorellini JP et al 2006; DeBowes LJ 2010) (Figure 2). While color change is a reliable sign of disease, it is now known that increased gingival bleeding on probing, brushing or chewing occurs prior to a color change (Fiorellini JP et al 2006 Meitner SW 1979). Gingivitis is typically associated with calculus, but is primarily elicited by plaque and thus can be seen in the absence of calculus. Alternatively, widespread supragingival calculus may be present with little to no gingivitis. It is critical to remember that calculus itself is essentially non-pathogenic (Niemi BA 2008, Wiggs RB & Lobprise HB 1997). Therefore, the degree of gingival inflammation should be used to judge the need for professional therapy (Niemi BA 2013).

As gingivitis progresses to periodontitis, the oral inflammatory changes intensify. The hallmark clinical feature of established periodontitis is attachment loss. In other words, the periodontal attachment to the tooth recedes apically. There are two common presentations of attachment loss (Niemi BA 2013). In some cases, the loss results in gingival recession while the sulcal depth remains the same. Consequently, tooth roots become exposed and the disease process is easily identified on conscious exam (Figure 3). In other cases, the gingiva remains at the same height while the area of attachment moves apically, thus creating a periodontal pocket (Figure 4). This form is typically diagnosed only under general anesthesia with a periodontal probe. It is important to note that both presentations of attachment loss can occur in the same patient, as well as the same tooth. Attachment loss progresses, until tooth exfoliation in most cases. After tooth exfoliation occurs, the area generally returns to an uninfected state, but the bone loss is permanent.

Severe local consequences

The most common local consequence of periodontal disease is an oral-nasal fistula (ONF). ONFs are typically seen in older, small breed dogs (especially chondrodystrophic breeds such as Dachshunds); however, they can occur in any breed as well as felines (Niemi BA 2010, Holmstrom et al 1998). ONFs are created by the progression of periodontal disease up the palatal surface of the maxillary canines however; any maxillary tooth is a candidate (Marretta SM & Smith MM 2005; Niemi BA 2010). The result is a communication between the oral and nasal cavities, creating chronic inflammation (rhinitis). (Figure 5) Clinical signs include chronic nasal discharge, sneezing, and occasionally anorexia and halitosis. Definitive diagnosis of an oronasal fistula often requires general anesthesia. The diagnosis is made by introducing a periodontal probe into the periodontal space on the palatal surface of the tooth. (Figure 6) Interestingly, this condition can occur even when the remainder of the patient's periodontal tissues is relatively healthy (including other surfaces of the affected tooth) (Niemi BA 2008). Appropriate treatment of an ONF requires extraction of the tooth and closure of the defect with a mucogingival flap (Marretta SM & Smith MM 2005; Niemi BA 2010).

Another potential severe local consequence of periodontal disease is a class II perio-endo lesion which can be seen in multi-rooted teeth. (Niemi BA 2008). This occurs when the periodontal loss progresses apically and gains access to the endodontic system, thereby causing endodontic disease via bacterial contamination. The endodontic infection subsequently spreads through the tooth via the common pulp chamber and causes periapical ramifications on the other root(s). (Figure 7) In contrast, class I lesions are periodontal infection extending from the root canal

system and class III are true combined lesions (Wiggs RB & Lobprise HB 1997). Type 1 is not a periodontal consequence and type three is exceedingly rare in veterinary patients.

The third potential local consequence of severe periodontal disease is a “pathologic fracture” (Mulligan T *et al.* 1998, DeBowes 2010). These fractures typically occur in the mandible (especially the area of the canines and first molars) due to chronic periodontal loss, which weakens the bone. (Figure 8) This condition is also most commonly seen in small breed dogs, (Mulligan T *et al.* 1998) mostly because their teeth (especially the mandibular first molar) are larger in proportion to their jaws (Gioso MA 2003). (Figure 9) Pathologic fractures occur most commonly as a result of mild trauma or during dental extraction procedures. However, some dogs have suffered from fractures while simply eating.

Pathologic fractures carry a guarded prognosis for several reasons, but mostly due to lack of remaining bone. There are numerous options for fixation, but regardless of the method of fixation chosen, the periodontally diseased root(s) must be extracted for healing to occur (Figure 10) (Niemi BA 2008, Taney KG & Smith MM 2010). Awareness of the risk of pathologic fractures can help the practitioner to avoid problems in at risk patients during dental procedures.

The fourth local consequence of severe periodontal disease results from inflammation close to the orbit, which could potentially lead to blindness (Anthony JMG *et al.* 2010; Ramsey DT *et al.* 1996). The proximity of the tooth root apices of the maxillary molars and fourth premolars places the delicate optic tissues in jeopardy. (Figure 11)

The fifth local consequence described in numerous human studies is an increased incidence of oral cancer in patients with chronic periodontal disease (Rosenquist K *et al.* 2005; Zheng TZ *et al.* 1990; Graham S *et al.* 1977 Wen *et al.* 2014, Guha *et al.* 2007, Rezende *et al.* 2008, Bendgaard *et al.* 1995, Talamini *et al.* 2000, Maier *et al.* 1993). The association in this case is likely due to the chronic inflammatory state that exists with periodontitis (Figure 12) (Trosko JE 2001).

The sixth significant local consequence of periodontal disease is chronic osteomyelitis, which is an area of non-vital infected bone. (Figure 13) Dental disease is the number one cause of oral osteomyelitis. Once an area of bone is necrotic, it can no longer respond to antibiotic therapy. Therefore, definitive therapy generally requires aggressive surgical debridement (Niemi BA 2008; Wiggs RB & Lobprise HB 1997). Finally, osteonecrosis is another possible severe sequel of (untreated or poorly treated) dental disease in dogs (Peralta *et al.* 2015).

Systemic consequences of periodontal disease:

Systemic ramifications of periodontal disease have been extensively studied over the last few decades resulting in numerous papers. While there is currently no cause and effect, and much of the research is human, there is mounting evidence as to the negative consequences of periodontal disease on systemic health. The pathogenesis is that inflammation of the gingiva and periodontal tissues that allows the body’s defenses to attack the invaders also allows these bacteria to gain access to the body (Scannapieco 2004, Mealey and Klokkevold 2006, Niemi 2013). Not only are the bacteria themselves admitted, but also their inflammatory mediators such as lipopolysaccharide (LPS). These bacteria and their byproducts can have severe deleterious effects throughout the body (Takai 2005). In addition to the bacteria themselves and their toxic byproducts, distant effects can also occur secondary to the activation of the patient’s own

inflammatory mediators such as cytokines (e.g. IL-1 and 6, PGE2, and TNF) (Pavlica *et al* 2008, Lah *et al* 1993, Renvert *et al* 1996, Scannapieco 2004 Rawlinson *et al* 2005). These mediators have been linked to numerous systemic problems such as cardiovascular, hepatic, and renal insults. (see below) It is reported that human patients with periodontal disease are four times more likely to have multiple (three or more) systemic maladies than those in good periodontal health (Al-Emadi *et al* 2006).

Affected organs:

Liver:

The bacterial invasion of the liver has been shown to increase parenchymal inflammation and portal fibrosis (DeBowes *et al* 1996). It has also been correlated with overall liver disease (Tomofuji *et al* 2009, Ohyama 2009, Alberg 2014). Furthermore, bacteremias have been shown to cause cholestasis in dogs (Taboada and Meyer 1989, Center 1990). Finally, one study showed a significant relationship between the periodontal disease burden and increased inflammation in the hepatic parenchyma (Pavlica *et al* 2008).

Kidney:

Renal filtration places periodontopathogenic bacteria in direct contact with endothelium and therefore increases the likelihood of the glomerular capillary walls being affected (Arbes *et al* 1999, Khlgatain *et al* 2002, Nassar 2002, Ortiz *et al* 1991). Chronic infectious and inflammatory diseases have been shown to contribute to the formation of immune complexes in the kidney, resulting in glomerulonephritis, which may be self-propagating (Hoffmann *et al* 1996) (Baylis 1987) (MacDougal *et al* 1986, Sedor *et al* 1993). These changes can lead to chronic inflammation and secondary scarring of the organ resulting in decreased function over time (DeBowes *et al* 1996, Fournier *et al* 2001, Pavlica *et al* 2008, Rawlinson *et al* 2005, Cullinan 2009).

Heart:

Periodontal disease has been linked to significant changes in the cardio-pulmonary system. Several studies have suggested that oral bacteria can adhere to previously damaged heart valves leading to endocarditis. (O'Grady 1995, Abbott 2008) There are also veterinary studies which have noted a significant increase in the incidence of atrio-ventricular valve changes with periodontal disease. (Pavlica *et al* 2008), In fact, one report showed the risk of endocarditis at approximately 6-fold higher for dogs with stage 3 periodontal disease, compared with the risk for dogs without periodontal disease (Glickman *et al* 2009).

While ischemic heart disease is not a common problem in veterinary patients, numerous studies have linked periodontal disease and oral bacteremias to myocardial infarctions and other histological changes in humans (Southerland *et al* 2006, Arbes *et al* 1999, Matilla *et al* 1989, Loos *et al* 2000, Janket *et al* 2003, Joshipura *et al* 1996, Franek *et al* 2005, Glickman *et al* 2009, Geerts *et al* 2004, Beck *et al* 1996, Spahr *et al* 2006) (Arbes *et al* 1999) In addition, the endothelial function of the heart muscle is negatively affected by periodontal disease. (Mercanoglu *et al* 2004) Finally, periodontal disease is reported to be associated with hypertension in humans. (Tsakos *et al* 2010)

The physiologic changes that precede Ischemic heart disease (increased blood viscosity, as well as increased fibrinogen, platelet aggregation-associated protein (PAAP), and other coagulation

factors) can be promoted by periodontal inflammation. (Lowe *et al* 1997, Kweider *et al* 1993, Herzberg *et al* 1998). In fact, the simple infusion of these bacteria resulted in alterations of physical parameters (such as heart rate, blood pressure, and ECG) in rabbits consistent with a myocardial infarction (Meyer *et al* 1998). Finally, there are studies which found periodontal infections to directly cause atherosclerosis in pigs and mice (Brodala *et al* 2005, Lalla *et al* 2003). C reactive protein and other inflammatory markers are increased in periodontal disease and are associated with myocardial infarction. (Noack *et al* 2001, (Ridker *et al* 2002, Wu *et al* 2000, D'Aiuto *et al* 2004, DeBowes 2008, Joshipura *et al* 2004, (de Oliveira *et al* 2010).

Lungs

Several studies have linked gum disease to an increased incidence of chronic respiratory disease (COPD) and pneumonia (Garcia 2001, Limeback 1998, Hayes *et al* 1998, Deo 2009, Scannapieco *et al* 1998, Al-Emadi *et al* 2006, Mealey and Klokkevold 2006).

Oral infections are also known to exacerbate chronic respiratory diseases and proper care will decrease these consequences (Scannapieco *et al* 1998, Nagatake *et al* 2002, Kawana *et al* 2002, Adachi *et al* 2007, Adachi *et al* 2002).

Other deleterious effects:

Diabetes mellitus

Numerous studies have established a strong link between diabetes and increased periodontal disease, as well as between periodontal disease and an increase in insulin resistance (Nesbitt *et al* 2010, Benguigui *et al* 2010, Nagata 2009, Nishimura *et al* 2005, Ekuni *et al* 2010, Al-Emadi *et al* 2010). This makes sense, as any acute infection (bacterial or viral) will increase insulin resistance and worsen glycemic control, even in non-diabetic patients (Yri-Jarvinen *et al* 1989, Grossi *et al* 2004, Zadik 2010). This means that periodontal disease lends to not only poor diabetic control, but maybe more importantly to the increased severity of diabetic complications (wound healing, microvascular disease) as well as cardiac and renal disease (Iacopino *et al* 2001, Taylor *et al* 1996, Thorstensson *et al* 1996, Tsai *et al* 2002, Southerland *et al* 2006, Saremi *et al* 2005, Thorstensson *et al* 1996).

Malignancies:

While far from definitive due to the large number of confounding factors (Meyer *et al* 2008), recent studies are proposing a link between periodontal disease and distant neoplasia such as gastrointestinal, kidney, pancreatic, and hematological cancers. (Watabe *et al* 1998, Abnet *et al* 2001, Stolzenberg-Solomon *et al* 2003, Michaud *et al* 2007, Hujoel *et al* 2003, Chang *et al* 2016, Maruyama *et al* 2017, Michaud *et al* 2013).

Chronic inflammation:

It has been proven that periodontal disease can elicit an increase in inflammatory lipids as well as an overall lipidemic state (Nibali *et al* 2007, Lah *et al* 2003, Renvert *et al* 1996, Scannapieco 2004, Rawlinson *et al* 2005, Winning *et al* 2015, (Moutsopoulos and Madianos 2006, Iacopino and Cutler 2004, Ebersole *et al* 1999, Salvi *et al* 1998).

Early mortality:

A strikingly significant indicator of the degree to which periodontal disease affects overall health is demonstrated in mortality studies. When all other risk factors are ruled out, periodontal disease has been shown to be a significant predictor of early mortality in human beings (Jansson *et al* 2002, Avlund *et al* 2009, Holm-Pedersen *et al* 2008). In fact, one study reported that severe periodontal disease is a higher risk factor than smoking (Garcia *et al* 1998).

Systemic benefits of periodontal therapy:

While these numerous studies do not prove a cause and effect relationship, the sheer numbers are highly suggestive of a link. However, further support for the role that periodontal disease plays in systemic disease is provided by studies that show improvement in health markers following periodontal therapy.

By far the best studied conditions are diabetes and heart disease in humans.

Proper therapy of periodontal disease improves glycemic control and decreases insulin requirements (D'Aiuto *et al* 2004, Mine *et al* 2005, Mealy 1999, Miller *et al* 1992, Skaleric *et al* 2004, Promsudthi *et al* 2005, Stewart *et al* 2001, Hayashi *et al* 2017, Simpson *et al* 2015, Wang *et al* 2014) In addition, periodontal health is improved in patients with good diabetic control (Tervonen and Knuuttila 1986, Tsai *et al* 2002). Periodontal therapy can decrease the level of circulating inflammatory products and improve endothelial function (Correa *et al* 2010, Duarte *et al* 2010, Mercanoglu *et al* 2004, Hayashi *et al* 2017)

There is also evidence to suggest that periodontal therapy improves renal function (Artese *et al* 2010, Grazini *et al* 2010, Hayashi *et al* 2017). Periodontal therapy has been shown to improve liver values and increase lifespan in patients with cirrhosis (Hayashi *et al* 2017, Tomofuji *et al* 2009, Lins *et al* 2011, Grønkjær 2015).

Conclusion:

While the aforementioned studies are not definitive, periodontal disease is an infectious process that requires affected patients to deal with dangerous bacteria on a daily basis, leading to a state of chronic disease (Harvey and Emily 1993, Holmstrom *et al* 1998). Therefore, we must learn to view periodontal disease as not merely a dental problem that causes bad breath and tooth loss, but as an initiator of more severe systemic consequences. As one human text states, "Periodontitis is a gram-negative infection resulting in severe inflammation, with potential intravascular dissemination of microorganisms throughout the body" (Mealey and Klokkevold 2006). This is echoed by additional authors who state: "Periodontal disease is clearly an important and potentially life threatening condition, often underestimated by health professionals and the general public". (Sculley and Langley-Evans 2002). The Surgeon General of the United States issued a statement in 2000 referring to the 'silent epidemic' of oral and dental diseases, and stressed the importance of oral health as being essential for general health and well-being (NIH 2000). Finally, the World Health Organization Executive Board acknowledged the intrinsic link between oral health, general health and quality of life (WHO 2007).

Key Points:

- Periodontal disease is by far the most common medical condition in small animal veterinary patients.
- Plaque forms within 24 hours, calculus within 3 days and gingivitis begins as early as 2 weeks.
- Periodontal inflammation is caused by subgingival plaque; therefore, control of plaque needs to address both supra- and more importantly subgingival plaque to be effective at controlling disease.
- Calculus (or tartar) is essentially non-pathogenic
- The first sign of periodontal disease is bleeding on probing or brushing which occurs prior to a color change
- Periodontal infections have been linked to numerous systemic maladies including:
 - Diabetes Mellitus
 - Heart, lung, liver, and kidney disease
 - Early mortality
- Periodontal disease has been associated with numerous severe local effects including:
 - Oronasal fistulas
 - Oral cancer
 - Mandibular fractures
 - Ocular infection and blindness
 - Osteomyelitis
 - Class II perio-endo lesions

References:

Lund EM, Armstrong PJ, et al (1999) Health status and population characteristics of dogs and cats examined at private veterinary practices in the United States. *J Am Vet Med Assoc.* 214, 1336-41.

National Companion Animal Study (1996) University of Minnesota Center for companion animal health. Uplinks: pp 3.

Wiggs RB, Lobprise HB (1997) Periodontology, in *Veterinary Dentistry, Principles and Practice*: Philadelphia, PA, Lippincott – Raven. pp 186-231.

Hoffmann TH, Gaengler P: (1996) Clinical and pathomorphological investigation of spontaneously occurring periodontal disease in dogs. *J Small Anim Pract.* 37: 471-9, 1996.

Niemiec BA. (2010) Pathologies of the oral mucosa. In; *Small animal dental, oral, and maxillofacial disease, a color handbook* (Niemiec BA (ed). London, Manson, 2010, 183-98.

Debowes LJ: Problems with the gingiva. In: *Small Animal dental, oral and maxillofacial disease, a color handbook* (Niemiec BA ed.). London, Manson, 2010, pp159 – 181.

Niemiec BA (2013) Local and Regional Consequences of Periodontal Disease. In: Veterinary Periodontology. (Niemiec BA, ed). Ames, Wiley Blackwell, 69-80.

Niemiec BA (2013) Systemic Manifestations of Periodontal Disease. In: Veterinary Periodontology. (Niemiec BA, ed). Ames, Wiley Blackwell, 81-90.

Loe H, Theilade E, Jensen SB (1965) Experimental gingivitis in man. *J Periodontol*, 36: 177.

Silness J, Loe H: Periodontal disease in pregnancy II. Correlation between oral hygiene and periodontal condition. *Acta Odontol Scand*. 22:121, 1964.

Armitage GC (1999) Development of a classification system for periodontal diseases and conditions. *Ann Periodontol* 4 (1):1-6. 1999.

Novak MJ (2006) Classification of disease and conditions affecting the periodontium. in Carranza's Clinical Periodontology. St. Louis, Mo, WB Saunders, 2006, pp100-109.

Shoukry M, Ali B, Naby MA, Soliman A (2007) Repair of experimental plaque-induced periodontal disease in dogs. *J Vet Dent* 24(3): 152-65.

Quirynen M, Teughels W, Kinder Haake S, Newman MG: Microbiology of Periodontal diseases, in: Carranza's Clinical Periodontology. St. Louis, Mo, WB Saunders, 2006, pp 134-169

Lindhe J, Hamp S, Loe H: (1975) Plaque induced periodontal disease in beagle dogs: A 4-year clinical, roentgenographical and histometrical study. *J Perio Res*. 10; 243-255.

Boyce EN, Ching RJ, Logan EI, et al (1995): Occurrence of gram-negative black-pigmented anaerobes in subgingival plaque during the development of canine periodontal disease. *Clin Infect Dis*. 20 Suppl 2: S317-9.

DuPont GA (1997) Understanding dental plaque: Biofilm Dynamics *J Vet Dent* 14(3), 91-9.

Socransky SS, Haffajee AD (2002) Dental biofilms: difficult therapeutic targets. *Periodontol* 2000. 28:12-55.

Williams JE: (1995) Microbial Contamination of Dental Lines, in Current and Future Trends In: Veterinary Dentistry: Proceedings of the Upjohn Worldwide Companion Animal Veterinary Dental Forum. 8-11.

Elder MJ, Stapleton F, et al. (1995) Biofilm related infections in ophthalmology: *Eye* 9(1); 102-109.

Niemiec BA (2008) Periodontal disease. *Top Companion Anim Med*.23(2):72-80.

Westfelt E, Rylander H, Dahlen G, Lindhe J (1998) The effect of supragingival plaque control on the progression of advanced periodontal disease. *J Clin Periodontol*. 25(7): 536-41, 1998

Hinrichs JE: (2006) The role of dental calculus and other predisposing factors, in: Carranza's Clinical Periodontology. St. Louis, Mo, WB Saunders, pp 170-192.

Harvey CE, Emily PP (1993) Periodontal Disease, in Small Animal Dentistry. St. Louis, Mosby, pp 89-144.

Nisengard RJ, Kinder Haake S, Newman MG, Miyasaki KT (2006) Microbial interactions with the host in periodontal diseases, in: Carranza's Clinical Periodontology. St. Louis, Mo, WB Saunders, pp 228-250.

Lang NP, Mombelli A, Attstrom R. (2002) Dental Plaque and Calculus. In: Clinical Periodontology and implant dentistry. Lindhe J, Karring T, Lang NP eds. 3rd ed, Munksgaard, pp.102-34.

Thoden Van Velzen SK, Abraham-Inpijin L, Modrer WDR: (1984) Plaque and systemic disease: a reappraisal of the focal infection concept. J Clin Periodontol 11: 209-20.

Scannapieco FA (2004) Periodontal inflammation: from gingivitis to systemic disease? Compend Contin Educ Dent;25(suppl 1):16-25.

Fiorellini JP, Ishikawa SO, Kim DM (2006) Clinical Features of Gingivitis, in: Carranza's Clinical Periodontology. St. Louis, Mo, WB Saunders, pp 362- 72.

Fiorellini JP, Kim DM, Ishikawa SO (2006) The Gingiva. in: Carranza's Clinical Periodontology. St. Louis, Mo, WB Saunders 46-67.

Wiggs RB, Lobprise HB (1997) Oral exam and diagnosis, in Veterinary Dentistry, Principals and Practice. Philadelphia, PA, Lippincott – Raven, pp 87-103

Bellows J (2004) Periodontal equipment, Materials, and Techniques. In: Small Animal Dental Equipment, Materials, and Techniques, a Primer. Blackwell, pp. 115-73.

Meitner SW, Zander H, Iker HP, et al (1979) Identification of inflamed gingival surfaces. J Clin Periodontol. 6:93.

Niemiec BA (2013) Pathogenesis and Etiology of Periodontal Disease. In: Veterinary Periodontology. (Niemiec BA, ed). Ames, Wiley Blackwell, 81-90.

Niemiec BA (2013) Periodontitis. In: Veterinary Periodontology. (Niemiec BA, ed). Ames, Wiley Blackwell, 51-68.

Holmstrom SE, Frost P, Eisner ER (1998) Exodontics, in Veterinary Dental Techniques (ed 2) Philadelphia, PA, Saunders, pp 215-254.

- Niemiec BA. (2010) Pathologies of the oral mucosa. In; Small animal dental, oral, and maxillofacial disease, a color handbook (Niemiec BA (ed). London, Manson, 183-98.
- Marretta SM, Smith MM (2005) Single mucoperiosteal flap for oronasal fistula repair. *J Vet Dent* 22(3):200–5.
- Wiggs RB, Lobprise HB (1997) Basic endodontic therapy, in *Veterinary Dentistry, Principals and Practice*. Philadelphia, PA, Lippincott – Raven, pp 280-324.
- Mulligan TW, Aller S, Williams CE (1998) Trauma, in *Atlas of canine and feline dental radiography*. Trenton, NJ, Veterinary Learning Systems, pp 176-183.
- Gioso MA, Shofer F, Barros PS, Harvery CE (2003) Mandible and mandibular first molar tooth measurements in dogs: relationship of radiographic height to body weight. *J Vet Dent* 18(2): 65-8
- Taney KG, Smith MM (2010) Problems with muscles, bones, and joints. In; Small animal dental, oral, and maxillofacial disease, a color handbook (Niemiec BA (ed). London, Manson, 199-204.
- Anthony JMG, Sammeyer LS, Laycock AR. (2010) *Vet Ophthalmol.* 13: 106-9.
- Ramsey DT, Marretta SM, Hamor RE, et al (1996). Ophthalmic manifestations and complications of dental disease in dogs and cats. *J Am Anim Hosp Assoc.* 32(3):215-24.
- Rosenquist K (2005) Risk factors in oral and oropharyngeal squamous cell carcinoma: a population-based case-control study in southern Sweden. *Swed Dent J Suppl* 179: pp 1-66.
- Rosenquist K, Wennerberg J, Schildt EB, et al: (2005) Oral status, oral infections and some lifestyle factors for oral and oropharyngeal squamous cell carcinoma. A population-based case-controlled study in southern Sweden. *Acta Otolaryngol* 125(12): pp1327-36.
- Zheng TZ, Boyle P, Hu HF, et al. (1990) Dentition, oral hygiene, and risk of oral cancer: a case-control study in Beijing, People's Republic of China. *Cancer Causes Control.* 1990; 1:235–241
- Graham S, Dayal H, Rohrer T, et al. (1977) Dentition, diet, tobacco, and alcohol in the epidemiology of oral cancer. *J Natl Cancer Inst.* 59:1611–1618.
- Trosko JE (2001) Commentary: is the concept of “tumor promotion” a useful paradigm? *Mol Carcinog.* 30: 131-137.
- Wiggs RB, Lobprise HB (1997) *Veterinary Dentistry, Principals and Practice*. Philadelphia, PA, Lippincott – Raven, pp 128, 163.
- Marshall MD, Wallis CV, Milella L, Colyer A, Tweedie AD, Harris S (2014) A longitudinal assessment of periodontal disease in 52 Miniature Schnauzers. *BMC Vet Res.* 10:166.

Holcombe LJ, Patel N, Colyer A, Deusch O, O'Flynn C, Harris S (2014) Early canine plaque biofilms: characterization of key bacterial interactions involved in initial colonization of enamel. *PLoS One.* ;9(12): e113744.

Wen BW, Tsai CS, Lin CL, Chang YJ, Lee CF, Hsu CH, Kao CH. (2014) Cancer risk among gingivitis and periodontitis patients: a nationwide cohort study. *QJM.*107(4):283-90.

Guha N, Boffetta P, Wunsch Filho V, Eluf Neto J, Shangina O, Zaridze D, Curado MP, Koifman S, Matos E, Menezes A, Szeszenia-Dabrowska N, Fernandez L, Mates D, Daudt AW, Lissowska J, Dikshit R, Brennan P. (2007) Oral health and risk of squamous cell carcinoma of the head and neck and esophagus: results of two multicentric case-control studies. *Am J Epidemiol.* 166(10):1159-73.

Rezende CP, Ramos MB, Daguíla CH, Dedivitis RA, Rapoport A. (2008) Oral health changes in with oral and oropharyngeal cancer. *Bras J Otorhinolaryngol.* 74(4):596-600.

Bundgaard T, Wildt J, Frydenberg M, Elbrønd O, Nielsen JE. (1995) Case-control study of squamous cell cancer of the oral cavity in Denmark. *Cancer Causes Control.* 6(1):57-67.

Talamini R, Vaccarella S, Barbone F, Tavani A, La Vecchia C, Herrero R, Muñoz N, Franceschi S (2000) Oral hygiene, dentition, sexual habits and risk of oral cancer *Br J Cancer,* 83 (9). 1238-42

Maier H, Zöller J, Herrmann A, Kreiss M, Heller WD (1993) Dental status and oral hygiene in patients with head and neck cancer. *Otolaryngol Head Neck Surg,* 108 (6). 655-661,

Peralta S, Arzi B, Nemeč A, Lommer MJ, Verstraete FJ (2015) Non-Radiation-Related Osteonecrosis of the Jaws in Dogs: 14 Cases (1996-2014). *Front Vet Sci.* 5; 2:7.

Scannapieco FA (2004) Periodontal inflammation: from gingivitis to systemic disease? *Compend Contin Educ Dent ;*25(suppl 1):16-25.

Mealey BL, Klokkevold PR (2006) Periodontal Medicine: Impact of periodontal infection on systemic health. in: Carranza's Clinical Periodontology. St. Louis, Mo, WB Saunders, 2006, pp 312-329.

Niemiec BA (2013) Systemic Manifestations of Periodontal Disease. In: Veterinary Periodontology. (Niemiec BA, ed). Ames, Wiley Blackwell, 81-90.

Takai T (2005) Fc receptors and their role in immune regulation and autoimmunity. *J Clin Immunol* 25: 1-18.

Pavlica Z, Petelin M, Juntos P, et al (2008) Periodontal disease burden and pathological changes in the organs of dogs. *J Vet Dent* 25 (2), 97-108.

Lah TT, Babnik J, et al (1993) Cysteine proteinases and inhibitors in inflammation: Their role in periodontal disease. *J Periodontol.* 64: 485-91.

Renvert S, Wirkstrom M, et al (1996) Histological and microbiological aspects of ligature induced periodontitis in beagle dogs. *J Clin Perio.*23:310-9.

Rawlinson JE, Reiter AM, Harvey CE (2005) Tracking systemic parameters in dogs with periodontal disease. Proceedings of the 19th annual veterinary dental forum, Orlando, pp. 429.

Tomofuji T, Ekuni D, Sanbe T, Azuma T, Tamaki N, Irie K, et al. (2009) Effects of improvement in periodontal inflammation by tooth brushing on serum lipopolysaccharide concentration and liver injury in rats. *Acta Odontol Scand*; 67:200–5.

Ohyama H, Nakasho K, Yamanegi K, Noiri Y, Kuhara A, Kato-Kogoe N, et al (2009) An unusual autopsy case of pyogenic liver abscess caused by periodontal bacteria. *Jpn J Infect Dis.* 62:381–3.

Aberg F, Helenius-Hietala J, Meurman J, Isoniemi H. (2014) Association between dental infections and the clinical course of chronic liver disease. *Hepato Res.* 44(3):349-53.

Taboada J, Meyer DJ (1989) Cholestasis associated with extrahepatic bacterial infection in five dogs. *J Vet Intern Med.* 3: 216-20.

Center SA (1990) Hepatobiliary infections. In: Green CE, ed. *Infectious diseases of the dog and cat.* Philadelphia, PA, W.B. Saunders, pp 146-56.

Arbes SJ jr, Slade GD, Beck JD (1999) Association between extent of periodontal disease and self-reported history of heart attack: an analysis of NHANES III data. *J Dent Res.* 78: 1777.

Khlgatain M, Nassar H, et al. (2002) Fimbria-dependent activation of cell adhesion molecule expression in *Porphyromonas gingivalis* infected endothelial cells. *Infect Immun.* 70: 257-67.

Nassar H, Chou HH, et al (2002) Role for fimbriae and lysine-specific cysteine proteinase gingipain K in expression of interleukin – 8 and monocyte chemoattractant protein in *Porphyromonas gingivalis* infected endothelial cells. *Infect immune.* 70: 268-76.

Ortiz A, Gomez-Chiarri M, et al (1991) The role of platelet-activating factor (PAF) in experimental glomerular injury. *Lipids.* 26:1310-5.

Hoffmann TH, Gaengler P (1996) Clinical and pathomorphological investigation of spontaneously occurring periodontal disease in dogs. *J Small Anim Pract.* 37: 471-9.

Baylis C (1987) Effects of administered thromboxane on the intact, normal rat kidney. *Ren Physiol.* 10:110-21.

MacDougal DF, Cook T, et al (1986) Canine chronic renal disease: prevalence and types of glomerulonephritis in the dog. *Kidney Int.* 29:1144-51.

Sedor JR, Konieczkowski M, et al (1993) Cytokines, mesangial cell activation and glomerular injury. *Kidney Int.* 39 (suppl) 65S-70S.

Debowes LJ, Mosier D, Logan E, Harver CE, Lowry S, Richardson DC: (1996) Association of periodontal disease and histologic lesions in multiple organs from 45 dogs. *J Vet Dent* 13(2): 57-60.

Fournier D, Mouton C, et al. (2001) *Porphyromonas gulae* sp. Nov., an anaerobic, gram – coccobacillus gingival sulcus of various animal hosts. *Int J Syst Evol Microbiol.* 51: 1179-89.

Cullinan MP, Ford PJ, Seymore GJ (2009) Periodontal disease and systemic health: current status. *Aust Dent J.* 54(Supp 1), S62-S69.

O'Grady MR (1995) Acquired valvular heart disease, in Ettinger SJ, Feldman EC (eds.): *Textbook of Veterinary Internal Medicine* (ed 4). Philadelphia, PA, W.B. Saunders, pp 944-958.

Abbott JA (2008) Acquired Valvular Disease. In: *Manual of Canine and Feline Cardiology* (fourth edition) Tilley LP (ed). Elsevier, St Louis, MO, pp. 110-38.

Glickman LT, Glickman NW, Moore GE, Goldstein GS, Lewis HB.(2009) Evaluation of the risk of endocarditis and other cardiovascular events on the basis of the severity of periodontal disease in dogs. *J Am Vet Med Assoc.* 234(4):486-94.

Southerland JH, Taylor GW, Moss K, Beck JD, Offenbacher S (2006) Commonality in chronic inflammatory diseases: periodontitis, diabetes, and coronary artery disease. *Periodontol.*40:130–143.

Arbes SJ, Slade GD, Beck JD (1999) Association between the extent of periodontal attachment loss and self-reported oh heart attack: an analysis of NHANES III data. *J Dent Res.* 78: 1777-82.
Mattila KJ, Nieminen MS, Valtonen VV, et al (1989): Association between dental health and acute myocardial infarction. *British Medical Journal,* 298:779.

Loos BG, Craandijk J, Hoek FJ, Wertheim-Van Dillen PM, van der Velden U (2000) Elevation of systemic markers related to cardiovascular diseases in the peripheral blood of periodontitis patients. *J Periodontol* 71(10): pp 1528-34.

Janket S, Baird AE, Chuang S, Jones JA (2003) Meta-analysis of periodontal disease and risk of coronary heart disease and stroke, *Oral Surg Oral Med Oral Pathol oral Radiol Endod.* 95: 559

Joshi KJ, Rirum EB, et al (1996) Association of periodontal disease and coronary heart disease. *J Dent Res.* 75: 1631-36.

Franek E, Blach A, et al (2005) Association between chronic periodontal disease and left ventricular hypertrophy in kidney transplant recipients. *Transplantation.* 80: 3-5.

Geerts SO, Legrand V, Charpentier J, Albert A, Rompen EH.(2004) Further evidence of the association between periodontal conditions and coronary artery disease. *J Periodontol.* 75(9):1274-80.

Beck J, Garcia R, Heiss G, Vokonas PS, Offenbacher S (1996) Periodontal disease and cardiovascular disease. *J Periodontol.* 67(10 Suppl):1123-37.

Spahr A, Klein E, Khuseyinova N, Boeckh C, Muche R, Kunze M, Rothenbacher D, Pezeshki G, Hoffmeister A, Koenig W (2006) Periodontal infections and coronary heart disease: role of periodontal bacteria and importance of total pathogen burden in the Coronary Event and Periodontal Disease (CORODONT) study. *Arch Intern Med.* 13;166(5):554-9.

Arbes SJ jr, Slade GD, Beck JD (1999) Association between extent of periodontal disease and self-reported history of heart attack: an analysis of NHANES III data. *J Dent Res.* 78: 1777.

Mercanoglu F, Oflaz H, Oz O, et al (2004) Endothelial dysfunction in patients with chronic periodontitis and its improvement after initial periodontal therapy. *J Periodontol.* 75(12):1694-700.

Tsakos G, Sabbah W, Hingorani AD (2010) Is periodontal inflammation associated with raised blood pressure? Evidence from a National US survey. *J Hypertens.* 2010.

Lowe GD, Lee AJm, Rumley A, et al (1997) Blood viscosity and of cardiovascular events: the Edinburgh artery study. *Haematol,* 96: 168.

Kweider M, Lowe GD, Murray GD, et al (1993) Dental disease, fibrinogen, and white cell counts: links with myocardial infarction? *Scott Med Journal*38:73.

Herzberg MC, Meyer MW (1998) Dental plaque, platelets, and cardiovascular diseases. *Ann Periodontol.* 3:151.

Meyer MW, Gong K, Herzberg MC.(1998) Streptococcus sanguis-induced platelet clotting in rabbits and hemodynamic and cardiopulmonary consequences. *Infect Immun.* 66(12):5906-14.

Noack B, Genco RJ et al. (2001) Periodontal infections contribute to elevated systemic C-reactive protein level. *J Periodontol* 72:1221-1227.

Ridker PM, Rifai N, Rose L, et al (2002) Comparison of C-Reactive protein and low density lipoprotein cholesterol levels in the prediction of first cardiac events. *New England J Med*347: 1557.

Wu t, Trevisan M, Genco RJ, et al: (2000) Examination of the relation of between periodontal health status and cardiovascular risk factors: serum total and high density lipoprotein cholesterol, C-reactive protein, and plasma fibrinogen. *Am J Epidemiol.* 151: 273.

D'Aiuto F, Parkar M, et al. (2004) Periodontitis and systemic inflammation: control of the local infection is association with a reduction in serum inflammatory markers. *J Dent Res.* 83: 156-60.

Debowes LJ (2008) C-Reactive Protein and Periodontal disease. Proceedings of the 22nd Annual Dental Forum.

Joshiyura KJ, Wand HC, Merchant AT, Rimm EB. (2004) Periodontal disease and biomarkers related to cardiovascular disease. *J Dent Res.* 83:151–155.

de Oliveira C, Watt R, and Hamer M. (2010) Toothbrushing, inflammation, and risk of cardiovascular disease: Results from Scottish Health Survey. *BMJ*

Brodala N, Merricks EP, et al: (2005) *Porphyromonas gingivalis* bacteremia induces coronary and aortic atherosclerosis in normocholesterolemic and hypercholesterolemic pigs. *Arterioscler Thromb Vasc Biol.* 25: 1446-51.

Lalla E, Lamster IB. et al (2003) Oral infection with a periodontal pathogen accelerates early atherosclerosis in apolipoprotein E-null mice. *Arterioscler Thromb Vasc Biol.* 23: 1405- 11.

Garcia R (2001) Epidemiologic Associations between Periodontal diseases and Respiratory Diseases. In *The Periodontal-Systemic Connection: a State-of-the-Science Symposium*, Bethesda MD. April 18-20.

Limeback H (1998) Implications of oral infections on systemic diseases in the institutionalized elderly with a special focus on pneumonia. *Ann Periodontol* 3(1): pp 262-75.

Hayes C, Sparrow D, Cohen M, Et Al.(1998) The association between alveolar bone loss and pulmonary function: the VA Dental longitudinal study. *Ann Periodontol* 3: 257.

Deo V, Bhongade ML, Ansari S, Chavan RS. Periodontitis as a potential risk factor for chronic obstructive pulmonary disease: a retrospective study. *Indian J Dent Res.* 20(4):466-70, 2009.

Scannapieco FA, Papandonatos GD, Dunford RG (1998) Associations between oral conditions and respiratory disease in a national sample survey population. *Ann Periodontol.* 3(1):251-6.

Nagatake T, Ahmed K, Oishi K. (2002) Prevention of respiratory infections by povidone-iodine gargle. *Dermatology.* 204 Suppl 1:32-6.

Kawana R, Nagasawa S, Endo T, Fukuroi Y, Takahashi Y. (2002) Strategy of control of nosocomial infections: application of disinfectants such as povidone-iodine. *Dermatology.* 204 Suppl 1:28-31.

Adachi M, Ishihara K, Abe S, Okuda K. (2007) Professional oral health care by dental hygienists reduced respiratory infections in elderly persons requiring nursing care. *Int J Dent Hyg.* 5(2):69-74.

Adachi M, Ishihara K, Abe S, Okuda K, Ishikawa T. (2002) Effect of professional oral health care on the elderly living in nursing homes. *Oral Surg Oral Med Oral Pathol Oral Radiol Endod.* 94(2):191-5.

Nesbitt MJ, Reynolds MA, Shiao H: (2010) Association of periodontitis and metabolic syndrome in the Baltimore Longitudinal Study of Aging. *Aging Clin Exp Res.* 22(3):238-42.

Benguigui C, Bongard V, Ruidavets JB, Chamontin B, Sixou M, Ferrières J, Amar J.(2010) Metabolic syndrome, insulin resistance, and periodontitis: a cross-sectional study in a middle-aged French population. *J Clin Periodontol.*37(7):601-8.

Nagata T. (2009) Relationship between diabetes and periodontal disease *Clin Calcium.*19(9):1291-8.

Nishimura F, Soga Y, Iwamoto Y, Kudo C, Murayama Y. (2005) Periodontal disease as part of the insulin resistance syndrome in diabetic patients. *J Int Acad Periodontol.* 2005 7(1):16-20.

Ekuni D, Tomofuji T, Irie K, et al: (2010) Effects of periodontitis on aortic insulin resistance in an obese rat model. *Lab Invest.* 90(3):348-59.

Al-Emadi A, Bissada N, Farah C, Siegel B, Al-Zaharani M. (2006) Systemic diseases among patients with and without alveolar bone loss. *Quintessence Int.* 37(10):761-5.

Yri-Jarvinen H, Sammalkorpi K, Koivisto VA, et al. (1989) Severity, duration, and mechanism of insulin resistance during acute infections. *J clin Endocrinol Metab* 69: 317.

Grossi SG, Mealey BL, Rose LF: (2004) Effect of periodontal infection on systemic health and well-being. In Rose LF, Mealey BL, Genco RJ, Cohen DW, editors. *Periodontics: medicine, surgery, and implants.* St Louis, Elsevier

Zadik Y, Bechor R, Galor S, Levin L.(2010) Periodontal disease might be associated even with impaired fasting glucose. *Br Dent J.* 208(10): E20.

Iacopino AM (2001) Periodontitis and diabetes interrelationships: role of inflammation. *Ann Periodontol* 6(1): pp 125-37.

Taylor GW, Burt BA, Becker MP, et al: (1996) Severe periodontitis and risk for poor glycemic control in patients with non-insulin dependent diabetes mellitus. *J periodontal.* 67: 1085.

Tsai C, Hayes C, Taylor GW. (2002) Glycemic control of type 2 diabetes and severe periodontal disease in US adult population. *Community Dent Oral Epidemiol*;30:182-92.

Southerland JH, Taylor GW, Moss K, Beck JD, Offenbacher S. (2006) Commonality in chronic inflammatory diseases: periodontitis, diabetes, and coronary artery disease. *Periodontol.*40:130-143

Saremi A, Nelson RG, Tulloch-Reid M, Hanson RL, Sievers ML, Taylor GW, et al. (2005) Periodontal disease and mortality in type 2 diabetes. *Diabetes Care* 28:27-32.

Thorstensson H, Kuylensstierna J, Hugoson A. (1996) Medical status and complications in relation to periodontal disease in insulin dependent diabetics. *J Clin Periodontol* 23:194-202.

Meyer MS, Joshipura K, Giovannucci E, Michaud DS. (1998) A review of the relationship between tooth loss, periodontal disease, and cancer. *Cancer Causes Control*.19(9):895-907, 2008. Watabe K, Nishi M, Miyake H, Hirata K. Lifestyle and gastric cancer: a case-control study. *Oncol Rep*. 5:1191–1194.

Abnet CC, Qiao YL, Mark SD, Dong ZW, Taylor PR, Dawsey SM. (2001) Prospective study of tooth loss and incident esophageal and gastric cancers in China. *Cancer Causes Control*. 12:847–854.

Stolzenberg-Solomon RZ, Dodd KW, Blaser MJ, Virtamo J, Taylor PR, Albanes D. Tooth loss, pancreatic cancer, and *Helicobacter pylori*. *Am J Clin Nutr*. 2003; 78:176–181

Michaud DS, Joshipura K, Giovannucci E, Fuchs CS. A prospective study of periodontal disease and pancreatic cancer in US male health professionals. (2007) *J Natl Cancer Inst*. 299:171–175.

Hujoel PP, Drangsholt M, Spiekerman C, Weiss NS. (2003) An exploration of the periodontitis-cancer association. *Ann Epidemiol*. 13:312–316.

Chang JS, Tsai CR, Chen LT, Shan YS. (2016) Investigating the Association Between Periodontal Disease and Risk of Pancreatic Cancer. *Pancreas*. 45(1):134-41.

Maruyama T, Tomofuji T, Machida T, Kato H, Tsutsumi K, Uchida D, Takaki A, Yoneda T, Miyai H, Mizuno H, Ekuni D, Okada H, Morita M. (2017) Association between periodontitis and prognosis of pancreatobiliary tract cancer: A pilot study. *Mol Clin Oncol*. 6(5):683-687.

Michaud DS, Izard J, Wilhelm-Benartzi CS, You DH, Grote VA, Tjønneland A, Dahm CC, Overvad K, Jenab M, Fedirko V, Boutron-Ruault MC, Clavel-Chapelon F, Racine A, Kaaks R, Boeing H, Foerster J, Trichopoulou A, Lagiou P, Trichopoulos D, Sacerdote C, Sieri S, Palli D, Tumino R, Panico S, Siersema PD, Peeters PH, Lund E, Barricarte A, Huerta JM, Molina-Montes E, Dorronsoro M, Quirós JR, Duell EJ, Ye W, Sund M, Lindkvist B, Johansen D, Khaw KT, Wareham N, Travis RC, Vineis P, Bueno-de-Mesquita HB, Riboli E. (2013) Plasma antibodies to oral bacteria and risk of pancreatic cancer in a large European prospective cohort study. *Gut*. 62(12):1764-70.

Michaud DS, Liu Y, Meyer M, Giovannucci E, Joshipura K.(2008) Periodontal disease, tooth loss, and cancer risk in male health professionals: a prospective cohort study. *Lancet Oncol*. 9(6):550-8, 2

Nibali L, D'Aiuto F, Griffiths G, Patel K, Suvan J, Tonetti MS. (2007) Severe periodontitis is associated with systemic inflammation and a dysmetabolic status: a case-control study. *J Clin Periodontol*. 34(11):931-7.

Lah TT, Babnik J, et al: (1993) Cysteine proteinases and inhibitors in inflammation: Their role in periodontal disease. *J Periodontol*. 64: 485-91, 1993,

- Renvert S, Wirkstrom M, et al: (1996) (Histological and microbiological aspects of ligature induced periodontitis in beagle dogs. *J Clin Perio.* 23:310-9.
- Winning L, Patterson CC, Cullen KM, Stevenson KA, Lundy FT, Kee F, Linden GJ. (2015) The association between subgingival periodontal pathogens and systemic inflammation. *J Clin Periodontol.* 42(9):799-806.
- Moutsopoulos NM, Madianos PN (2006) Low grade inflammation in chronic infectious diseases: paradigm of periodontal infections. *Ann N Y Acad Sci.* 1088: pp 251-64.
- Iacopino AM, Cutler CW: Pathophysiological relationships between periodontitis and systemic disease: recent concepts involving serum lipids. *J Periodontol* 71(8): pp 1375-84, 2000
- Ebersole JL, Cappelli D, Mott G, Kesavalu L, Holt SC, Singer RE (1999) Systemic manifestations of periodontitis in the non-human primate. *J Periodontal Res* 34(7): pp 358-62.
- Salvi GE, Brown CE, Fujihashi K, et al. (1998) Inflammatory mediators of the terminal dentition in adult and early onset periodontitis. *J Periodontal Res.* 33:212–225.
- Jansson L, Lavstedt S, Frithiof L (2002) Relationship between oral health and mortality rate. *J Clin Periodontol* 29:1029.
- Avlund K, Schultz-Larsen K, Krustrup U, (2009) Effect of inflammation in the periodontium in early old age on mortality at 21-year follow-up. *J Am Geriatr Soc.* 57(7):1206-12.
- Holm-Pedersen P, Schultz-Larsen K, Christiansen N, Avlund K. (2008) Tooth loss and subsequent disability and mortality in old age *J Am Geriatr Soc.* 56(3):429-35.
- Garcia RI, Krall EA, Vokonas PS (1998) Periodontal disease and mortality from all causes in the VA dental longitudinal Study. *Ann Periodontol* 3:339.
- D'Aiuto F, Parker M, Andreou G. (2004) Periodontitis and systemic inflammation: Control of the local infection is associated with a reduction in serum inflammatory markers. *J Dent Res.* 83:156-60.
- Mine K, Nejat A, Elif U, Faik Murat E. (2005) The effect of improved periodontal health on metabolic control in type 2 diabetes mellitus. *J Clin Periodontol* 32:266-72.
- Mealy BL. (1999) Influence of periodontal infections of systemic health. *Periodontol*2000 21:197.
- Miller LS, Manwell MA, Newbold D, et al. (1992) The relationship between reduction in periodontal inflammation and diabetes control: a control of 9 cases. *J periodontal* 63:843.

Skaleric U, Schara R, Medvescek M, Hanlon A, Doherty F, Lessem J. (2004) Periodontal treatment by Arestin and its effects on glycemic control in type 1 diabetes patients. *J Int Acad Periodontol.* 6(4 Suppl):160-5.

Promsudthi A, Pimapansri S, Deerochanawong C, Kanchanavasita W. (2005) The effect of periodontal therapy on uncontrolled type 2 diabetes mellitus in older subjects. *Oral disease.* 11:293– 298.

Stewart JE, Wager KA, Friedlander AH, Zadeh HH. (2001) The effect of periodontal treatment on glycemic control in patients with type 2 diabetes mellitus. *J Clin Periodontol* 28:306-10

Simpson TC, Weldon JC, Worthington HV, Needleman I, Wild SH, Moles DR, Stevenson B, Furness S, Iheozor-Ejiofor Z. (2015) Treatment of periodontal disease for glycaemic control in people with diabetes mellitus. *Cochrane Database Syst Rev.* 6;(11):CD004714.

Wang TF, Jen IA, Chou C, Lei YP. (2014) Effects of periodontal therapy on metabolic control in patients with type 2 diabetes mellitus and periodontal disease: a meta-analysis. *Medicine (Baltimore).* 93(28): e292.

Tervonen T, Knuuttila M. (1986) Relation of diabetes control to periodontal pocketing and alveolar bone level. *Oral Surg Oral Med Oral Pathol* ;61:346-9.

Tsai C, Hayes C, Taylor GW. (2002) Glycemic control of type 2 diabetes and severe periodontal disease in US adult population. *Community Dent Oral Epidemiol* 30:182-92

Artese HP, Sousa CO, Luiz RR, Sansone C, Torres MC. (2010) Effect of non-surgical periodontal treatment on chronic kidney disease patients. *Braz Oral Res.* 24(4):449-54.

Graziani F, Cei S, La Ferla F, Vano M, Gabriele M, Tonetti M. (2010) Effects of non-surgical periodontal therapy on the glomerular filtration rate of the kidney: an exploratory trial. *J Clin Periodontol.* 37(7): 638-43.

Hayashi J, Hasegawa A, Hayashi K, Suzuki T, Ishii M, Otsuka H, Yatabe K, Goto S, Tatsumi J, Shin K. (2017) Effects of periodontal treatment on the medical status of patients with type 2 diabetes mellitus: a pilot study. *BMC Oral Health.* 21;17(1):77.

Tomofuji T, Ekuni D, Sanbe T, Azuma T, Tamaki N, Irie K, et al. (2009) Effects of improvement in periodontal inflammation by tooth brushing on serum lipopolysaccharide concentration and liver injury in rats. *Acta Odontol Scand.* 67:200–5.

Lins L, Bittencourt PL, Evangelista MA, Lins R, Codes L, Cavalcanti AR, Paraná R, Bastos J. (2011) Oral health profile of cirrhotic patients awaiting liver transplantation in the Brazilian Northeast. *Transplant Proc.* 43(4):1319-21.

Grønkjær LL. (2015) Periodontal disease and liver cirrhosis: A systematic review. SAGE Open Med. Sep 9;3

Correa FO, Gonçalves D, Figueredo CM, Bastos AS, Gustafsson A, Orrico SR.(2010) Effect of periodontal treatment on metabolic control, systemic inflammation and cytokines in patients with type 2 diabetes. J Clin Periodontol. 37(1):53-8.

Duarte PM, da Rocha M, Sampaio E, et al: (2010) Serum levels of cytokines in subjects with generalized chronic and aggressive periodontitis before and after non-surgical periodontal therapy: a pilot study. J Periodontol. 81(7):1056-63.

Mercanoglu F, Oflaz H, Oz O, et al: (2004) Endothelial dysfunction in patients with chronic periodontitis and its improvement after initial periodontal therapy. J Periodontol. 75(12):1694-700.

Scannapieco FA, Bush RB, Paju S. (2003) Associations between periodontal disease and risk for nosocomial bacterial pneumonia and chronic obstructive pulmonary disease. A systematic review. Ann Periodontol. 8(1):54-69.

Harvey CE, Emily PP: (1993) Periodontal Disease, in Small Animal Dentistry. St. Louis, Mosby, pp 89-144.

Holmstrom SE, Frost P, Eisner ER (1998) Dental Prophylaxis, in Veterinary dental techniques (ed 2). Philadelphia, PA, Saunders, pp 133-66

Sculley, D, and Langley-Evans, S: (2002) Salivary Antioxidants and Periodontal Disease Status. Proceedings of the Nutrition Society, 137-143.

Oral health in America: (2000) a report of the surgeon general. Rockville: US Department of Health and Human Services, National Institute of Dental and Craniofacial Research, National Institutes of Health.

WHO (2007) Oral health: action plan for promotion and integrated disease prevention (EB120/10). 120th Session, 22–30 January. WHO, Geneva

Common disorders of the teeth

Enamel Hypoplasia

Trauma, heredity, poor nutritional status, or inflammatory conditions (such as viral (e.g. distemper infection) during development may cause irregularities in enamel formation. (Dupont 2010) Trauma and localized infection tend to damage a single tooth or teeth in the same area. However, systemic disease and genetic conditions generally affect most or all the teeth. These episodes may manifest with microscopic changes that produce a tooth with thin enamel that is easily damaged, termed enamel hypoplasia (Figure 1). Also, commonly noted, enamel hypomineralisation causes enamel pitting, flakiness and discolouration (Figure 2). Enamel or dentine may appear absent on examination, or it may be thinner and weaker and separate during chewing or examination. The terms hypoplasia and hypomineralisation are often used incorrectly in the veterinary literature.

Tooth Wear (abrasion/attrition)

Slow, abrasive loss of enamel and dentine can be classified into the type of wear and the degree of pathology. Physiological wear from mastication, resulting in loss of enamel, dentine and in advanced cases pulp exposure is termed dental attrition. If attrition is due to malocclusion of teeth, it is termed pathological attrition. (Figure 3) Enamel or dentine loss due to an external object, such as metal cages, sticks, balls or bones, is termed dental abrasion (Figure 4) (Dupont 2010). If the process is gradual, odontoblasts can produce tertiary dentine to protect the underlying pulp tissues. However, in cases where attrition or abrasion is rapid, it can result in pulp exposure. Both enamel hypoplasia/hypomineralisation and abrasion/attrition may weaken the tooth structurally leading to a higher chance and prevalence of tooth fracture. This is especially true in cases of chronic cage or fence chewing. (Figure 5)

Tooth Fractures

Fractures to the crown and/or root of the tooth are not an uncommon finding in dogs and cats. Fractured teeth have been found in 49.6 % of companion animals (Soukup *et al.* 2015). Further, 10% of dogs have teeth with direct pulp exposure. (Golden *et al.* 1982). A significant number of dogs and cats have access to bones, sticks, and antlers resulting in injuries caused during chewing; they may be involved in high impact trauma such as car accidents, sporting injuries, i.e. golf stick/ball, baseball bat; or low impact trauma such as fall resulting in tooth fractures. Trauma to the tooth may be classified based on the amount of tooth structure exposed, i.e. enamel, dentine, or root, as well as whether the pulp tissues are directly exposed (Figure 6). It is further classified accordingly as enamel damage or infraction (Figures 7 and 8), enamel loss with no exposure of dentine (Figures 9 and 10), enamel and dentine exposure without pulp exposure (Figures 11 and 12), crown and root involvement without pulp exposure (Figures 13 and 14), root fracture without crown damage or pulp exposure (Figures 15 and 16), and whether there is pulp exposure, isolated to the crown (Figure 17 and 18) or involving both crown and root (Figure 19 and 20). An injury that does not expose the pulp is termed uncomplicated, whilst pulp exposure is termed complicated.

A tooth that has suffered trauma without fracture may result in painful pulpitis and eventually pulpal necrosis. Some of these teeth will appear dull or discoloured (Figure 21) (termed intrinsic staining) and most require root canal treatment or extraction similar to a tooth with direct pulp exposure (see below) (Hale 2001).

Sequela

All vital teeth with direct pulp exposure are exceedingly painful. (Bender 2000; Hargreaves *et al.* 2004; Hasselgren 2000). In most cases, a non-vital tooth which is not appropriately treated will become infected. Once this occurs, the bacteria gain access to the local tissues via the apex, creating local inflammation and/or infection. This may be seen on radiographs as periapical rarefaction (Figure 22). Patients with non-vital teeth rarely show signs of the pain and or infection, but it is present. Those teeth which are not treated by root canal therapy or extraction may result in a draining sinus tract at or near the apex of the root. The most common sites for this are adjacent to the medial canthus of the eye or lateral bridge of the nose (maxillary canine or premolar), or a sinus tract on the lateral or ventral surface of the mandible (mandibular canine tooth).

Diagnosis

Endodontic examination is incomplete without dental exploration and radiographs to confirm or rule out pulp exposure and to assess the degree of periapical pathology respectively, prior to treatment. If the fracture exposes the pulp chamber, the pulp may appear pink if recent, or grey/black if chronic. In recent fractures, the teeth are quite painful and the patient may resist conscious oral examination. Once the pulp is necrotic, there is usually no pain on probing; however, there is long term low grade pain and infection.

Therapy

Treatment options are directly related to the type and degree of damage as well as the presence or absence of endodontic infection. All teeth with any type of damage should be radiographically examined for signs of non-vitality or inflammation. If there is evidence of this on radiology, root canal therapy or extraction is necessary

- If the defect is confined to the enamel or dentine, without radiographic signs of periapical pathology, smoothing any sharp edges and restoration is all that is required. Treatment of dentin exposure is always recommended to reduce sensitivity, block off the pathway for infection, and smooth the tooth, thus decreasing periodontal disease (Theuns et al 2011).
- Chronic wear results in the production of tertiary or reparative dentine so the tooth pulp continues to be protected by a dentinal layer. These teeth require no therapy, as long as they are radiographically healthy.
- Any tooth with direct pulp exposure or radiographic signs of tooth death/periapical inflammation requires treatment by extraction or root canal therapy to prevent further periapical pathology and subsequent osteomyelitis, which may lead to systemic complications.
 - Vital teeth with direct pulp exposure are quite painful and should be treated expediently. If a therapeutic delay is necessary, pain management should be provided until surgery. Note, however that antibiotics are not indicated in these cases. (Niemic BA 2012)

Teeth with advanced periapical lesions or root resorption may benefit from extraction over root canal treatment.

Key Points:

- Fractures to the crown and/or root of the tooth are a common finding in dogs and cats.
- A complete endodontic examination requires dental exploration and radiographs to confirm or rule out pulp exposure and to assess the degree of periapical pathology respectively, prior to treatment.
- If the defect is confined to the enamel or dentine, without radiographic signs of periapical inflammation, smoothing any sharp edges and restoration is all that is required.
- Any tooth with direct pulp exposure or radiographic signs of tooth death/periapical inflammation requires treatment by extraction or root canal therapy.

References

Hale FA (2001) Localized intrinsic staining of teeth due to pulpitis and pulp necrosis in dogs. Hale FA. J Vet Dent. 18(1):14-20.

Golden AL, Stoller N, Harvey CE. (1982) A survey of oral and dental diseases in dogs anaesthetised at a veterinary hospital. Am Anim Hosp Assoc 18:891-9.

Harvey CE, Shofer FS, Laster L. (1994) Association of age and body weight with periodontal disease in North American dogs. J Vet Dent; 11:94-105.

Andreasen JO, Andreasen FM. (1994) Textbook and colour atlas of traumatic injuries to the teeth. 3rd ed. Copenhagen. Munksgaard,

AVDC website. www.avdc.org

Verstraete FJM, Lommer MJ. (2012) Oral and Maxillofacial Surgery in Dogs and Cassandra Elsevier

Soukup JW, Hetzel S, Paul A. (2015) Classification and Epidemiology of Traumatic Dentoalveolar Injuries in Dogs and Cats: 959 Injuries in 660 Patient Visits (2004-2012). J Vet Dent. 32(1):6-14.

Goldschmidt S, Zimmerman C, Collins C, Hetzel S, Ploeg HL, Soukup JW. (2017) The Influence of Force Direction on the Fracture Pattern and Fracture Resistance of Canine Teeth in Dogs. J Vet Dent.

Furtado MM, Kashivakura CK, Ferro C, (2007) Prevalence of crown trauma in free-ranging maned wolves (*Chrysocyon brachyurus*) in central Brazil. J Vet Dent. 24(4):231-4.

Niemiec BA (2001) Assessment of vital pulp therapy for nine complicated crown fractures and fifty-four crown reductions in dogs and cats. J Vet Dent. 18(3):122-5.

Clarke DE (2001) Vital pulp therapy for complicated crown **fracture** of permanent canine teeth in dogs: a three-year retrospective study. J Vet Dent. 18(3):117-21.

Hale FA, Anthony JM (1996) Treatment of mandibular and **dental fractures** in a young dog. Can Vet J. 37(5):307-9

Theuns P, Niemiec BA: Bonded Sealants for Uncomplicated Crown Fractures. J Vet Dent. 28(2):130-2, 2011.

Niemiec BA (2012) How to address and stabilize dental emergencies: In: Veterinary Dentistry Applications in Emergency Medicine and Critical or Compromised Patients. Practical Veterinary Publishing, San Diego, pp 1-32.

Soukup JW, Hetzel S, Paul A (2015) Classification and Epidemiology of Traumatic Dentoalveolar Injuries in Dogs and Cats: 959 Injuries in 660 Patient Visits (2004-2012).J Vet Dent.32(1):6-14.

Bender IB. (2000) Pulpal pain diagnosis: a review. J Endod. 26:175

Hargreaves KM, Kaiser K. (2004) New advances in the management of endodontic pain emergencies. J Calif Dental Assoc 32:469

Hasselgren G (2000) Pains of dental origin. Den Clin North Am. 12:263

The following terms and abbreviations from the American Veterinary Dental College are used:

Abbreviation	Pathology
T/FX/EI	Enamel Infraction - Incomplete fracture (crack) of the enamel without loss of tooth substance
T/FX/EF	Enamel fracture - fracture in which crown substance is lost, limited to enamel
T/FX/UCF	A fracture of the enamel and dentine not involving the pulp. In veterinary species, the types of dental tissue involved in a crown fracture can vary with the species and can include enamel, cementum, and dentine
T/FX/CCF	A fracture involving enamel and dentine and exposing the pulp
T/FX/UCRF	A fracture involving enamel, dentine, and cementum, but not exposing the pulp
T/FX/CCRF	A fracture involving enamel, dentine, and cementum and exposing the pulp
AB	Tooth wear caused by contact of a tooth with a non-dental object
AT	Tooth wear caused by contact of a tooth with another tooth
EH	Enamel hypoplasia / hypomineralisation

Figures:

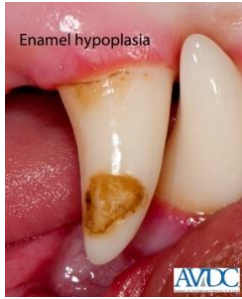


Figure 1. Enamel hypoplasia.

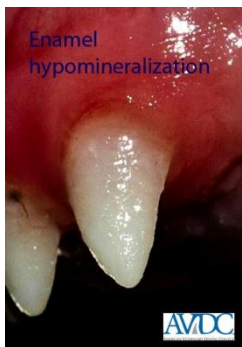


Figure 2. Enamel hypomineralisation.

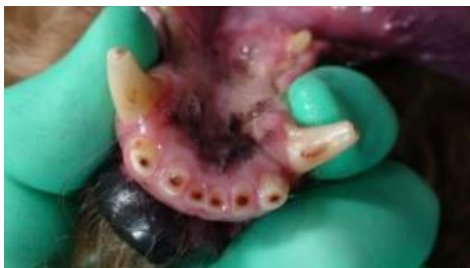

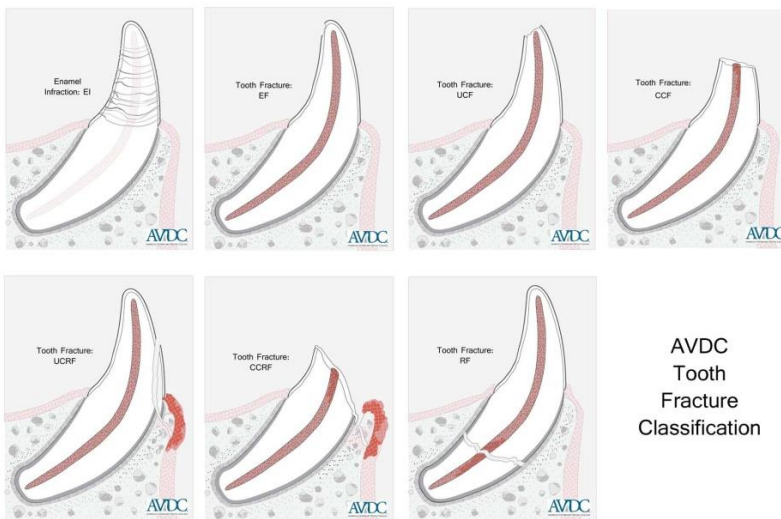
Figure 3. Attrition.

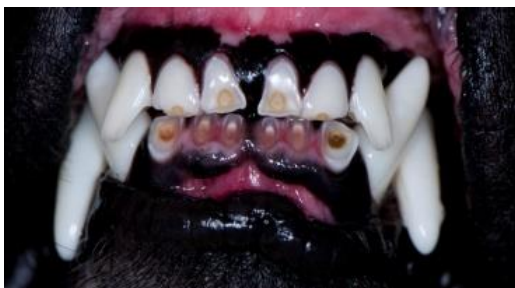

Figure 4. Abrasion.

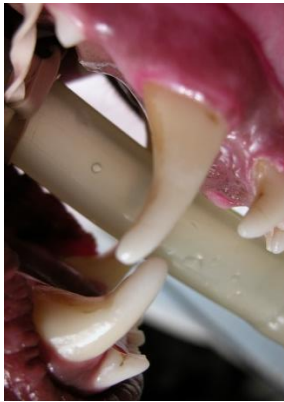

Figure 5: Abrasion on the distal aspect of the right canines in a dog from “fence Chewing”



AVDC
Tooth
Fracture
Classification

Figure 6. AVDC Tooth Fracture Classification.

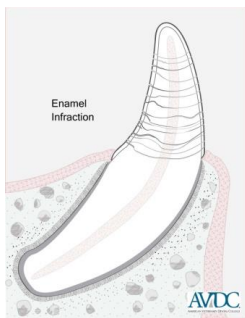


Figure 7. Enamel Infraction.

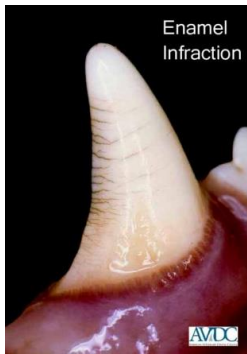


Figure 8. Enamel Infraction.

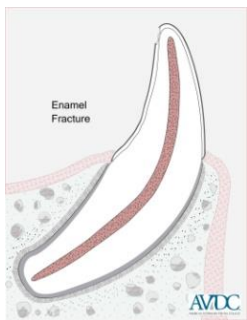


Figure 9. Enamel Fracture.

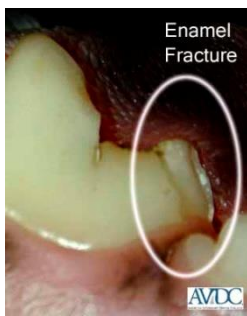

Figure 10. Enamel Fracture.

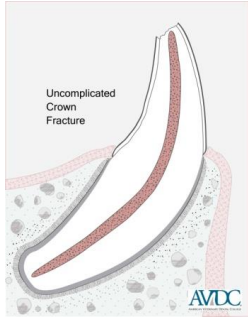


Figure 11. Uncomplicated Crown Fracture.

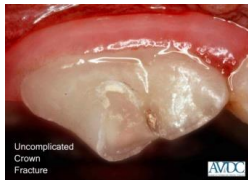

Figure 12. Uncomplicated Crown Fracture.

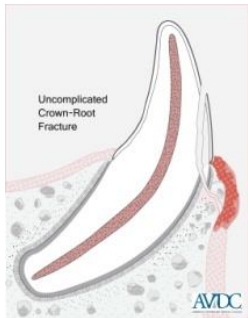


Figure 13. Uncomplicated Crown Root Fracture.

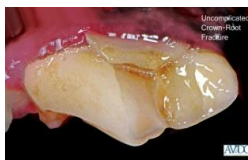

Figure 14. Uncomplicated Crown Root Fracture.

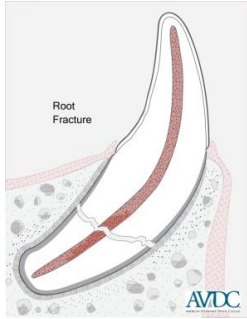


Figure 15. Root Fracture.

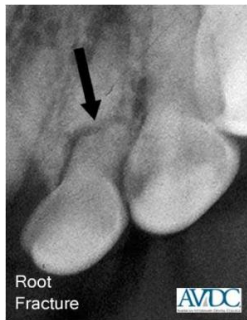

Figure 16. Root Fracture.

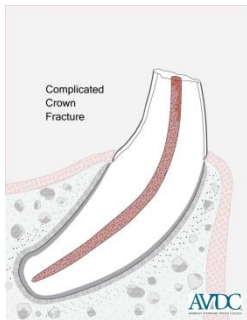


Figure 17. Complicated Crown Fracture.

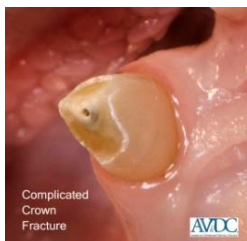


Figure 18. Complicated Crown Fracture.

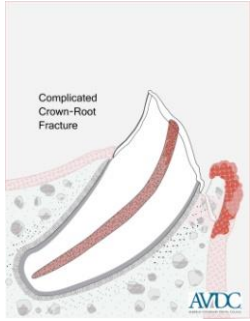


Figure 19. Complicated Crown Root Fracture.

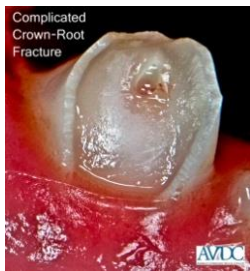


Figure 20. Complicated Crown Root Fracture.

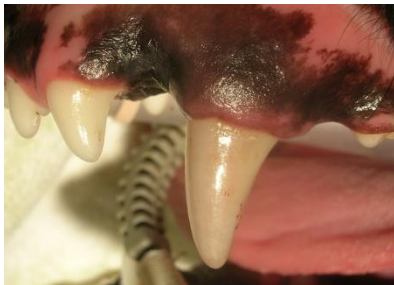

Figure 21: Intrinsic staining (non-vital) tooth

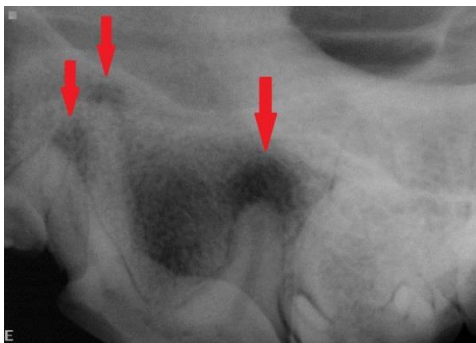


Figure 22: Periapical rarefaction in a non-vital maxillary fourth premolar.

Tooth Resorption

Tooth resorption (TR) is, by definition, the loss of dental hard tissue. Tooth resorption can be physiological (resorption of the root of primary teeth) or pathological. In these guidelines only pathologic TR is discussed.

TR has been reported in human dentistry (Heithersay GS, 2004) and various species including the dog (Arnbjerg 1996), feral cat (Verstraete et al. 1996; Clarke and Cameron 1997), chinchilla (Crossley et al. 1997) and horse (Henry et al 2016). In veterinary dentistry, it is of most importance in the domestic cat where it occurs quite frequently, and it is increasingly noted in the canine population. In a study, which investigated the incidence of TR in a clinically healthy population of 228 cats using a combination of clinical examination and radiography, it was found that the mandibular 3rd premolars (307, 407) were the most commonly affected teeth and the pattern of TR development was symmetrical in most cats (Ingham KE et al. 2001).

Aetiology

The resorptive process is quite well understood (Okuda and Harvey 1992; Shigeyana et al. 1996), however the aetiology of most TR is not clear. Resorption was traditionally considered a disease of modern civilisation but it has also been reported in wild cats (Berger et al. 1996; Levin 1996) and in the late medieval era (Berger et al., 2004) which directly contradicts that theory.

Tooth resorption is due to an active process where odontoclasts become activated. The resorption appears to be a progressive process. It initiates on the root surface, typically at the cemento-enamel junction in type 1 lesions. It then invades the root and spreads within the root dentine up into the coronal dentine, where it may undermine the enamel. This loss of support may cause the enamel to collapse or break off. Therefore, clinical findings (visual or tactile), even if they are very small, represent an advanced stage of the disease (Fig. 1).

There appear to be two distinct types of tooth resorption: idiopathic and inflammatory. (Dupont G 2010, Niemiec BA 2008). Any trauma can create resorption of the root surface, however some of these defects heal while others do not. A possible etiopathogenic model for 'idiopathic' feline external root resorption is that an area of tooth trauma which does not properly heal will lead to dentine exposure and eventually ankylosis and replacement resorption (Gorell et al. 2013). (Fig. 2)

Below the gum line, resorbed areas are replaced by cementum- or bone-like material. The pulp resists becoming exposed by the resorption by the creation of tertiary dentin until late in the disease course. Above the gum line, smaller defects are often covered by a highly vascular granulation tissue, which is an attempt by the body to cover the exposed dentine tubules (Fig. 3).

Classification

A distinction is made depending on the localisation of the resorption: internal resorption starts within the endodontic system and is mostly due to pulpitis. External resorption has its origin at the root surface and can have several causes. In an advanced stage, the two forms can hardly be distinguished. In dogs and especially cats, external resorption is much more common.

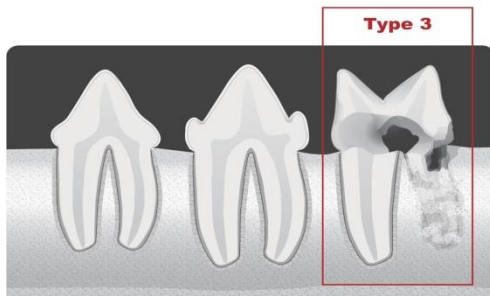
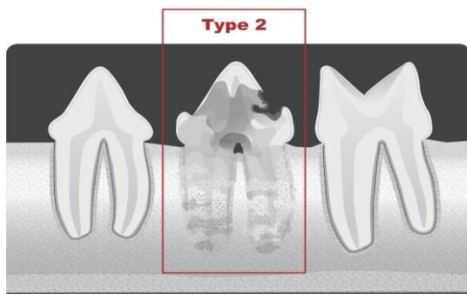
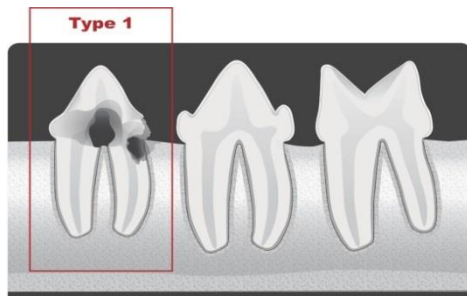
Tooth resorption is classified based on the severity of the resorption (Stages 1-5) and on the radiographic appearance of the resorption (Types 1-3) (American Veterinary Dental College, 2017). The AVDC classification of tooth resorption assumes that tooth resorption is a progressive condition.

Types of Resorption Based on Radiographic Appearance

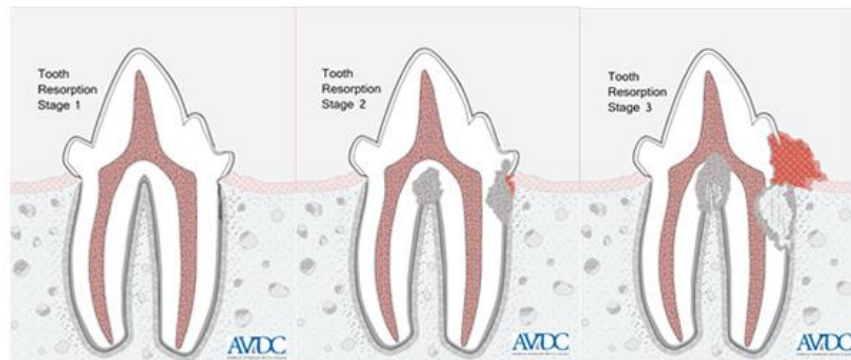
Type 1 (T1): On a radiograph of a tooth with type 1 (T1) appearance, a focal or multifocal radiolucencies are present in the tooth with otherwise normal radiopacity and normal periodontal ligament space and endodontic system. There is tooth destruction but no replacement.

Type 2 (T2): On a radiograph of a tooth with type 2 (T2) appearance, there is narrowing or obliteration of the periodontal ligament space in at least some areas and decreased radiopacity of at least part of the tooth. There are signs of replacement resorption.

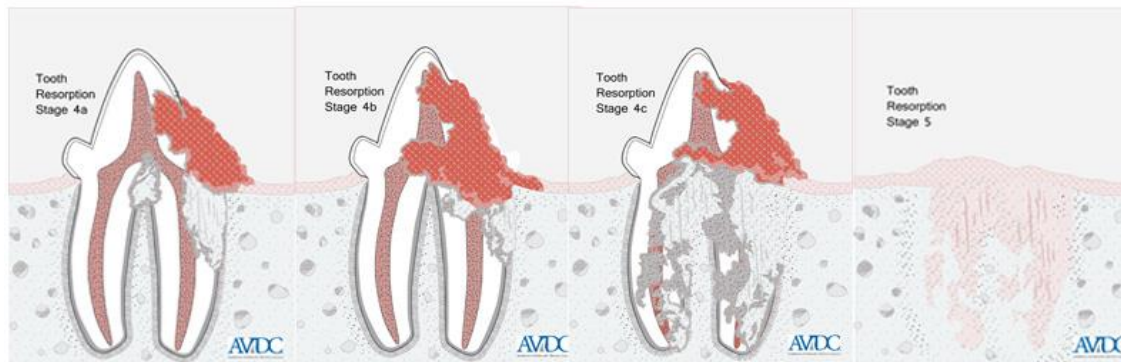
Type 3 (T3): On a radiograph of a tooth with type 3 (T3) appearance, features of both type 1 and type 2 are present in the same tooth. A tooth with this appearance has areas of normal and narrow or lost periodontal ligament space, and there are focal or multifocal radiolucencies in the tooth and decreased radiopacity in other areas of the tooth.



Stage of Resorption Based on Radiographic Appearance



Tooth Resorption - AVDC Classification of Clinical Stages



Stage 1 (TR 1): Mild dental hard tissue loss (cementum or cementum and enamel).

Stage 2 (TR 2): Moderate dental hard tissue loss (cementum or cementum and enamel with loss of dentin that does not extend to the pulp cavity).

Stage 3 (TR 3): Deep dental hard tissue loss (cementum or cementum and enamel with loss of dentin that extends to the pulp cavity); most of the tooth retains its integrity.

Stage 4 (TR 4): Extensive dental hard tissue loss (cementum or cementum and enamel with loss of dentin that extends to the pulp cavity); most of the tooth has lost its integrity.

- **TR4a:** Crown and root are equally affected;
- **TR4b:** Crown is more severely affected than the root;
- **TR4c:** Root is more severely affected than the crown.

Stage 5 (TR 5): Remnants of dental hard tissue are visible only as irregular radiopacities, and gingival covering is complete.

Several types and stages of TR can coexist in the same patient. *Fig. 4*

Clinical significance

TR is very common in domestic cats. Studies have shown that 20 to 75% of mature cats are clinically affected depending on the population examined (Bellows J, 2009).

In the human dental literature, it is reported that the process does not seem to be painful if it stays below the gingival margin (Heithersay GS, 2004). When the process reaches the cemento enamel junction or the enamel collapses over the resorbed space, the dentine is exposed which results in significant pain as well as the possibility of infection in type 1 lesions. The initial pain (dental sensitivity) occurs due to change of capillary flow in the dentinal tubules (the hydrodynamic theory of pulp hypersensitivity) (Barnstorm M, 1986) The pulp is then indirectly exposed to bacterial contamination, which results in possible endodontic infection. Therefore, dentinal exposure due to TR is painful and/or can create local infection.

Clinical findings

Until the process reaches the oral cavity, there will be no clinical (visual or tactile) findings. At an early clinical stage, the gingival margin may be inflamed or minor enamel and dentine defects will be covered by highly vascular tissue. With progressive resorption, partial or even complete loss of the crown is possible.

Affected patients may show secondary signs of this dental disorder (Bellows J 2010, Furman RB Niemiec BA 2013) such as:

- *change of behaviours* : decreased grooming, picking at and dropping food, pawing at mouth, hiding, lethargy
- *signs of oral discomfort* : sticky mucus on the lips and/or paws, head shaking, rubbing the mouth on the ground, tooth grinding

However, the lack of these signs should not be misconstrued as evidence that there are no lesions or that they are not painful (Dupont G 2010, Holmstrom SE et al 1998, Niemiec BA 2008). The clear majority of cats affected by this condition show no outward clinical signs of discomfort.

Examination and Diagnosis

The examination is based on three diagnostic modalities (Bellows J, 2009 Niemiec BA 2015):

Visual examination: the visual examination only allows detection of very late stage disease, once the crown is involved.

Tactile exploration: the entire surface of each tooth must be examined with a dental explorer, especially at the gingival margin. Intact enamel is very smooth. If there is a resorptive lesion present, the explorer catches. Even the slightest roughening is a clear sign of such a lesion or subgingival calculus. If there is any doubt as to the aetiology, the defect should be re-evaluated following scaling.

Dental radiographs: for a complete staging and treatment planning, dental radiographs are mandatory. It is highly recommended to take a full mouth radiograph study of all feline patients presented for dental examination. If the owner is financially limited there is an option to radiograph the mandibular 3rd premolars as sentinel teeth (Ingham KE et al. 2001) (for detailed information, see chapter 2c: Radiology)

Differential diagnoses: tooth resorption might be mistaken for a tooth fracture, abrasion, or furcation exposure. To differentiate between a TR and furcation exposure, it should be noted that TR is rough while furcation exposure is generally smooth.

Treatment options

The aim of treatment is pain relief and infection control for the patient. As TR is a process caused by the patient's own cells (odontoclasts), restoration of the defects is not indicated. The treatment will depend on the clinical situation:

Monitoring

If tooth resorption is radiographically diagnosed, but has not progressed into the oral cavity, clinical and radiographic monitoring is indicated. The monitoring recalls must be performed on a regular basis to ensure that a surgical intervention may be performed expediently. If this is not possible, extraction or crown amputation should be considered.

Extraction

Best practice is the extraction of the affected tooth. It is important to make sure that all roots are removed entirely. This must be confirmed radiographically. Drilling or "atomising" the roots with a bur (root pulverization) is strongly discouraged. (For more information see extraction section)

Crown amputation

In type 2 resorption, where the root has been fully or partly replaced by bone tissue, extraction can be very difficult if not impossible. In such cases a crown amputation may be indicated (DuPont, 1995) but only when the following criteria are fulfilled:

- No radiographic evidence of an endodontic system
- No periodontal ligament visible on the dental radiograph
- No clinical or radiographic signs of endodontic or periodontal pathology
- No evidence of caudal stomatitis
 - In these cases, as much of the "root" should be removed as possible.

Crown amputation involves the creation of an envelope gingival flap, removal of all tooth substance down 1-2 mm below bone level with a dental bur and suturing of the gingiva. In type 3 resorption, the type 2 root can be amputated while the type 1 root should be extracted (*Fig. 5*)

Key Points:

- Tooth resorption is a progressive process
- This condition is painful, despite the typical lack of clinical signs.
- There are two types of tooth resorption, types 1 and 2, with different therapy recommended
- Gold standard for treatment is extraction
- Crown amputation is only indicated when the following criteria are visible on the dental radiograph:
 - Advanced type 2 resorption
 - No periodontal ligament
 - No endodontic system
 - No evidence for periodontal disease
 - No evidence for endodontic pathology
 - No evidence of caudal stomatitis

References:

Heithersay GS (2004) Invasive cervical resorption. *Endodontic topics* 7: 73-92.\

Arnbjerg J (1996) Idiopathic dental root replacement resorption in old dogs. *Journal of Veterinary Dentistry* 13(3), 97-99

Verstraete FJM, Aarde Van RJ, Nieuwoudt BA et al. (1996) The dental pathology of feral cats on Marion Island. Part II: periodontitis, external odontoclastic resorptive lesions and mandibular thickening. *Journal of Comparative Pathology* 115, 283-297

Clarke DE, Cameron A (1997) Feline dental resorptive lesions in domestic and feral cats and the possible link with diet. Proceedings of the 5th World Veterinary Dental Congress, April 1 to 3, Birmingham, UK. pp 33-34.

Crossley D, Dubielzig R, Benson K (1997) Caries and odontoclastic resorptive lesions in a chinchilla (*Chinchilla lanigera*). *Veterinary Record* 141(13): 337-339

Henry TJ, Puchalski SM, Arzi B, Kass PH, Verstraete FJ. (2016) Radiographic evaluation in clinical practice of the types and stage of incisor tooth resorption and hypercementosis in horses. *Equine Vet J.* 12. (e-pub ahead of print)

Okuda A, Harvey CE (1992) Etiopathogenesis of feline dental resorptive lesions. In: *Feline Dentistry. Veterinary Clinics of North America: Small Animal Practice.* W. B. Saunders, Philadelphia. pp 1385-1404.

Shigeyana Y, Grove TK, Strayhorn C et al. (1996) Expression of adhesion molecules during tooth resorption in feline teeth: a model system for aggressive osteoclastic activity. *Journal of Dental Research* 75(9): 1650-1657

Berger M, Schawalter P, Stich H et al. (1996) Feline dental resorptive lesions in captive and wild leopards and lions. *Journal of Veterinary Dentistry* 13(1): 13-21

- Levin J (1996) Tooth resorption in a Siberian tiger. Proceedings of the 10th Annual Veterinary Dental Forum, October 31 to November 2, Houston, Texas, USA. pp 212-214.
- Berger M et al. (2004) Feline Dental Resorptive Lesions in the 13th to 14th Centuries. *Journal of Veterinary Dentistry* 21(4): 206-213
- Dupont G: (2010) Pathologies of the Dental Hard Tissues. In: Small Animal Dental, Oral and Maxillofacial Disease-A Color Handbook (Niemiec BA ed.). London, Manson. pp 128-59.
- Niemiec BA (2015) Feline Tooth Resorption. In: Feline Dentistry for the General Practitioner. Practical Veterinary Publishing, San Diego, pp 48-53
- Niemiec BA (2008): Oral Pathology. *Top Companion Anim Med.* 23(2):59-71.
- Gorell C, Andersson S, Verhaert L (2013) Resorptive lesions. In: Veterinary Dentistry for the General Practitioner. 2nd Edition. Ed C. Gorell. WB Saunders, Philadelphia, pp 511-556
- American Veterinary Dental College (2017), <http://www.avdc.org> (accessed 29 April 2017)
- Bellows J (2009) Tooth resorption. In: Feline Dentistry. Ed J. Bellows. Wiley-Blackwell, Ames. pp 229-248.
- Bellows J: (2010) Oral Pathology. In: Feline Dentistry, Oral assessment, treatment, and preventative care. Ames, Wiley Blackwell. pp 101-48.
- Furman RB, Niemiec BA: (2013) Salvation. In: Canine and Feline Gastroenterology (Washabau RJ, Day MJ eds). St. Louis, Elsevier. pp 162-6.
- Holmstrom SE, Frost P, Eisner ER: (1998) Endodontics. In: Veterinary Dental Techniques, 2nd ed. Philadelphia, WB Saunders. pp 312-7.
- Bellows J (2009) Oral examination. In: Feline Dentistry. Ed J. Bellows. Wiley-Blackwell, Ames. pp 83-99
- Ingham KE, Gorell C, Blackburn JM et al. (2001) Prevalence of odontoclastic resorptive lesions in a clinically healthy cat population. *Journal of Small Animal Practice* 42(9): 439-443
- DuPont G (1995) Crown amputation with intentional root retention for advanced feline resorptive lesions. A clinical study. *Journal of Veterinary Dentistry* 12(1): 9-13.
- Niemiec BA (2008): Oral Pathology. *Top Companion Anim Med.* 23(2):59-71.
- Brännström M (1986) The hydrodynamic theory of dentinal pain. *Journal of Endodontics* 12(10): 453-457
- Ingham KE, Gorell C, Blackburn JM et al. (2001) Prevalence of odontoclastic resorptive lesions in a clinically healthy cat population. *Journal of Small Animal Practice* 42(9): 439-443.

Figures:

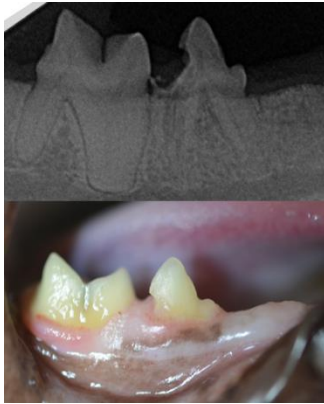


Figure 1: Intraoral dental radiograph of the right mandible of a cat showing an advanced type 2 resorptive lesion on the distal aspect of the right mandibular P4 (408) (top). The intraoral dental picture reveals only a small defect

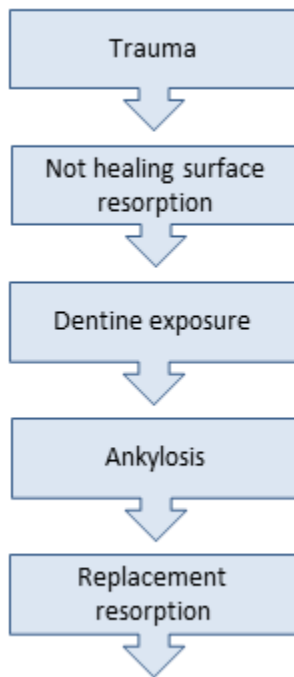


Figure 2: Possible etiology of type 2 TRs.

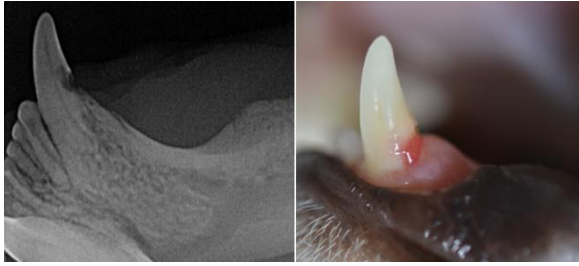

Figure 3: Intraoral dental radiograph (left) and picture (right) of the left mandible of a cat showing a type 2 resorptive lesion on the distal aspect of the left mandibular canine (304).

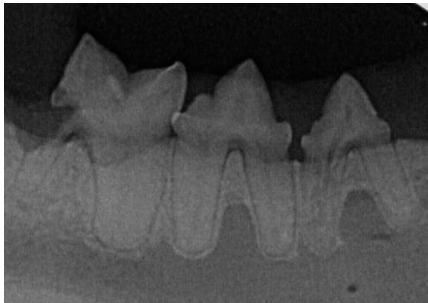

Figure 4: Intraoral dental radiograph of the right mandible of a cat showing a type 1 resorptive lesion on the distal root of the first molar (409) and type 2 resorption on the distal root of the 3rd premolar (407)

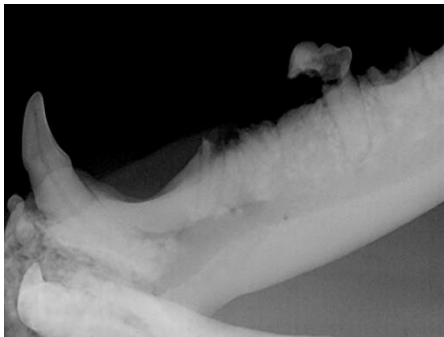

Figure 5: Intraoral dental radiograph of the left mandible of a cat showing a type 3 resorptive lesion on fourth premolar (408). The mesial root is resorbed, while the distal root maintains its normal root structure.

Maxillofacial Trauma

Maxillofacial trauma is a fairly common occurrence and can affect both the soft and hard tissues (bones and teeth) and often both. Patients with maxillofacial trauma may present with complaints of facial swelling or distortion, oral bleeding, salivation, and abnormal closure of the mouth, however they often demonstrate minimal to no clinical signs.

At all times, practitioners must be cognizant of the possibility of brain edema, and other such non-visible trauma to underlying structures of the head. In addition, the trauma may have created cardiothoracic and/or abdominal injuries. Because these conditions can be life threatening, they should be evaluated for and treated prior to definitive care of the oral cavity.

Initial exam may uncover lacerations, especially to the lips and/or tongue. The oral cavity has two advantages when compared to other soft tissues: the presence of saliva and ample vascularization. Saliva provides immunological barriers to infection such as IgA, bacteriostatic enzymes, and a physical cleansing action which flushes out bacteria. These actions assist the healing process, and provide some protection against infection. The high level of vascularization in the oral cavity is helpful with healing, which may allow for decreased debridement.

The cosmetic repairs of facial trauma may be of concern to the owner. Consideration should be taken to create the most cosmetic result to facilitate healing. Reconstructive surgery may be necessary in order to assist with more aesthetic healing. Comfort and function should be the primary aim or reconstruction.

Soft Tissue Trauma

The most common soft tissue injuries to the mouth caused by trauma are:

- Degloving injuries, especially of the lower lip, caused by high speed traumas and vehicular accidents (Figure 1)
- Lip lacerations due to fighting (Figure 2)
- Tongue lacerations/damage due to fighting, car accidents, or electrical shock (Figure 3)
- Gingival lacerations (Figure 4) and periodontal trauma
- Hard palate lesions such as high rise syndrome (Figure 5)
- Soft tissue trauma from caustic agents or electric shock (Figure 6)

Reparative surgery should be performed expediently for all oral soft tissue lesions, if the patient is stable (see above). Diseased/non-vital tissue should be debrided prior to closure. Closure should be delayed if further necrosis is expected (injuries due to caustic or electrical shock) (Niemic BA 2012). However, due to the high vascularity, moderately damaged tissue can be maintained. One important aspect to be taken into consideration is the preservation of the attached gingiva during soft tissue surgery. All teeth should be covered by at least 2 mm of gingiva where possible; however, teeth can be healthy despite less coverage (Niemic BA 2012; Takas VJ 1995; Lewis JR & Reiter AM 2005; Wolf HF et al 2005).

There are many suitable options for suture material when addressing oral trauma. The sutures should be simple interrupted and placed 2-3 mm apart. (Niemic BA 2008) (Figure 6)

Absorbable non-braided sutures are preferred on a swedged-on reverse cutting needle are generally recommended (Harvey CE 2003). (see equipment chapter)

Hard tissue trauma

The various types of hard tissue trauma include maxillofacial fractures (Figures 7 and 8), TMJ fractures and luxations, (Figure 9) and tooth luxations (Figure 10) and avulsions (Figure 11) (Taney KG & Smith MM 2010; Niemiec BA 2012, Verstraete 2012). When teeth or bones are affected, always conduct a thorough oral examination. Initial examination can be attempted while awake, but a full exam and dental radiographs are only possible under general anaesthesia.

Maxillofacial fractures

When bones of the face are fractured, basic orthopedic principles must be kept in mind. However, there are three major differences between maxillofacial and long bone fractures. (Verstraete FJ 2012) Two of these are anatomic: the tooth roots and neurovascular structures within the mandibular canal. These 2 structures cannot be injured during therapy. (Figure 12) This means no that invasive fixation methods (pins or plates) can be inserted into or through them. Therefore, external fixation is strongly discouraged for maxillofacial fractures, because of the risk of traumatic pin placement (Gioso M et al 2001; Taney KG & Smith MM 2010). (Figure 13) Mini bone plates may be useful in certain situations, but care must be taken to ensure atraumatic placement of the screws. (Figure 14)

The other potential difference between appendicular and maxillofacial fractures is the commonality of pathological fracture (Niemiec BA 2012). These may occur due to a neoplastic or cystic (Figure 15) cause, but in the clear majority of cases they are secondary to advanced periodontal disease. These fractures typically occur in the mandible (especially the area of the canines and first molars) due to extensive periodontal loss which weakens the bone in affected areas (Figures 16, 17) (Niemiec BA 2008). This condition is more common in small breed dogs (Mulligan T et al 1998), owing mostly to the fact that their teeth (especially the mandibular first molar) are larger in proportion to their mandible in comparison to large breed dogs (Figure 18) (Gioso MA et al 2000,). Therefore, small breed dogs have a very minimal amount of bone apical to the tooth root, putting this area at high risk of fracture when periodontal bone loss occurs. Diagnosis is only generally possible with made on dental radiography.

Pathologic fractures (see periodontal disease section) carry a guarded prognosis for several reasons. (Taney KG & Smith MM 2010) Adequate healing is difficult to obtain due to lack of remaining bone, low oxygen tension in the area, and difficulty in rigidly stabilizing the caudal mandible. (Niemiec BA 2008, Holmstrom SE et al 1998) There are numerous options for fixation, but the use of invasive techniques is generally required. Regardless of the method of fixation, the periodontally diseased root(s) must be extracted for healing to occur (Figures 19 and 20) (Niemiec BA 2012, Taney KG & Smith MM 2010).

Diagnosis

Standard medical radiography equipment has limitations when evaluating oro-maxillo-facial fractures; however, when CT and/or dental radiographs are not available this modality can provide useful information (Niemic BA 2011). (Figure 21) However, in tier 1 and some tier 2 countries, they are considered minimally acceptable. Dental radiographs are recommended whenever possible and should be considered a minimum requirement in tier 3 countries. (Figure 22) However, Computerized Tomography or cone beam CT (CBCT) scans are ideal for maxillofacial fracture diagnosis and treatment planning. (Figure 23)

Therapeutic measures

There are invasive (insertions into bone), and non-invasive (intraoral splints, tape muzzle) methods of fracture stabilization. The invasive methods include interfragmentary wiring, (Figure 24) external fixators, and mini-plates. Invasive methods should be only being used in carefully selected cases taking the anatomy and occlusion into account. In addition, invasive methods require a future surgery for removal of the implants is necessary, unless biocompatible plating material is used (eg. titanium (Wiggs RB & Lobprise HB 1997; Taney KG & Smith MM 2010).

The noninvasive methods utilize interdental or circummandibular wires (Figure 25) and/or acrylic resins (Figure 26) for fracture fixation (Taney KG & Smith MM 2010; Niemic BA 2003). These techniques can be cost effective and easy to learn. Potential drawback with non-invasive fixation is that only the coronal aspect of the jaw is fixated and not as sturdy as invasive methods. The reader is directed to Verstraete *et al* (2015) for these techniques.

A very simple emergency (and in some cases, especially in juvenile animals, also final) treatment is placing a (tape or nylon) muzzle or elastic face mask to provide support to the fractured bones.

Tooth luxation/avulsion

An avulsed tooth has been traumatically torn out of the alveolus (Niemic BA 2012, Taney KG & Smith MM 2010). A luxated tooth is partially distracted from the alveolus but is still attached. The tooth may be luxated in the buccal direction, which usually involves fracture of the buccal alveolar wall as well. This most commonly occurs with the canine teeth (especially maxillary), but incisors can be affected as well (Wiggs RB & Lobprise HB 1997). This typically occurs following dog fights, but can also result from significant cage chewing or trauma (Gracias M & Orsini P 1998; Spodkic GJ 1992). Tooth intrusion injuries are severe in that they most commonly result in disruption of the neurovascular structures.

Clinical presentation

These patients will either present with a swelling on the muzzle or a missing tooth (Niemic BA 2012). Oral exam reveals a displaced tooth or an empty alveolus (Figure 27).

Diagnosis

Skull films are useful, however are typically not detailed enough to diagnose subtle problems such as root fractures (Figure 28a), periodontal disease (Figure 28 b) or small areas missing bone

(Niemic BA 2011). Therefore, dental radiography or CT is recommended prior to fixation (Niemic BA 2012).

Where possible, these cases should be referred to a veterinary dentist as soon as possible for replacement and stabilization. However, if this is not feasible due to schedule or the stability of the patient, good results may still be possible despite a short delay. The fixation method is typically a figure-8 wire and acrylic splint (Figure 29) (Niemic BA 2012). However, these teeth require root canal therapy due to non-vitality secondary to disruption of the blood supply. Therefore, if root canal therapy is not an option, extraction is preferred. Extraction is always performed for luxated/avulsed deciduous teeth.

KEY POINTS

- Minimal debridement is recommended for oral trauma due to the rich blood supply
- Non-invasive methods (acrylic splints and interdental wiring) are preferred for fixation of oral fractures.
- External fixators are not recommended; however properly adapted mini-plates may be indicated.
- Dental radiographs provide critical information in oral trauma cases.
- Pathologic fractures are common in small and toy breed dogs and must be taken into consideration in the management of fractures in these breeds.
- Infected teeth must be extracted from fracture sites.
- Replaced avulsed teeth require endodontic therapy.

References:

Niemic BA: (2012) Local and regional consequences of Periodontal disease. In: Veterinary Periodontology. Niemic BA ed. John Wiles and Sons, Ames, pp 69-80.

Lewis JR, Reiter AM (2005) Management of generalized gingival enlargement in a dog-case report and literature review. *J Vet Dent.* 22 (3): 160 – 169.

Tackas VJ (1995) Root coverage techniques: A review. *J West Soc Periodontol Periodontal Abstr.* 43 (1): 5–14.

Wolf HF, Rateitschak EM, Rateitschak KH, Hassell TH. (2005) *Color Atlas of Dental Medicine: Periodontology* 3rd ed. Stuttgart: Thieme.

Niemic BA (2008) Extraction techniques. *Top Companion Anim Med.* 23:97–105.

Harvey CE & Emily PP. *Oral Surgery* (1993). In: C.E. Harvey, P.P. Emily (Eds.) *Small Animal Dentistry*. Mosby-Year Book, St. Louis.

Taney KG, Smith MM: (2010) Problems with the bones, muscles and joints. In: *Small Animal dental, oral and maxillofacial disease, a color handbook* (Niemic BA ed). London, Manson. pp 189-223.

Niemiec BA (2012) How to address and stabilize dental emergencies: In: Veterinary Dentistry Applications in Emergency Medicine and Critical or Compromised Patients. Practical Veterinary Publishing, San Diego, pp 1-32.

Gioso, M. A. et al. (2001) Clinical and Histological Evaluation of Acrylic Resin in the fracture of the Mandible and Maxilla and Separation of Mandibular symphysis in dogs and cats. Cienc. Rural vol.31 no.2 Santa Maria.

Niemiec, BA: Periodontal disease. Top Companion Anim Med. 2008;23(2):72-80.

Mulligan T, Aller S, Williams C (1998) Atlas of Canine and Feline Dental Radiography. Trenton, New Jersey, Veterinary Learning Systems, 1998, P. 176-183.

Gioso MA, Shofer F, Barros PS, Harvey CE: Mandible and mandibular first molar tooth measurements in dogs: relationship of radiographic height to body weight. J Vet Dent 18(2): 65-8

Holmstrom SE, Frost P, Eisner ER: (1998) Exodontics, in Veterinary Dental Techniques (ed 2) Philadelphia, PA, Saunders, pp 215-254.

Niemiec BA: (2011) The Importance of Dental Radiology. Eur J Comp Anim Pract. 20(3): 219-29.

Wiggs RB, Lobprise HB: (1997) Oral Surgery. In: Veterinary Dentistry: Principles and Practice. Lippincott-Raven, Philadelphia.

Niemiec BA: Intraoral acrylic splint application. J Vet Dent. 20(2):123-6, 2003.

Gracis M, Orsini P: (1998) Treatment of traumatic dental displacement in dogs: six cases of lateral luxation. J Vet Dent. 15:65-72.

Spodnick GJ: (1992) Replantation of a maxillary canine after traumatic avulsion in a dog. J Vet Dent. 9:4-7.

In: Oral and maxillofacial surgery in dogs and cats. Frank JM Verstraete and Melinda J Lomer. Saunders Elsevier. pp

Oral Tumors

Tumour means “swelling”, or an abnormal growth. Tumours in the oral cavity are divided into benign or malignant, and whether they are of odontogenic origin or not. The term “epulis” has been misused for decades as the description of a benign oral growth. In actuality an epulis is any abnormal growth arising from the gingiva, which may include malignant tumours. Oral tumours account for approximately 7% of tumours in dogs and about 10% in cats.

Benign Tumours

Benign tumours range from minor enlargements of the gingiva to locally proliferative lesions that cause tooth movement and/or tooth resorption. Oral swellings may also include cysts and abscesses.

Gingival enlargement is an area of gingival overgrowth, but needs to be differentiated histopathologically from other oral masses. This condition is generally caused by gingival hyperplasia, which is an overgrowth of fairly normal gingival tissues. Gingival hyperplasia (GH) can have a genetic predisposition (e.g. Boxers), be caused by certain medications (i.e. cyclosporine, phenobarbital, calcium channel blockers), or be attributed to plaque-induced gingival inflammation. If the GH is caused by a drug, discontinuation of the medication will often allow the gingiva to return to normal. Plaque-induced GH is responsive to gingivoplasty and gingivectomy, and can be controlled by daily tooth brushing and effective dental home care. When overgrowth is determined to be genetically induced and other sources have been ruled out, it is best treated by gingivectomy. However, eventual regrowth is expected. (Force J Niemiec BA 2009, Niemiec BA 2012)

Peripheral Odontogenic Fibromas

Peripheral odontogenic fibromas (previously called fibromatous epulis of periodontal ligament origin) are very common oral growths in dogs, and can be fibrous or ossifying. (Chamberlain et al 2012, DeBowes 2010) They arise from the periodontal ligament and create localised firm swellings. While marginal excision may suffice for control, excision of the tooth and complete debridement of its periodontium is required to achieve a cure.

Odontomas

Odontomas are comprised of regular dental tissue that has grown in an irregular manner (hamartomas). (Niemiec BA 2010) Compound odontomas are hamartomas which contain numerous complete tooth-like structures. Complex odontomas contain structures derived from individual tooth components – enamel, dentine, cementum and pulp. Marginal excision will prove curative for both of these lesions. However, it is very common to create large voids during surgery which should be addressed with bone augmentation and fastidious closure. (Head KW 2008)

Oral cysts

Oral cysts include dentigerous cysts, which arise from remnants of the enamel organ that is embedded or impacted (failed to erupt into the mouth). (Verstraete FJR et al 2012, Head KW 2008) In the cysts are often associated with impacted mandibular P1 teeth, especially in

brachiocephalic breeds, (Niemiec BA 2010) The incidence of cystic formation in impacted teeth in dogs was reported to be 29% (Babbit et al 2016) hence the necessity of taking radiographs of all “missing” teeth (Niemiec BA 2011)

Cysts can range from small and almost invisible radiographically, to extensive, causing resorption of the bone and/or roots of the premolars occasionally extending from mandibular P1 rostrally to P4 caudally. These cysts can even extend rostrally beyond the canine, causing bone resorption around some of the ipsilateral incisors. Occasionally, cysts are palpable as fluctuant enlargements of the gingiva, but most often are identified on dental radiographs. Cysts can generally be diagnosed radiographically, but should be confirmed histopathologically (presence of an epithelial lining associated with the cemento-enamel junction of the retained tooth).

Treatment involves excision of the affected tooth / teeth and complete debridement of the cystic epithelial lining. The resultant cavity is allowed to fill with blood and suturing the gingiva closed will enable new bone to develop within the jaw. While the blood clot supplies all necessary products for bone healing, larger defects may benefit from bone augmentation. About 3 months following surgery, new bone will be found to completely fill the original cyst site and lamina dura and periodontal ligament space will be evident around previously bone-denuded teeth roots.

Acanthomatous ameloblastoma (AA)

Acanthomatous ameloblastoma (AA) (also known as acanthomatous epulis of dogs) is a benign tumour that is locally invasive and typically causes movement of the dentition. (Chamberlain et al 2012, Head et al 2002) The peripheral type causes bone enlargement and movement of some teeth, while the central lesion may be associated with a cyst-like lesion within the jaw. These growths often have a fleshy appearance and are most commonly seen around the canine and incisor teeth. Large breed dogs are predisposed. These lesions are best treated by excision with at least 5-10 mm margins, depending upon the site of the lesion. These tumours are also quite radiation sensitive, resulting in up to a 90% control rate (Thrall 1984, Theon 1997) However, this modality can have significant negative consequences (eg malignant transformation), so is generally reserved for inoperable cases. (Thrall 1981) Finally, intralesional bleomycin has been shown to be an effective treatment modality. (Kelly JM et al 2010, Yoshida K et al 1998)

Plasmacytoma

This is an uncommon oral tumour which behaves in a biologically similar way to AA above. They are very locally aggressive, but do not appear to metastasise. Surgical excision with 5-10 mm margins is curative in most cases. In addition, they are very radiosensitive, generally proving curative.

Transmissible venereal tumours (TVT) of dogs

While typically found on the genitals, these tumours can also be found in the oral cavity. They are virtually unheard of in tier 3 countries, but must be on the differential list in geographic areas where TVT are prevalent (typically tropical and subtropical climates). (Ganguly B 2016, Lapa FAS 2012) Histopathology is necessary to differentiate them from lymphoma and other round-cell lesions. (Chikweto A 2013, Kabuusu RM 2010). The typical therapy is IV vincristine, which is generally curative. (Das U, Das AK 2000, Scarpelli KC et al 2010) However, it has been reported that these tumours may also be self-limiting, and the host is then immune. (Welsh JS 2011)

Papillomatosis

Papillomas may present in the oral cavity and on the lips of young animals. Generally viral in origin, they can also be idiopathic. They are white, grey, or flesh coloured masses which are generally pedunculated. They occur both singly and in bunches. While these lesions are usually self-limiting in severe cases the lesions become secondarily infected and can affect appetite. Malignant transformation to SCC has been known to occur. In advanced cases, surgical excision or debulking with histopathology is recommended. Alternative therapeutic modalities include autogenous vaccination and traumatic crushing; these, however, have not been overly successful. (Niemi BA 2010)

Eosinophilic granuloma complex (ECG)

These lesions are a group of related masses in the mouths of cats. The most common is the indolent ulcer variety found on the upper incisor lip and/or philtrum, colloquially called “rodent ulcers”. Linear granulomas can be seen anywhere in the mouth, and are the more aggressive type, possibly resulting in mandibular fracture or oronasal fistulas. Finally, collagenolytic granulomas appear as a firmly swollen, but non-inflamed, lip in the rostral area of the mandible. These are most commonly seen in young, female cats. (Niemi BA 2015)

In the majority of cases, the aetiology of these lesions is unknown. However, a local accumulation of eosinophils and their release of granule contents is proposed to initiate the inflammatory reaction and secondary necrosis. The accumulations commonly result from local (food) or systemic allergies; although these lesions have been seen in cases where allergic disease has been ruled out. Additional proposed causal agents include response to irritation, genetic predisposition, insect bites (flea and mosquito), and bacterial, fungal, viral, and autoallergen stimuli. (Niemi BA 2015)

Some dogs, namely Siberian Husky and Cavalier King Charles Spaniels are over represented. Lesions are usually seen on the soft palate just caudal to the hard palate mucosa. They may have raised edges with ulcerated centres. Affected animals are often presented due to inappetence and gagging when attempting to swallow.

While occasionally classic in appearance, histopathology is always recommended to differentiate these from other oral tumours. The first step in any therapy is to rule out any possible underlying allergic cause. Flea treatment, food trial, and allergy testing should all be performed. If possible, referral to a dermatologist is recommended. If an allergic cause is discovered, treatment should be directed to removing/treating this issue. Medical therapy for idiopathic cases can include: antibiotics, corticosteroids, and cyclosporine.

MALIGNANT TUMOURS

The more caudal in the mouth the lesion is located, the poorer the prognosis. Lesions in the rostral part of the mandibles or maxilla or the rostral half of the tongue carry a much better prognosis, and excision with clear margins may be curative (Mc Entrée 2012, Dhaliwal RS 2012)

Malignant melanoma (MM) (30-40% of malignant oral tumours in dogs; rare in cats)

This is the most prevalent oral tumour in dogs (mean age 12 years). These lesions are often incidental findings during routine oral examinations, and are usually advanced at the time of diagnosis. Presentation is characterised by pigmented or unpigmented lesions that are initially smooth but later ulcerate. They are predominantly sessile. They are highly locally aggressive, generally resulting in bony reaction. Breeds with highly pigmented oral tissues appear to be over represented. (Dhaliwal RS et al 1998)

These tumours may be melanotic with variable amounts of pigment or amelanotic (lacking pigment). Special histochemical stains are often required to make a positive diagnosis for both forms of this tumour. (Ramos-Vara JA 2000) The tumour is locally invasive and spreads to the local lymph nodes (70% of cases) and lungs (66%). Therefore, the prognosis is guarded to poor, unless diagnosed and excised prior to metastasis.

The ideal treatment modality is en bloc surgical removal with 2-3 cm margins. Additional therapeutic options are radiation therapy, chemotherapy, and a melanoma vaccine. (Dhaliwal RS 2012, Bergman PJ 2007, Bergman et al 2003, Bergman 2006).

Squamous cell carcinoma (SCC) (24 - 30% of malignant oral tumours in dogs; 64-75% in cats)

This is the second most prevalent oral tumour in dogs (mean age 8 years) and the most common oral tumour in cats (mean age 12.5 years). Lesions may be tonsillar or non-tonsillar and may also affect the tongue. These lesions tend to be ulcero-proliferative and can destroy extensive areas of the jaws, disrupting teeth and occasionally result in mandibular fracture. These lesions may also be found under the tongue or on the tongue dorsum. (Dhaliwal RS 2010, Niemiec BA 2016) The osteoblastic forms result in new bone formation

The prevalence of oral SCC is greater in animals living in major cities which may be due to higher levels of air pollution. Cats which wear flea collars and/or live in smoking households are at a greater risk of oral SCC. (Bertone ER 2003)

As with all oral malignancies, wide excision (1.5-3 cm depending on reference) is the treatment of choice. Accelerated radiation protocols have been found to be beneficial (and in some cases curative) in dogs with inoperable tonsillar / pharyngeal SCC, but facilities which offer this service are uncommon (Rejec *et al* 2015, Theon 1997). In general SCC in cats does not respond to radiation therapy, however studies combining chemotherapy have shown some palliative effects. (Fidel J et al 2011, Dhaliwal RS 2010, Rejec *et al* 2015) Recent use of intratumoural injection of radioactive Holmium (¹⁶⁶Ho) microspheres shows promise for increasing effectiveness of excisional surgery (van Nimwegan *et al.* 2017). Animals suffering from acanthomatous ameloblastoma who undergo irradiation therapy are at risk of these lesions converting to squamous cell carcinomas.

Fibrosarcoma (FSA) (17-25% of oral tumours in dogs; 12-22% in cats)

Fibrosarcoma appears at a mean age of 8-9 years in dogs, and 10 years in cats. These lesions usually present as sessile lesions on the palate; smooth and slightly paler than surrounding tissue. Large breed dogs appear to be over represented (especially Golden Retrievers) and they are typically younger (4-5 years) when first diagnosed.

Although surgical excision of these tumours is the preferred treatment, regrowth is very common, even when the surgical margins were reported to be “tumour free”. Fibrosarcomas may present as histologically low grade but clinically high grade, where the oral lesion is rapidly enlarging but it appears more benign microscopically. (Ciekot PA et al 1994) Golden retrievers are highly overrepresented for this specific presentation of the tumour. These require more aggressive and quicker intervention. Ideal therapy for this tumor has not yet been determined. Different treatment modalities, including surgical excision with or without radiation therapy, radiation therapy alone, and radiation with or without localized hyperthermia, prolonged the survival times in some dogs. (Ciekot PA et al 1994)

Lymphosarcoma

Lymphomas may occur in the oral cavity and account for approximately 5% of oral tumours. These can lead to bony changes and movement of teeth. There are tonsillar and non-tonsillar types.

Epitheliotropic T-cell lymphomas (ETCL) are oral manifestations of an alimentary canal tumour and are highly resistant to treatment. ETCL lesions present as chronic gingivostomatitis with periodontitis. The lesions can extend to the muco-cutaneous junction and in some cases the lesions have a blueish tinge due to extravascular pooling of blood. (Niemiec 2015)

Osteosarcoma

Oral osteosarcomas are rare in dogs and comprise only about 2% of oral tumours in cats. (Heyman SJ et al 1992, Stebbins KE et al 1989) 7% of osteosarcoma tumours in the dog involve the skull. Lesions may cause bony destruction or bone proliferation, while some may appear to be cyst-like radiographically. Like axial osteosarcomas, these tend to metastasize late during disease and therefore may have a better prognosis for cure. (Dickerson ME et al 2001) Wide excision (2-3 cm) is generally curative, however mandibulectomy is the preferred therapy in mandibular cases. (Dhaliwal RS 2010) Radiation and chemotherapy can also be used as it is in the more common appendicular form. (Dickerson ME et al 2001)

Mast cell tumour (MCT)

Oral MCT accounts for about 6% of oral tumours, and is twice as commonly found in males than females. Lung metastases must be ruled out prior to surgical excision. Excision with 3 cm margins is recommended and therefore any reconstruction must be well planned prior to the surgery. (Macey DW 1986) A potential complication of surgery can be anaphylactic type reaction due to histamine release from mast cell degranulation. Preoperative administration of a histamine blocker (e.g., diphenhydramine [1 to 2 mg/kg SC 30 to 60 minutes before surgery]) may decrease this complication. Mast cell tumour can also be found on the tongue of cats and in

some cases the margin of the tongue may be affected, resembling plaque-responsive marginal glossitis. Excision in these cases is not indicated and they must be managed medically.

Key Points:

- The oral cavity is a very common location for tumours.
- Benign and malignant conditions can appear very similar clinically, therefore histopathology is mandatory.
- The most common oral malignant tumour in the dog is melanoma followed by SCC.
- The most common feline oral malignancy is SCC followed by fibrosarcoma.
- Prompt and aggressive therapy offers the best chance for cure and therefore regular oral exams are necessary.
- Surgical excision is the treatment of choice for most oral tumours with the margins based on the type of growth and tissue planes.
- Chemotherapy and radiation therapy may be used as palliative or adjunct means if available.
- In some cases, accelerated radiation protocols are curative.

References:

Bergmann 2006 Vaccine Volume 24, Issue 21, 22 May 2006, Pages 4582-4585

Kelly JM, Belding BA, Schaefer AK. Acanthomatous ameloblastoma in dogs treated with intralesional bleomycin. *Vet Comp Oncol.* 2010 Jun;8(2):81-6.

Niemiec BA (2016): Oral Pathology. In: *Feline Dentistry for the General Practitioner.* (Niemiec BA ed) Practical veterinary Publishing, San Diego pp 8-76.

Yoshida K, Watarai Y, Sakai Y, Yanai T, Masegi T, Iwasaki T. The effect of intralesional bleomycin on canine acanthomatous epulis. *J Am Anim Hosp Assoc.* 1998 Nov-Dec;34(6):457-61.

Chikweto A, Kumthekar S, Larkin H, et al (2013). Genital and extragenital canine transmissible venereal tumour in dogs in Grenada, West Indies *Open J Vet Med*, 3, pp. 111–114

Kabuusu RM, Stroup DF, Fernandez C. (2010) Risk factors and characteristics of canine transmissible venereal tumours in Grenada, West Indies *Vet Comp Oncol*, 8 (1), pp. 50–55.

Ganguly B, Das U, Das AK (2016). Canine transmissible venereal tumour: a review *Vet Comp Oncol*, 14, pp. 1–12

Lapa FAS, Andrade SF, Gervazoni ER, Kaneko VM, Sanches OC, Gabriel Filho LRA (2012) Histopathological and cytological analysis of transmissible venereal tumor in dogs after two treatment protocols. *Colloq Agrar*, 8 (1), pp. 36–45

Chamberlain T, Lomer M (2012) Clinical Behaviour of Odontogenic Tumors. In: Oral and maxillofacial surgery in dogs and cats. Frank JM Verstraete and Melinda J Lomer. Saunders Elsevier. pp 403-10

Chamberlain T, Verstraete FJR (2012) Clinical Behaviour and management of odontogenic cysts. In: Oral and maxillofacial surgery in dogs and cats. Frank JM Verstraete and Melinda J Lomer. Saunders Elsevier. pp 481-486.

Mc Entrée (2012) Clinical Behaviour of Non-odontogenic tumours. In: Oral and maxillofacial surgery in dogs and cats. Frank JM Verstraete and Melinda J Lomer. Saunders Elsevier. pp 387-402.

Seguin (2012) Surgical treatment of Tongue Lip and Cheek Tumors In: Oral and maxillofacial surgery in dogs and cats. Frank JM Verstraete and Melinda J Lomer. Saunders Elsevier. Pp 431-59.

Head KW, Else RW, Dubielzig RR: (2008) Tumors of the Alimentary Tract. In: Tumours in domestic animals 4th ed. Meuten DJ Ed, Iowa State Press pp 401-81

Niemiec BA (2013) Gingival Surgery. In: Veterinary Periodontology. (Niemiec BA, ed). Ames, Wiley Blackwell, 193-205.

Bonelo D, Roy C Verstraete FJR (2012) Non-neoplastic proliferative Oral Lesions In: Oral and maxillofacial surgery in dogs and cats. Frank JM Verstraete and Melinda J Lomer. Saunders Elsevier. pp 411-21

Force J, Niemiec BA (2009) Gingivectomy and gingivoplasty for gingival enlargement. J Vet Dent. 26 (2): 132 – 137, 2009.

Ramos-Vara JA, Beissenherz ME, Miller MA, et al. (2000). Retrospective study of 338 canine oral melanomas with clinical, histologic, and immunohistochemical review of 129 cases. Veterinary Pathology 37:597–608.

Bergman PJ (2007). Anticancer vaccines. Veterinary Clinics of North America Small Animal Practice 37:1111–19.

Bergman PJ, McKnight J, Novosad A, et al. (2003). Long-term survival of dogs with advanced malignant melanoma after DNA vaccination with xenogenic human tyrosinase: a phase I trial. Clinical Cancer Research 9:1284–90.

Dhaliwal RS, Kitchell BE, Marretta SM (1998). Oral tumors in dogs and cats. Part I. Prognosis and treatment. Compendium of Continuing Education 20:1011–21.

Dhaliwal RS, Kitchell BE, Marretta SM (1998). Oral tumors in dogs and cats. Part II. Prognosis and treatment. Compendium of Continuing Education 20:1109–19.

Bertone ER, Snyder LA, Moore AS. (2003) Environmental and lifestyle risk factors for oral squamous cell carcinoma in domestic cats. J Vet Intern Med. Jul-Aug;17(4):557-62.

Theon AP, Rodriguez C, Madewell BR. (1997) Analysis of prognostic factors and patterns of failure in dogs with malignant oral tumors treated with megavoltage radiation. *J Am Vet Med Assoc.* 210:778–784.

Fidel J, Lyons J, Tripp C, Houston R, Wheeler B, Ruiz A. (2011) Treatment of oral squamous cell carcinoma with accelerated radiation therapy and concomitant carboplatin in cats. *J Vet Intern Med.* May-Jun;25(3):504-10.

Ciekot PA, Powers BE, Withrow SJ, Straw RC, Ogilvie GK, LaRue SM (1994). Histologically low-grade, yet biologically high-grade fibrosarcomas of the mandible and maxilla in dogs: 25 cases (1982–1991). *Journal of the American Veterinary Medicine Association* 204:610–15.

Heyman SJ, Diefenderfer DL, Goldschmidt MH, et al. (1992). Canine axial skeletal osteosarcoma. A retrospective study of 116 cases (1986 to 1989). *Veterinary Surgery* 21:304–10.
Stebbins KE, Morse CC, Goldschmidt MH (1989). Feline oral neoplasia: a ten-year survey. *Veterinary Pathology* 26:121–8.

Dickerson ME, Page RL, LaDue TA, Hauck ML, Thrall DE, Stebbins ME, Price GS. (2001) Retrospective analysis of axial skeleton osteosarcoma in 22 large-breed dogs. *J Vet Intern Med.* Mar-Apr;15(2):120-4.

Macy DW: (1986) Canine and feline mast cell tumors: Biologic behavior, diagnosis, and therapy. *Semin Vet Med Surg Small Anim* 1:72-83.

Debowes LJ: (2010) Problems with the gingiva. In: *Small Animal dental, oral and maxillofacial disease, a color handbook* (Niemić BA ed.). London, Manson, pp159 – 181.

Niemić BA: Problems with the Pediatric Patient. In: *Small Animal dental, oral and maxillofacial disease, a color handbook* (Niemić BA ed.). London, Manson, 2010, pp159 – 181.

Welsh JS. Contagious cancer. *Oncologist.* 2011;16(1):1-4.

Das U, Das AK (2000). Review of canine transmissible venereal sarcoma. *Vet Res Commun.* 24(8):545-56.

Scarpelli KC, Valladao ML, Metze K. (2010) Predictive factors for the regression of canine transmissible venereal tumor during vincristine therapy. *Vet J.* 183:362–363.

Malocclusion in Veterinary medicine

Van Nimwegan SA, Bakker RC, Kirpensteijn J, van Es RJJ, Koole R, Lam MGEH, Jesselink JW, Nijssen JFW (2017) Intratumoral injection of radioactive holmium (¹⁶⁶Ho) microspheres for treatment of oral squamous cell carcinoma in cats.

Babbitt SG, Krakowski Volker M, Luskin IR (2016) Incidence of Radiographic Cystic Lesions Associated with Unerupted Teeth in Dogs. *J Vet Dent.*33(4):226-233.

Thrall DE. (1984) Orthovoltage radiotherapy of acanthomatous epulides in 39 dogs. J Am Vet Med Assoc. 184(7):826-9.

Theon AP, Rodriguez C, Griffey S, Madewell BR. (1997) Analysis of prognostic factors and patterns of failure in dogs with periodontal tumors treated with megavoltage irradiation. J Am Vet Med Assoc.; 210:785–788.

Thrall DE, Goldschmidt MH, Biery DN. (1981) Malignant tumor formation at the site of previously irradiated acanthomatous epulides in four dogs. J Am Vet Med Assoc. 178:127–132.

Rejec A, Benoit J, Tutt C, Crossley D, Butinar J, Hren NI(2015) Evaluation of an Accelerated Chemoradiotherapy Protocol for Oropharyngeal Squamous Cell Carcinoma in 5 Cats and 3 Dogs. J Vet Dent. 32(4):212-21.

Malocclusions

A malocclusion is any occlusion which is not standard for the breed. (Roux P 2010) It may be purely cosmetic or result in occlusal trauma. In cases of occlusal trauma there is significant pain and discomfort for the patient and if left untreated can result in significant complications such as oronasal fistulation, tooth wear and subsequent fracture and/or tooth death. In general, jaw length (or skeletal) malocclusions (Angle class II, III, IV) are considered genetic or heritable. Conversely, tooth (non-skeletal) discrepancies (class I) are considered nongenetic, with the notable exception of mesiocclusion of the maxillary canines (lance effect) seen in Shetland sheepdogs and Persian cats, which is considered genetic. (Gawor J 2013) Bellows J 2004)

Class I malocclusions, neutroclusion

This is defined as an occlusion with normal jaw lengths (scissor bite), where one or more teeth are out of alignment. These conditions are generally considered nongenetic, however, there is a high prevalence of some syndromes in certain breeds (see above) which indicates a genetic predisposition in some cases. Class I malocclusions can result from lip/cheek/tongue pressure (or lack thereof), significant systemic or endocrine issues, and less commonly neoplastic or cystic formation may also result in tooth deviation. Displacement in some situations was previously believed to result from persistence of the deciduous teeth. However, research shows that deciduous tooth persistence is caused by improper eruption of the permanent teeth. (Hobson P 2005) This class of malocclusion includes: linguoversion of the mandibular canine teeth, mesioversion of the maxillary canines (lance teeth), anterior cross bite or malalignment of the incisor teeth. (Startup S 2013, Thatcher G 2013, Martel D 2013)

Class II malocclusion, mandibular distocclusion

This is also termed overshoot or mandibular brachygnathism. In the EH Angle classification system (human) is defined as the lower molar positioned caudal to the upper molar. (Niemi BA 2010, Angle EH 1899) This is a jaw length discrepancy where the mandible is pathologically shorter than the maxilla, with the mandibular premolars caudal to the corresponding maxillary premolars. The major issue is that the mandibular canines typically cause significant occlusal trauma to the palate, gingiva, and/or maxillary canine teeth. Therefore, intervention is almost always required (Storli SH 2013).

Class III malocclusion mandibular mesiocclusion

This is also called undershot and is a jaw length discrepancy typically where the maxilla is shorter than normal. This condition is often caused by line breeding for a specific size and shape of the head. (Stockard CR 1941,) The great variety in the size and structure of the canine maxilla and mandible as well as tooth size between breeds, in combination with cross breeding have also resulted in malocclusions. Further evaluation of these findings supports the theory that malocclusions likely occur secondary to the degree to which achondroplasia is expressed within the patient. (Stockard CR 1941) Early trauma with bone scarring or physeal closure may also result in this condition; however, this diagnosis should be supported by a history of trauma. This condition, while common and “normal” in certain breeds often creates painful gingival and tooth trauma. However, as in all malocclusions, it is rare to have the patient show clinical signs. Nevertheless, therapy of the traumatic malocclusion is recommended (Yelland R 2013).

Class IV malocclusion (maxillomandibular asymmetry)

This is a jaw length discrepancy in which one of the mandibles is shorter than the other resulting in a shift of the mandibular midline. A true class IV malocclusion occurs when one mandible is longer than the maxilla and the other is pathologically shorter. An asymmetry can occur in one of three directions: rostrocaudal, dorsoventral or side to side. In general, this malocclusion causes palatine or gingival (+/- tooth) trauma and if this is occurring, therapy is recommended. (Hardy D 2013)

Therapy for Malocclusions:

Therapy for malocclusions can be classified into several categories. (Startup S 2013, Thatcher G 2013, Martel D 2013, Yelland R 2013, Storli S 2013, Moore J 2013)

1. For purely cosmetic cases no therapy is recommended. It is quite common for breeder/show clients to wish cosmetic therapy; however, this is strongly discouraged by the AVDC, AKC, and other organizations for ethical reasons. (Gawor J 2013)
2. Surgical - which generally consists of extraction of teeth causing occlusal trauma. This should be the treatment of choice for traumatic malocclusions in tier 1 & 2 countries.
3. Orthodontic: This is where the maloccluded teeth are moved into the correct or a non-traumatic position via the use of various appliances.
4. Coronal amputation and endodontic/restorative - where the offending teeth are shortened and undergo endodontic therapy (vital pulp therapy or root canal treatment) or their shape is changed by odontoplasty and a restoration/sealant placed.

The latter two are challenging techniques and should only be attempted by dental specialists (and potentially veterinarians with advanced training).

Key Points:

- Malocclusions in veterinary patients often cause trauma which can result in significant morbidity and therefore require treatment, regardless of lack of clinical signs.
- The majority of malocclusions have a genetic component, often secondary to line breeding for specific traits.
- Unless a malocclusion can be unequivocally shown to be of traumatic origin it should not be corrected by orthodontics for ethical reasons.
- There are several treatment options for traumatic malocclusions, however in most areas of the world, extraction is the most expedient.

References:

Bellows J: (2004) Orthodontic equipment, materials and techniques. In Small animal dental equipment, materials and techniques, a primer. Oxford, Blackwell. 263-96.

Gawor J (2013): Genetics and Heredity in Veterinary Orthodontics. In Veterinary Orthodontics (Niemic BA ed). Practical Veterinary Publishing, San Diego, pp 8-12.

Startup S (2013) Rotated/crowded/supernumerary teeth In Veterinary Orthodontics (Niemic BA ed). Practical Veterinary Publishing, San Diego, pp 66-72.

- Thatcher G (2013): Mesiooccluded maxillary canines (lance effect): teeth In Veterinary Orthodontics (Niemić BA ed). Practical Veterinary Publishing, San Diego, pp 73-80.
- Martel D (2013): Linguooccluded mandibular canines (Base narrow teeth In Veterinary Orthodontics (Niemić BA ed). Practical Veterinary Publishing, San Diego, pp 81-98.
- Storli SH (2013): Class II Malocclusions In Veterinary Orthodontics (Niemić BA ed). Practical Veterinary Publishing, San Diego, pp 99-109
- Yelland R (2013): Class III Malocclusions In Veterinary Orthodontics (Niemić BA ed). Practical Veterinary Publishing, San Diego, pp 110-15.
- Harvey CE, Emily PP (1993): Orthodontics, In: Small Animal Dentistry. St. Louis, Mosby. 266-96.
- Roux P, Howard J: (2010) The evaluation of dentition and occlusion in dogs. EJCAP. 20(3):241-51.
- Stockard CR, Johnson AL: (1941) The Genetic and Endocrine Basis for Differences in Form and Behavior. In: The American Anatomical Memoirs, number 19, Wistar Institute of Anatomy and Biology, Philadelphia.
- Angle EH: (1899) The Angle System of Regulation and Retention of the Teeth and Treatment of Fractures of the Maxillae. 5th ed. Philadelphia, SS White Manufacturing Co.
- Hardy D (2013): Class IV Malocclusions: In Veterinary Orthodontics (Niemić BA ed). Practical Veterinary Publishing, San Diego, pp 116-20.
- Gawor J (2013): Ethical considerations in veterinary orthodontics: In Veterinary Orthodontics (Niemić BA ed). Practical Veterinary Publishing, San Diego, pp 13-16
- Moore J (2013): Fixed and removable orthodontic appliances In Veterinary Orthodontics (Niemić BA ed). Practical Veterinary Publishing, San Diego, pp 36-47.
- Moore J (2011): Vital Pulp Therapy. In Veterinary Endodontics (Niemić BA ed). Practical veterinary Publishing, San Diego, pp 78-92.
- Hobson P (2005). Extraction of retained primary canine teeth in the dog. *Journal of Veterinary Dentistry* **22**(2):132–7.

Section 2: Animal Welfare issues concerning dental health

Introduction

At the veterinary profession's core are the five central animal welfare tenets: that animals should be cared for in ways that minimize stress, fear, suffering and pain, as well as be free to express natural behaviours (Brambell R, 1965). Additional concerns about animals' quality of life have been expressed when animals are asked to endure stimuli and physiological challenges for which they do not possess coping mechanisms (Fraser et al, 1997). Quality and regular dental care is necessary to provide optimum health and quality of life in veterinary patients. If left untreated, diseases of the oral cavity can create unrelenting pain, contribute to other serious local or systemic diseases (Niemi BA 2013, Niemi BA 2008), and prevent natural expression of oral and facial behaviours due to a lack of appropriate physiological coping mechanisms (Palmeira I *et al* 2017). Un- and undertreated dental disease has a serious impact on the welfare of the patient, and as such is an unacceptable condition for any veterinarian to leave purposefully unaddressed.

Dental disease is common

Historically, it was a commonly held belief that companion animals required little if any dental care; however, we now know that dental disease is the most common medical condition in companion animals. Over 80% of dogs and 70% of cats have evidence of periodontitis by the age of 3 (Kortegaard et al, 2008). Further, 10% of dogs have a fractured tooth with painful direct pulp exposure (termed complicated crown fractures) (Golden 1982, Chidiac 2002) and Bellows (2009) found 20-75% of mature cats are clinically affected with oral resorptive lesions, depending on the population examined. It is estimated that 50% of large breed dogs have small fractures (termed uncomplicated crown fractures) with painful dentin exposure (Hirvonen *et al.* 1992) (See oral pathology section). Therefore, the clear majority of veterinary patients are dealing with significant pain, infection, or both daily.

Dental disease causes pain and suffering

It is well documented in humans that dental pain can be extreme (Bender 2000; Hargreaves *et al.* 2004; Hasselgren 2000). Multiple published articles link dental pain to decreased productivity sleep disturbance, and significant social and psychological impacts (Reisine et al, 1989; Anil et al, 2002, Heavilin et al, 2011, Choi et al, 2015). Animals are quite stoic but their dental pain is likely equally present (Cohen AS & Brown DC 2002, Niemi BA 2005, Holmstrom SE et al 1998), given that the pain thresholds of people and animals are quite similar (Bennett et al, 1988; Rollin B, 1998). Pain is an experience unique to each individual, and behavioural demonstrations of pain, especially dental pain, may be missed by owners and veterinarians.

Nociception research is becoming less common as animal care committees at academic institutions around the world become stricter in their guidelines for responsible animal use in research settings. However, non-human mammals have been found to be excellent models for dental pain in the human world (le Bars 2001). Research into excruciating human pulpitis has found small rodents to be an excellent model. Notable and repeatable changes due to pulpal pain include decreased weight gain, increased time to complete meals, shaking, yawning, freezing and decreased activity (Chidiac 2002, Chudler *et al.* 2004) but dogs and cats have also been utilized

to show behavioural changes with pulpal and non-pulpal pain (le Bars, 2002; Rodan *et al.* 2016). Additional research is strongly recommended into better understanding oral pain and how it should best be assessed in companion animal species. However, there is substantive belief within the profession that despite not always being able to prove an animal is in pain, we should seek to relieve pain we suspect them to have at all times (WSAVA 2013)

Untreated dental disease can lead to chronic inflammation and infection of the oral tissues. As in other areas of the body, unchecked infection is an ethically unacceptable condition, once suspected, to leave without appropriate therapy.

Dental disease can alter behaviour

Behavioural scoring systems to evaluate pain exist for a variety of systems and species (Matthews *et al.*, 2015) and are described in more depth in the Anaesthesia Section. However, it is important to note that dental pain indicators are often vague and non-specific.

There are many conditions which cause pain for our patients, including, but not limited to periodontal disease, tooth and jaw fractures, tooth resorption, caries, traumatic malocclusions, feline orofacial pain syndrome, and some oral neoplasias. It is important for practitioners to understand that the absence of noting a behavioural change due to chronic dental pain does not mean that the pain is not there, nor does it imply any lack of severity. Sadly, many dogs and cats simply do NOT show the pain they are forced to endure daily in any observable way (Merola *et al.* 2016). When pain is noted behaviorally, behaviours such as pawing, mutation of the mouth, and decreased appetite appear prevalent (Rusbridge *et al.* 2015). As veterinarians, it is our absolute responsibility as veterinarians to diagnose, treat, and relieve pain and suffering for our animal patients. To allow untreated dental disease to cause continuous pain without therapy is a significant animal welfare issue. It is our duty as veterinarians to proactively diagnose these painful conditions, offer appropriate therapy, and educate our owners about the welfare issues of not treating these conditions.

Interpreting behavioural signals of oral pain can be complex, however it is a simple fact that animals will continue to eat despite debilitating and extreme dental pain. Animals require nourishment to survive, and the instinct to survive is stronger than the desire to avoid pain. It is important to remember that while the majority of animals will demonstrate normal oral behaviours, such as playing with toys, marking with facial glands, or using their mouth to explore their environment despite experiencing dental pain, others may be prevented from expressing these natural and essential behaviours due to chronic discomfort. Additionally, clients report that they are happier to know their pets are not in pain (McElhenny J, 2005). Whether or not behavior changes are observed, the underlying pain should not be a condition which the animal is expected to endure, either by the veterinary community or by owners.

While a definitive behavioural guide for assessing behavioural changes due to oral disease and discomfort is not available at this time, the authors strongly suggest this is an area that deserves further research.

Dental pain and infection cause physiological signs of stress

Infectious aetiologies such as endodontic and especially periodontal disease bring with them a significant bacterial disease burden, which the patient must cope with on a daily basis. (Niemic

BA 2013, Niemiec BA 2008) Unchecked pain and infection can lead to potentially deleterious consequences as the body's natural stress responses are activated (Broom DM, 2006). While these may be appropriate in the short term, chronic stressors negatively affect multiple body systems. Immune function impacts may be first noted with the development of an acute stress leukogram, progressing to leukopenia and immunosuppressive inflammatory cytokine changes with chronicity (Henkman et al, 2014). Several publications have linked chronic stress responses to decreased ability to eliminate bacterial infection and increased susceptibility to disease in humans and mice (Biondi et al, 1997; Karin et al, 2006; Kjank et al, 2006).

Change starts when we begin the conversation

At the practitioner level, a simple questionnaire or discussion with the owner regarding current oral and facial behaviours, and any changes that have been noted, should be performed and recorded in the patient's medical record. While anecdotally it appears that most owners and many veterinarians feel oral pain will decrease appetite (and therefore in its absence lead to misreported changes), we encourage practitioners to consider a more universal view to the wide variety of changes that may be noted as sequelae to oral disease (Table 1) (DeForge, DH)

Table 1: Possible Observable Changes Associated with Dental Pain

- Changed patterns of contact: pet with owner
- Hypersalivation
- Aggression
- Withdrawal
- Disturbances in sleep pattern
- Reduced grooming
- Changes in eating behaviour
- Change in food preference-hard to soft
- Food tossing into mouth: swallowing food whole
- Chewing on one side of mouth only
- Smacking of lips
- Mouth chattering
- Tooth grinding: especially in feline
- Tongue hanging out of mouth
- Change in play behaviour
- Blood in food or water bowl
- Bloody discharge from nose
- Rubbing face or pawing at face
- Hair loss noted around muzzle
- The feline withdrawing from cheek rubbing for affection
- Dropping food outside of the food bowl-reluctance to masticate

When taking a history from an owner, it is important for the veterinarian not to ask leading or closed ended questions, but appeal to the owner to evaluate any changes they may or may not have noticed regarding these issues. Equally important is following up on these, or any additional

changes the owner has noted since professional dental therapy has been completed. Follow-up at 2 as well as 8-10 weeks would be advised, to get a full picture of the improvements noted following therapy.

Veterinary handling techniques have welfare implications

The welfare needs of our patients begin from the time they enter our practices. Dental treatment must be conducted by properly trained veterinary professionals. Handling must be gentle and humane at all times. Low stress and feline friendly handling techniques are recommended during initial examination and introduction of anaesthetic agents, as outlined in the AAFP Guidelines (Rodan et al, 2011; Carney et al, 2012, Herron et al, 2014). The human-animal bond is tenuous, and fear experienced during handling for veterinary procedures can disrupt this bond quickly (Knesl et al, 2016). Education on, and commitment to reducing stress involved with handling for oral exams and procedures related to dental therapy needs to be considered when addressing dental disease in our patients.

All procedures in the oral cavity (including professional teeth cleaning) must be performed under general anaesthesia with a secured airway (endo- tracheal intubation). All precautions, safety measures, monitoring rules and standards apply, as referenced in the Anaesthesia section ([Hyperlink to Anaesthesia](#)).

Gentle, efficient and thoughtful tissue handling (minimally invasive surgery) is recommended to prevent excessive pain and swelling post-procedure. In addition, appropriate choice of, or avoidance of mouth gag use altogether may help to prevent trauma ([Hyperlink to Anaesthesia](#)). Local and regional anaesthetic blocks, and adequate pre- and postoperative pain management are necessary for controlling the pain that may be experienced from proper dental therapy.

Non-anaesthesia dentistry (NAD) procedures represent a major animal welfare concern

Veterinary organizations worldwide agree that dentistry without anesthesia is not medically beneficial. The person conducting the dental procedure cannot possibly evaluate the pathology, nor conduct any meaningful subgingival treatment without proper anaesthesia. This may lead to a cosmetically improved oral cavity with persistent infection, inflammation, and pain. Therefore, not only is the procedure ineffective, it often results in masking the pathology present, which delays appropriate care. This directly opposes the welfare benefits, and improvements to quality of life, that are at the centre of these guidelines. Additionally, the stress or discomfort incurred during this time consuming cosmetic procedure is wholly avoidable and indefensible from a medical and ethical standpoint. As such, the World Small Animal Veterinary Association strongly objects to the practice of veterinary dentistry without appropriate anaesthesia is inadequate, and provides a substandard level of care which may be misleading to the pet owner.

Education in dental care will increase animal welfare:

Veterinary dental care is an essential component of a preventive healthcare plan, and yet it is largely ignored in the veterinary educational system. As otherwise noted in these Guidelines more thoroughly (see Universities section), the universities role in the education and promotion of educational opportunities for not only diagnosis and therapeutic techniques for dental disease, but oral pain detection and behavioural changes associated with its pathology, must be addressed by veterinary curriculum internationally. Without educational reform and prioritization, welfare

and quality of life improvements achievable from increased quantity and quality of dental care will be impeded.

As welfare advocates, the veterinary profession needs to change their messaging regarding the need for dental care for companion animals, begin to advocate for proper dental care for our patients, and educate our clients on the importance of quality dental care to the welfare of their pets. By utilizing the five tenets of animal welfare as our guide, regular dental examination and proper therapy will help to address infection, control pain, and allow return to regular behavior. Keeping these goals central to our thought processes while recommending and performing procedures in the oral cavity is essential to the practice of humane veterinary medicine.

Key Points

- Modern animal welfare science looks to veterinarians to care for animals in ways that minimize fear, suffering, and pain, and allows them to express natural behaviours.
- Dental disease is the most common medical condition faced by companion animals, and has significant welfare implications when left undiagnosed and untreated.
- Dental disease can lead to unrelenting pain and unchecked infection, create immunological and physiological stress, cause serious local and systemic disease, and prevent natural behavioural expression.
- Behavioural changes due to oral pain can be vague and non-specific, rarely result in loss of appetite, and need to be assessed with owners both before and after dental procedures.
- Learning and promoting good handling techniques for our dental patients pre-, during, and post-therapy is important for maintaining the human-animal bond and minimizing pain and psychological suffering
- The WSAVA Dental Guidelines Committee feels strongly that practicing Anaesthesia Free Dentistry (performing dental procedures without appropriate anaesthesia or analgesia) is inadequate, and provides a substandard level care that may lead to significant welfare and quality of life issues.
- Veterinarians need to change the way they discuss dental disease and improve our advocacy for our patients, in order to help our clients understand the welfare issues of pain, infection, and disease risk their companion animals face with inadequate dental care.

References

Brambell, Roger (1965), Report of the Technical Committee to Enquire Into the Welfare of Animals Kept Under Intensive Livestock Husbandry Systems, Cmd. (Great Britain. Parliament), H.M. Stationery Office, pp. 1–84

Bender IB. (2000) Pulpal pain diagnosis: a review. *J Endod.* 26:175

Chidiac, J.-J., Rifai, K., Hawwa, N. N., Massaad, C. A., Jurjus, A. R., Jabbur, S. J. and Saadé, N. E. (2002), Nociceptive behaviour induced by dental application of irritants to rat incisors: A new model for tooth inflammatory pain. *European Journal of Pain*, 6: 55–67.

Hargreaves KM, Kaiser K. (2004) New advances in the management of endodontic pain emergencies. *J Calif Dental Assoc* 32:469

Hasselgren G (2000) Pains of dental origin. *Den Clin North Am.* 12:263

Le Bars D, Gozariu M, Cadden SW. Animal models of nociception. *Pharmacol Rev.* 2001;53(4):597–652.

Merola, I., & Mills, D. S. (2016). Behavioural Signs of Pain in Cats: An Expert Consensus. *PLoS ONE*, 11(2)

I. Palmeira, M. J. Fonseca, C. Lafont-Lecuelle, P. Pageat, A. Cozzi, P. Asproni, J. Requicha and J.T. Oliveira (2017) Pain assessment in cats with dental pathology: the accuracy of a behavioral observation-based scale. *European Congress of Veterinary Dentistry Proceedings*. Pp 87.

Rusbridge C and Heath S (2015) Feline Orofacial Pain Syndrome. In: *Feline Behavioural Health and Welfare*, Elsevier pp 213-226.

Fraser D, Weary DM, Pajor EA, Milligan BN (1997) A scientific conception of animal welfare that reflects ethical concerns. *Animal welfare* 6, 187-205

Hirvonen T, Ngassapa D, Narhi M (1992) Relation of dentin sensitivity to histological changes in dog teeth with exposed and stimulated dentin.

Bennett GJ, Xie YK. (1988), A peripheral mononeuropathy in rat that produces disorders of pain sensation like those seen in man. *Pain.* 33(1):87-107.

Rollin, BE (1998) *The Unheeded Cry: Animal Consciousness, Animal Pain, and Science*. Expanded ed. Ames: Iowa State University Press.

Broom, DM (2006) Behaviour and welfare in relation to pathology. *Applied Animal Behaviour Science*, 97 (1) Pp 73-83.

Hekman JP, Karas AZ, Sharp CR (2014). Psychogenic Stress in Hospitalized Dogs: Cross Species Comparisons, Implications for Health Care, and the Challenges of Evaluation. *Animals: An Open Access Journal from MDPI*, 4(2), 331–347.

McElhenny J (2005) Taking away the pain. *Veterinary Medicine: A Century of Change*. pp. 61-64.

Biondi, M., & Zannino, L. G. (1997). Psychological stress, neuroimmunomodulation, and susceptibility to infectious diseases in animals and man: a review. *Psychotherapy and Psychosomatics*, 66(1), 3-26.

Karin M, Lawrence T, & Nizet V (2006). Innate immunity gone awry: linking microbial infections to chronic inflammation and cancer. *Cell* 124.4: 823-835.

Kiank, C., et al. (2006) "Stress susceptibility predicts the severity of immune depression and the failure to combat bacterial infections in chronically stressed mice." *Brain, behavior, and immunity* 20.4, 359-368.

Knesl O, Hart BL, Fine AH, Cooper L (2016). Opportunities for incorporating the human-animal bond in companion animal practice. *Journal of the American Veterinary Medical Association*, 249(1), 42-44.

Rodan I, Sundahl E, Carney H, et al (2011) AAFP and ISFM Feline-Friendly handling guidelines. *J Feline Med Surg*; 13:364–375

Carney HC, Little S, Brownlee-Tomosso D, et al. (2012) AAFP and ISFM Feline-Friendly Nursing Care Guidelines. *J Feline Med Surg*. 14:337–349.

Herron ME, Shreyer T (2014) The pet-friendly veterinary practice: a guide for practitioners. *Vet Clin North Am Small Anim Pract*;44(3):451-481.

Niemiec BA (2013) Local and Regional Consequences of Periodontal Disease. In: *Veterinary Periodontology*. (Niemiec BA, ed). Ames, Wiley Blackwell, 69-80.

Niemiec BA (2013) Systemic Manifestations of Periodontal Disease. In: *Veterinary Periodontology*. (Niemiec BA, ed). Ames, Wiley Blackwell, 81-90.

Pettersson A, Mannerfelt T (2003) Prevalence of dental resorptive lesions in Swedish cats. *J Vet Dent*. 20(3):140-2.

Lund EM, Bohacek LK, Dahlke JL, et al: (1998) Prevalence and risk factors for odontoclastic resorptive lesions in cats. *J Am Vet Med Assoc*. 212(3):392-5.

Ingham KE, Gorrel C, Blackburn J, Farnsworth W (2001) Prevalence of odontoclastic resorptive lesions in a population of clinically healthy cats. *J Small Anim Pract*. 42(9):439-43.

Golden AL, Stoller NS, Harvey CE (1982) A survey of oral and dental diseases in dogs anesthetized at a veterinary hospital. *J Am Anim Hosp Assoc*. 18:891-9.

I. Palmeira, M. J. Fonseca, C. Lafont-Lecuelle, P. Pageat, A. Cozzi, P. Asproni, J. Requicha and J.T. Oliveira (2017) Pain assessment in cats with dental pathology: the accuracy of a behavioral observation-based scale. *European Congress of Veterinary Dentistry Proceedings*. Pp 87.

Niemiec BA (2008) Oral Pathology. *Top Companion Anim Med*. 23(2):59-71.

Cohen, AS, Brown DC (2002) Orofacial dental pain emergencies: endodontic diagnosis and management. In: *Pathways of the Pulp*, 8th edition (Cohen AS, Burns RC eds). St. Louis, Mosby. pp 31–76.

Niemiec BA (2005) Endodontics. In: *Vet clin N Am*. 35(4): 837-68.

Holmstrom SE, Frost P, Eisner ER (1998) Endodontics. In: *Veterinary Dental Techniques*, 2nd edn. Philadelphia, WB Saunders. pp 312-7.

Deforge DH: http://www.veterinarypracticenews.com/April-2009/Identifying-And-Treating-Oral-Pain/index.php?fb_comment_id=569809023123958_986424798129043#f37f617b61bb348

Golden AL, Stoller N, Harvey CE. (1982) A survey of oral and dental diseases in dogs anaesthetised at a veterinary hospital. *Am Anim Hosp Assoc* 18:891-9.

Section 3: Anesthesia and Pain management

Introduction

The vast majority of dogs and cats have some form of dental and/or oral disease. (Lund EM et al 1999, U of Minnesota 1996) These disorders often create significant pain and inflammation with an ultimate impact on quality of life (QoL), nutritional status and patient welfare. However, outward clinical signs of distress are not always noted, and thus most pets suffer in silence. (Niemiec BA 2012) (*see oral pathology section*)

The WSAVA Global Pain Council has published extensive guidelines on prevention, assessment and treatment of pain in companion animals. This document can be download at

http://www.wsava.org/sites/default/files/jsap_0.pdf (Matthews K et al 2014) and should be used as supplemental reading material to the WSAVA Dental Standardization, WSAVA Nutritional Assessment and the upcoming WSAVA Welfare guidelines. (Freeman L et al 2011)

Oral and maxillofacial disorders require general anesthesia for appropriate clinical and radiographic examination and treatment. Professional oral care, including dental cleanings, is generally associated with mild pain. More invasive dental procedures, such as advanced periodontal therapy, tooth extractions, root canal therapy, and oral surgeries such as mandibulectomy/maxillectomy and jaw fracture repair, are typically associated with moderate to severe pain. Proper anesthesia and effective analgesia play a crucial role in dentistry.

This section provides recommendations and suggests the *best practices* in anesthesia and pain management for canine and feline patients with oral/dental diseases. Some review articles have been published elsewhere with additional information on the subject (Woodward TM 2008, Beckman B 2013, de Vries M Putter G 2015).

Position on “anesthesia-free” or “non-anesthesia dental” (NAD) procedures

“Anesthesia-free” or NAD has been advocated by many lay people and a few veterinarians for routine preventive dentistry. The *American College of Veterinary Anesthesia and Analgesia* has published a position statement on this issue

(http://acvaa.org/docs/Anesthesia_Free_Dentistry.pdf) which is aligned with the standards of the *American Animal Hospital Association* (AAHA), the *European Veterinary Dental Society* (EVDS) and the *American Veterinary Dental College* (AVDC). In addition, the *American Veterinary Medical Association* (AVMA) position statement reported that “when procedures such as periodontal probing, intraoral radiography, dental scaling and dental extractions are justified by the oral examination, they should be performed under anesthesia”

(<https://www.avma.org/KB/Policies/Pages/AVMA-Position-on-Veterinary-Dentistry.aspx>). The *Australian Veterinary Association* published a position statement considering anesthesia-free dentistry as a matter of welfare: “Anaesthesia-free dentistry is highly likely to negatively affect the welfare of the animal and have negative psychological and behavioural consequences. It also poses a risk of injury to the operator. It is not possible to perform a professionally thorough and complete dental examination in the fully conscious animal; general anaesthesia is required in dogs and cats” (<http://www.ava.com.au/node/85991>).

The WSAVA Dental Standardization Committee strongly opposes this practice and reasons are discussed in the welfare and prophylaxis area as well as its own section. From an anaesthesia perspective, some other reasons are discussed below:

- The risks of anesthesia in healthy or even mildly compromised pets is low especially when performed by trained individuals, and avoiding anesthesia is not a valid concern.
- Sedation is not always safer than general anesthesia and veterinarians/owners are not always aware of this issue. Some sedatives that are required for chemical restraint are often contra-indicated in particular cases. Most important, cardiopulmonary monitoring may not be easily achieved during sedation.
- Oral and dental procedures may increase prevalence of aspiration of blood, saliva and debris which can occur in animals under sedation due to the fact that the airways are not protected.
- General anesthesia allows airway protection, appropriate ventilation and close monitoring of the cardiorespiratory function. Anesthetic protocols can be adjusted on a case-by-case basis.
- Analgesia is usually not provided in these cases.
- The goal is to provide great quality of care for animals and clients. “We can do better” as a profession and “anesthesia-free dentistry” is not part of this concept.

Patient preparation and assessment

Adequate handling and restraint will minimize stress and facilitate sedation. Most defensive or aggressive behavior is associated with fear and anxiety. Difficult animals should be handled with patience and gentle touch. It may be of benefit to allow cats to stay in their carrier during the preoperative period. The *American Association of Feline Practitioners* (AAFP) and the *International Society of Feline Medicine* (ISFM) have published guidelines on cat-friendly handling practices (<http://icatcare.org/sites/default/files/PDF/ffhg-english.pdf>) (Rodan I et al 2011). “Scruffing” is a controversial method of restraint and has been abandoned by many clinics.

Good anesthetic management starts with good planning. A proper pre-anesthetic examination assesses the suitability of a patient for anesthesia and provides an appreciation of risk factors. It will help in the prevention of complications and determine equipment/material requirements. The *Association of Veterinary Anaesthetists* has published a checklist for preparation of anesthesia (<http://www.ava.eu.com/information/checklists>). This includes patient identification, history, signalment, identification of concomitant diseases and medications, physical examination, risks associated with surgical procedures, fasting, risk assessment (Table 1) and equipment/material set-up/check-up. In general, the risk of anesthetic-related death in dogs and cats varies between 0.05 and 0.3%. (Brodbelt DC et al 2007, Brodbelt DC et al 2008, Matthews NS et al 2017) Morbidity and mortality are greater in patients with poor anesthetic risk assessment (ASA \geq III) demonstrating the importance of pre-anesthetic assessment and health status classification. If possible, canine and feline individuals with co-existing disease should be stabilized before general administration with the administration of fluids and correction of electrolyte and acid-base disturbances.

Serum chemistry and hematology, and additional imaging examination are recommended when abnormalities are identified from the history and physical examination and in patients with co-existing diseases. This may also represent an unique chance for the patient to get a “work-up” and a close investigation into its general health. However, results of a serum chemistry and

hematology will rarely impact anesthetic protocol and blood sampling can be a significant source of stress for some patients. (Alef M et al 2008)

The issue of mouth gags in cats undergoing general anesthesia for oral procedures

Mouth gags have been reported as a risk factor during anesthesia in cats and as a cause of temporary and permanent post-anesthetic blindness following oral procedures (de Miguel Garcia C et al 2013, Stiles J et al 2012) Mouth gags apply a continuous force against the teeth of the maxilla and mandible which may compress the maxillary artery which provides blood flow/oxygenation to the retina and brain in cats. Excessive opening of the mouth narrows the distance between the medial aspect of the angular process of the mandible and the rostrolateral border of the tympanic bulla; the maxillary artery courses between these two osseous structures (Martin-Flores M et al 2014, Scrivani PV et al 2014, Barton-Lamb AI et al 2013) This is particularly true with spring-loaded mouth gags, therefore these should not be used. Alternative methods such as properly sized plastic (e.g. cut syringe barrels) may be considered, however their use should be minimized, and must be released/removed periodically.

Anesthetic management

Anesthetic protocols should be tailored to the patient needs based on individual requirements, risk assessment, co-existing disease and drug availability. The goal of premedication is to produce anxiolysis, pain relief, and muscle relaxation while decreasing anesthetic requirements and providing smooth anesthetic induction and recovery. In addition, it can decrease the endocrine stress response to surgery and facilitate intravenous catheterization.

Neuroleptanalgesia is the combination of a sedative/neuroleptic with an opioid and it aims to decrease doses and adverse effects of both classes of drugs while maximizing their beneficial effects. Protocols for sedation and premedication commonly include a combination of an opioid with either acepromazine, dexmedetomidine or a benzodiazepine (ex. diazepam or midazolam), however the administration of an opioid alone, or in combination with a benzodiazepine is often used in ASA III or IV patients with co-existing disease. Suggested indications, advantages and disadvantages of drugs used for sedation and premedication are described in Table 2.

Anesthetic induction can be accomplished via administration of propofol, alfaxalone, thiopental, etomidate or a combination of ketamine/diazepam. Each anesthetic has its own advantages and disadvantages (Table 3) and drugs should be given “to effect” to minimize cardiorespiratory depression.

Volatile anesthetics (e.g. isoflurane and sevoflurane) are the preferred method for anesthetic maintenance. However, high concentrations of volatile anesthetics can produce peripheral vasodilation, reduce myocardial contractility and cardiac output which debilitated patients may not tolerate. Hypotension can be best avoided with reduced anesthetic concentrations by using balanced anesthesia; drugs that decrease volatile anesthetic requirements and provide good hemodynamic stability and analgesia (ex. opioid infusions or boluses). This is especially important in cases where geriatric or compromised patients are involved. This population has decreased physiological reserves and anesthetic drugs commonly produce a significant impact in

body systems which could have dramatic consequences. Eyes should be lubricated on at least an hourly basis since tear production is reduced during sedation and general anesthesia.

Limited drug availability

Volatile anesthesia is not always available and opioids may be under strict regulation and control to veterinarians in many countries.

- Optimal anesthetic/oral care is still possible with the use of injectable anesthetic protocols (e.g. xylazine, ketamine and diazepam combinations, and protocols involving tiletamine-zolazepam, etc.).
- General anesthesia requires endotracheal intubation.
- Ideally, the administration of fluid therapy/oxygen and adequate monitoring of anesthesia and body temperature should be performed.
- Local anesthetic blocks are widely available and imperative in perioperative pain management (see below).
- NSAIDs are also readily available and play an important role in controlling postoperative pain and inflammation when other modalities are unavailable.
- Injectable tramadol is available in many countries in South America and Europe and can be an effective alternative if opioids are not available.

Intubation

Endotracheal intubation is mandatory for dental procedures even if there is limited availability of drugs and lack of volatile anesthesia.

- Cuffed endotracheal tubes are used for intubation, provide airway protection and means of assisted ventilation. This is particularly important in oral procedures due to the increased risk of aspiration of contents.
- Oropharyngeal packing is recommended (see section on prophylaxis).
- Endotracheal intubation is required during general anesthesia and veterinarians should avoid cuff overinflation, particularly in cats, since it may cause tracheal damage/necrosis especially during patient movement (Mitchell SL et al 2000).
- Patients should be always disconnected from the breathing circuit when rolled from one side to the other.

Fluid therapy

Venous access should be established in all patients as part of best quality care, ideally using an intravenous catheter. It allows the administration of fluids, emergency drugs, antibiotics, analgesics and anesthetics during the perioperative period.

- Fluid therapy compensates for ongoing losses, prevents and treats dehydration and hypovolemia, and provides a source of electrolytes.
- Most anesthetic drugs will cause some level of cardiovascular depression and the administration of balanced crystalloid solution will optimize hydration status and tissue perfusion during anesthesia.
- The choice will be based on patient's needs and requirements. In general, it is accepted that lower (2-3 mL/kg/hour) than surgical crystalloid rates (5 mL/kg/hour) are used in anesthetized patients undergoing oral surgery since there is less insensible fluid loss.
- Fluid overload is a risk in dogs and cats especially considering that these procedures could be long in duration and may *not* be of invasive nature. Higher fluid rates may be

administered, if deemed necessary and in cases of hypovolemia without concomitant cardiac disease.

- Patients with advanced renal disease may benefit from preoperative fluid administration to establish proper hydration.

Monitoring

Anesthetic monitoring is significantly correlated with decreased morbidity and mortality. Veterinarians should not blame “anesthesia” itself for accidental deaths in the perioperative period since most anesthetic deaths occur when dogs and cats are not being closely monitored or often due to human errors. Simple peripheral pulse palpation and pulse oximetry can significantly decrease risk of anesthetic-related death by 80% in cats. (Brodbeck et al 2007).

- Pulse oximetry can be a challenge to monitor during anesthesia for oral procedures since the probe can be easily displaced, however it can be placed over the ears and paws.
- Mean blood pressure monitoring should be maintained above 70 mmHg for appropriate tissue perfusion. This is particularly important in dogs and cats with chronic kidney disease. Doppler ultrasound can be used to measure systolic blood pressure.
- Respiration should be ideally monitored using a capnograph since monitoring of respiratory rate does not provide information of the “quality of the respiratory function” (amplitude, gas exchange, metabolism, disconnection from anesthetic breathing system, etc.).
- Body temperature should be maintained between 37 and 38°C (98.6 - 100.4°F). It should be monitored in all circumstances (Stepaniuk K Brock N 2008). Prevention of hypothermia can be accomplished by avoiding contact with cold surfaces, the use of heating pads, active heating devices and blankets, and working in a warm environment. Bubble plastic wrap around the extremities can be also used for prevention of hypothermia. This material is cheap and available world-wide.

Equipment

Anesthetic equipment including anesthetic machine, breathing systems and endotracheal tubes should be tested before general anesthesia. They should be clean, in good working condition and undergo routine maintenance.

Dogs and cats at high risk of anesthetic-related death (i.e. ASA III or higher) ideally should be referred to a veterinarian with advanced training in veterinary anesthesia where available (e.g. some countries have board-certified veterinarians who underwent strict training by the American or European College of Veterinary Anesthesia and Analgesia).

Pain Management

General considerations

Pain management is not only important from the ethical and welfare point of view but also as a therapeutic strategy to re-establish organ function, accelerate hospital discharge and minimize financial costs. The International Association for the Study of Pain (IASP) has published a curriculum outline on pain for human dentistry based on entry level (<http://www.iasp-pain.org/Education/CurriculumDetail.aspx?ItemNumber=763>). A similar outline could be

adapted and applied in veterinary medicine for teaching veterinary students. In veterinary dentistry, clinicians should apply validated methods of pain assessment and treat orofacial pain based on available literature and scientific evidence, when appropriate. Principles of pain management for oral and maxillofacial disorders are presented below:

- Pain is considered to be the 4th vital assessment and its assessment and treatment should be part of every patient's "work-up". An analgesic plan should be in place during the perioperative period and for several days to a week after hospital discharge.
- Analgesic protocols should be created on a case-by-case basis and dosage regimens adjusted accordingly. Dental patients present with various levels of pain and a safe and effective approach can be challenging.
- Pain management is always best addressed using a preventive and multimodal analgesic approach and may be even more important in patients with oral disease as they often do not show obvious signs of pain (Box 1).
- The "basic" analgesic protocol includes the administration of opioids, local anesthetic blocks and nonsteroidal anti-inflammatory (NSAIDs) drugs unless contra-indicated (see Mathews et al. 2014 for drugs, doses and indications).
- The pros and cons of each class of analgesic should be taken in consideration.
- The administration of adjuvant analgesics is recommended in cases of moderate and severe pain, and for patient discharge. Hospitalization is recommended for invasive surgical procedures where patient requires frequent assessment and treatment with opioid and ketamine infusions, for example.

BOX 1 :

Preventive analgesia describes all types of perioperative interventions and efforts to address and minimize postoperative pain. Administration of analgesics is performed at any time and for varying duration in the perioperative period to prevent allodynia and central sensitization. *Multimodal analgesia* is the administration of two or more analgesic drugs with different mechanisms of action. These drug combinations should present substantial synergism which allows the use of lower doses of each class of analgesics with minimal adverse effects.

Pain assessment

Pain assessment in dogs and cats represent a challenge for the veterinarian since specific instruments/tools for the evaluation of pain in patients with oral disease have not been published. An instrument is currently under investigation and it is generally accepted that these animals have pain in the majority of cases especially those where a chronic infection or trauma exists. (Della et al 2016) Oral disease and associated pain is a welfare issue since it impacts quality of life and nutritional status (Box 2). Dental disease has been associated with pain in cats in a recent study (Palmeira et al 2017).

Box 2 - For example, it is not uncommon to observe increased body weight and activity, and better sleeping patterns/quality of life after treatment of oral disease. Some animals become friendlier after the procedure than before indicating a potential emotional and affective component of pain and inflammation. Analgesic management reduces pain and suffering and has a welfare benefit (see section of welfare).

In general, pain associated with oral disease may create specific and/or nonspecific clinical signs which will improve after oral treatment. Signs of dental pain include ptyalism, halitosis, decreased appetite, rubbing or pawing the face, changes in demeanor and reluctance to play with toys. Pain recognition and assessment can be performed using the Glasgow pain scoring tools for dogs (Reid j et al 2007) and cats (Reid et al 2017). These instruments have not been specifically validated for patients with oral disease but they provide an idea of the “overall” picture and can be used for any medical/surgical condition.

Perioperative pain control

Opioids are the first line of treatment in acute pain management and they have been reviewed in detail elsewhere. (Simon BT Steagall PV 2016, Bortolami E, Love EJ 2015)

- They produce varying levels of sedation (depending on the drug and patient’s health status), reduce anesthetic requirements in a dose-dependent manner (dogs) and have the benefit of reversibility.
- Different opioids have variable effects based on their receptor affinity, efficacy, potency and individual responses.
- This discussion is beyond the scope of the guidelines, however most full opioid agonists (e.g. morphine, hydromorphone, methadone, fentanyl, remifentanyl) will provide dose-dependent analgesia, increase vagal tone inducing bradycardia without changes in systemic vascular resistance or myocardial contractility, offering hemodynamic stability.
- Buprenorphine is a partial agonist of μ -opioid receptors and its use has been reviewed in cats. (Steagall PV et al 2014) Both buprenorphine and methadone can be administered via the buccal route and provide significant analgesic effects in this species. This is of interest in dental patients, however there might be liability issues of prescribing these medications to be administered by owners. It is also not known how inflammation will affect buccal pH and opioids’ absorption and analgesic efficacy.

Most oral and maxillofacial disorders and therapies involve inflammation and tissue damage/trauma. The administration of NSAIDs is strongly recommended in these cases and veterinarians should be aware of their approved dosage regimens in their countries.

- Unless contraindicated, NSAID therapy is commonly administered for approximately 3-7 days depending on type of oral disease/procedure.
- NSAIDs may also be administered to cats for several days. This may be particularly important after significant oral surgery, such as full-mouth extractions due to feline chronic gingivostomatitis. Some NSAIDs are licensed for daily long-term administration in cats in Europe and they could be an option for these patients.
- Maxillofacial trauma, and invasive and complex procedures (e.g. maxillectomy and mandibulectomy) can produce excruciating pain; they are commonly addressed with balanced anesthesia/multimodal analgesia (systemic administration of analgesic infusions such as opioids, lidocaine and ketamine) during early postoperative period (24-48 hours) in combination with NSAIDs.
- Analgesic infusions are important especially when oral administration of analgesics is not an option due to severe trauma or trismus (masticatory muscle myositis), among others.
- Analgesic prescription for “take-home” is an important part of pain management.
- NSAIDs are ideally combined with oral adjuvant analgesics such as tramadol, amitriptyline, gabapentin and/or amantadine.

Local anesthetic techniques of the oral cavity

Local anesthetic drugs produce a reversible block of sodium and potassium channels and transmission of nociceptive input. Local anesthetic techniques provide perioperative (and immediate postoperative) analgesia and reduce volatile anesthetic requirements in a cost-effective manner (Snyder CJ Snyder LB 2013, Aguiar J et al 2015, Gross ME et al 1997, Gross ME 2000). Further, they blunt the initial surgical trauma, decreasing recovery times. These blocks require minimal training and can be used for a variety of dental procedures including extractions or surgery of the oral cavity such as maxillectomy, mandibulectomy, among others. Some considerations are presented below:

- Unfortunately, local anesthetic techniques are not widely employed in veterinary medicine due to the lack of familiarity with use. The WSAVA Dental Standardization committee strongly supports the use of these techniques in perioperative pain control especially in scenarios with limited analgesic availability.
- These drugs are readily available and should be incorporated in the anesthetic management of patients with oral and maxillofacial disorders.
- It is important to note that techniques used in dogs cannot be directly extrapolated to cats due to anatomical differences between species.
- Descriptions and diagrams depicting various loco-regional anesthetic techniques have been described in the WSAVA Guidelines on the recognition, assessment and management of pain (Mathews K et al 2014).
- These techniques can be watched on the YouTube channel of the Faculty of Veterinary Medicine, Université de Montréal (links are provided below).

Materials:

Loco-regional anesthetic techniques of the oral cavity require simple and low-cost materials such as disposable 1 mL syringes, 25-mm to 30-mm 27-G or 25-G needles. Larger needles should be avoided as they may cause nerve and vascular damage while smaller needles may produce excessive pressure at injection and result in local tissue damage.

Drugs

Table 4 shows common doses and concentrations of local anesthetics (Table 4).

Levobupivacaine or bupivacaine may be preferred over lidocaine for local anesthetic techniques of the oral cavity due to its prolonged duration of action. However self-mutilation has been anecdotally reported if the oral cavity and particularly the tongue are still anesthetized hours after the end of procedure/after extubation. Anesthesia of the lingual and mylohyoid nerves may occur during a mandibular nerve block and result in desensitization of the rostral two-thirds of the tongue. The idea is to have excellent intraoperative and early postoperative analgesia with local anesthetics whereas postoperative pain relief is achieved with the administration of opioids, NSAIDs and adjuvant analgesics. Some veterinarians combine opioids such as buprenorphine (0.003-0.005 mg/kg) with local anesthetics for blocks of the oral cavity. In humans the administration of buprenorphine enhances and prolongs the effects of bupivacaine after minor oral surgery (Modi M et al 2009). In dogs, bupivacaine alone or in combination with buprenorphine reduced isoflurane requirements by approximately 20%. The addition of buprenorphine did not extend the duration of nerve blockade but it produced long-term isoflurane-sparing effect in some individuals (Snyder LB et al 2016).

Mixing local anesthetics

Historically, lidocaine 2% and bupivacaine 0.5% have been mixed together to decrease the onset of action of bupivacaine while increasing the duration of action of lidocaine. However these drugs have different pKa, % protein binding and there is little evidence that this combination is better than bupivacaine alone. The results may be unpredictable and the duration of action actually decreased. (Shama T et al 2002)

Volumes

A small amount of local anesthetic is required for these techniques. In general, volumes vary between 0.1- 0.2 mL in cats to 0.2 to 1 mL in dogs of lidocaine or bupivacaine as long as toxic doses are calculated taking account all dental blocks required (see below). The oral cavity is widely innervated by branches of multiple cranial nerves and it is not uncommon that a block will fail (Krug W Losey J 2011). Veterinarians should use a combination of techniques which can be repeated if toxic doses (see complications below) are respected, however other analgesic techniques should always be considered. Intraosseous or intraligamentary anesthesia might be an option when other techniques have failed, however these blocks do produce intrinsic pain at injection.

Avoiding complications

There are some important considerations before the administration of any local anesthetic block to avoid complications

- Calculation of toxic doses - Local anesthetic toxicity may occur when dosage regimens and intervals of administration are not properly calculated.
- In dogs and cats, it is well accepted that doses higher than 10 mg/kg (dogs) and 5 mg/kg (cats) of lidocaine, and 2 mg/kg of bupivacaine (both species) might induce clinical signs of toxicity such as seizures, cardiorespiratory depression, coma and death. (Chadwick 1985, Feldman et al 1989, Feldman et al 1991, Woodward TM 2008)
- The administration of lidocaine spray for endotracheal intubation in cats should be taken in consideration for dose calculations.
- Negative aspiration of blood - Veterinarians should always check for negative aspiration of blood to avoid accidental intravenous administration before drug administration especially when administering bupivacaine due to its cardiotoxic profile (Aprea F et al 2011). If bupivacaine is administered intravenously, dysrhythmias such as ventricular premature contractions may be observed.
- Intravenous administration is not an issue with lidocaine, however block may not be effective and hematoma/bleeding may occur. (Loughran CM et al 2016) Hematoma is best avoided using digital pressure after the administration of the local anesthetic for 30-60 seconds.
- Resistance to injection – A local block should not be performed if resistance to injection is encountered since this could indicate nerve needle penetration and risk of nerve damage. The needle should be withdrawn or readjusted in this case.

Complications after local anesthetic blocks of the oral cavity are rare but have been reported and include globe penetration most often requiring enucleation (Perry R et al 2015). Orbital penetration may also be caused by dental extractions and therefore may not be associated with the administration of anesthetics (Smith MM et al 2003, Guerreiro CE et al 2014)). Veterinarians should not be afraid to use these techniques; however these techniques should be used with cautious using appropriate landmarks. Local blocks should be avoided in the presence of abscesses or neoplasia due to the risk of dissemination of infection or neoplastic cells, respectively.

Inflammation and failure of local anesthetic block

Local anesthetics have a pKa between 7.5 and 9 and are formulated as acid solutions of hydrochloride salts (pH 3.5 – 5.0). This formulation gives a net prevalence of the ionized form and is thus water soluble. When a local anesthetic solution is injected into body tissues with a physiological pH (7.4), the non-ionized lipid-soluble form will prevail. This is critical for the drug effect since the non-ionized form crosses biological membranes. In inflamed tissues, the ionized form prevails, explaining why local anesthetics may be ineffective under such conditions (acidic pH and inflammation). Administration of a local anesthetic block should be performed in non-inflamed areas to improve efficacy. For example, an inferior alveolar nerve block should produce anesthesia of distal inflamed teeth because the block is performed proximally (distant) to the area of inflammation.

Specific techniques

1) Inferior alveolar nerve block (<https://www.youtube.com/watch?v=2q8ndh5Bn6U>)

Anesthesia of sensory and motor innervations of the mandible including teeth, lower lip, part of the tongue, hard and soft tissues. This foramen may be difficult to palpate in cats but the block can be still performed successfully. Cats do not have the concavity of the ventral margin of the body of the mandible which can be easily located in dogs.

2) Palatine nerve block (<https://www.youtube.com/watch?v=-xsDqqGRrjI>)

Anesthesia of palatine nerves and palate.

3) Infraorbital nerve block (<https://www.youtube.com/watch?v=H3L1LHBcM-g>)

Anesthesia of the skin and soft tissues inside the oral cavity, dorsal part of nasal cavity, maxillary bone rostral to the infraorbital foramen and incisive teeth. For desensitization of ipsilateral canine tooth, a maxillary nerve block is preferred and produces more consistent blockade. Caution must be taken with this block, as the infraorbital foramen is located just ventral to the orbit. A bony ridge can be easily palpated in cats. The infraorbital canal is much shorter in cats and brachycephalic dogs than in normo- and dolichocephalic dogs. It is only a few millimeters in length. To avoid eye penetration, the needle should be introduced ventrally and advanced only approximately 2 mm.

4) Middle mental nerve block (<https://www.youtube.com/watch?v=r9j06VVGvMw>)

Anesthesia of the rostral lower lip and mandibular aspect, including ipsilateral incisor\ teeth. In cats and small breed dogs, the foramen is small and it should not be penetrated to avoid nerve damage.

5) Maxillary nerve block (<https://www.youtube.com/watch?v=1AYNmsyzCv0>)

Anesthesia of the ipsilateral maxilla, teeth, palate, and the skin of the nose, cheek and upper lip. Another approach for the maxillary nerve has been described. Using an infraorbital approach, the tip of a catheter (without stylet) is advanced until the point where imaginary lines parallel to the infraorbital canal and its perpendicular drawn to the lateral canthus transect (reference). The upper lip is elevated and the infraorbital foramen is located (approximately dorsal to the third premolar tooth). The catheter is introduced approximately 2-4 mm into the foramen and the size of the catheter is selected by veterinarian in advance.

Tables:

Table 1 - ASA Physical Status Classification System (with permission). (ASA House of delegates, 2014)

ASA Classification*	Definition
ASA I	A normal healthy patient
ASA II	A patient with mild systemic disease
ASA III	A patient with severe systemic disease
ASA IV	A patient with severe systemic disease that is a constant threat to life
ASA V	A moribund patient who is not expected to survive without the operation

*Each classification is further subdivided with the inclusion of an “E” to represent an emergency surgery, where delay may affect outcome

Table 2 – Drugs used for sedation, premedication and chemical restraint in dogs and cats*

Drug	Dosage regimens**	Comments
Acepromazine	0.01-0.05 mg/kg IM, IV, SC	Mild sedation in cats Higher doses will not necessarily increase magnitude of effects; however duration of action may be increased
Diazepam†	0.2-0.5 mg/kg IV	Poor absorption after IM administration. Commonly used in combination with ketamine or propofol for anesthetic induction
Midazolam†	0.2-0.5 mg/kg IM or IV	Commonly used in combination with ketamine or propofol for anesthetic induction
Xylazine	0.2-0.5 mg/kg IM, IV	Sedation when (dex) medetomidine not available Vomiting and nausea are commonly produced
Dexmedetomidine	1-10 µg/kg IM, IV 10-20 µg/kg (OTM) (cats)	Lower doses are used for sedation and neuroleptanalgesia while high doses are administered for anesthesia in combination with ketamine and opioid (“doggy” or “kitty magic”) when volatile anesthesia is not available Higher doses may be required for chemical restraint of feral dogs and cats
Medetomidine	6-20 µg/kg IM, IV	See dexmedetomidine Half-potency of dexmedetomidine (doses are doubled) Buccal administration produces excessive salivation in cats
Ketamine	3-10 mg/kg IM or PO	Ketamine may be exceptionally used for sedation/chemical restraint in cats when combined with midazolam and an opioid Oral administration is used for feral cats
Alfaxalone	0.5-1 mg/kg IM	Alfaxalone may be exceptionally used for sedation in cats when combined with midazolam and an opioid

*Lower doses should be given when the intravenous route is chosen.

**Use in dentistry

† Paradoxal sedation is commonly observed after the administration of benzodiazepines in young, healthy patients.

Table 3 – Drugs used for anesthetic induction and injectable anesthesia†

† Specific information on these anesthetic agents should be found in appropriate text books

Drug	Dosage regimens	Comments
Alfaxalone*	0.5-3 mg/kg IV Up to 3-5 mg/kg (unpremedicated patients) IV	Doses are given to effect Cardiorespiratory depression can be observed Recoveries can be agitated (see drug's label)
Propofol*	0.5-4 mg/kg IV	Higher doses (6-8 mg/kg) may be required in cats Caution in hypovolemia and patients with cardiopulmonary disease Some formulations have preservatives which promote long shelf-life Anesthetic choice in nephropathies and hepatopathies
Ketamine*	2-5 mg/kg (induction) IV 2-20 µg/kg/min (infusion in balanced anesthesia) IV	Commonly used in combination with diazepam or midazolam for anesthetic induction Should never be administered alone Anti-hyperalgesic effects via N-methyl D-aspartate (NMDA) receptor antagonism Good cardiopulmonary stability Potential difficult anesthetic recoveries
Thiopental*	2.5-5 mg/kg IV	Used when other agents are not available Cardiopulmonary depression Drug accumulation (e.g. hypothermia, hepatopathy, nephropathy) may lead to prolonged anesthetic recovery Strictly given IV (otherwise risk of phlebitis and severe skin necrosis)
Tiletamine-zolazepam*	1-2 mg/kg IV	Option when volatile anesthesia is not available Analgesics should be administered for pain control Potential prolonged and rough recoveries Similar pharmacological profile to ketamine

*Doses are given to effect. The level of sedation should be assessed before induction of anesthesia to determine best dosage regimens of each agent. These drugs have all their unique advantages and disadvantages

Table 4 – Common local anesthetics used in veterinary anesthesia and pain management

Local Anesthetic*	Onset (min)	Common concentrations (%)	Duration of the block (h)	Relative potency (lidocaine = 1)	Suggested maximum doses (mg/kg)
Lidocaine	5 - 15	1, 2	1 - 2	1	10 (dogs) 5 (cats)
Mepivacaine	5 - 15	1, 2	1.5 – 2.5	1	4 (dogs) 2 (cats)
Bupivacaine	10 - 20	0.25, 0.5, 0.75	4 - 6	4	4 (dogs) 2 (cats)
Ropivacaine	10 - 20	0.5, 0.75	3 - 5	3	3 (dogs) 1.5 (cats)
Levobupivacaine	10 - 20	0.5, 0.75	4 - 6	4	2 (dogs) 1 (cats)

*Volumes of injection (0.25 – 1 mL) vary according to the size and patient’s anatomy and body weight. Anesthetic blocks can be repeated according to the duration of procedure, interest of postoperative analgesia and using less than maximum recommended doses (see text).

References

Lund EM, Armstrong PJ, et al (1999): Health status and population characteristics of dogs and cats examined at private veterinary practices in the United States. *J Am Vet Med Assoc.* 214, 1336-41.

National Companion Animal Study (1996) : University of Minnesota Center for companion animal health. Uplinks: pp 3.

Niemiec BA (2012) How to address and stabilize dental emergencies. In: *Veterinary Dentistry Applications in Emergency Medicine and Critical or Compromised Patients.* San Diego, Practical Veterinary Publishing. pp 1-32.

Mathews K, Kronen PW, Lascelles D, et al (2014) Guidelines for recognition, assessment and treatment of pain: WSAVA Global Pain Council members and co-authors of this document. *J Small Anim Pract.* 55(6):E10-68.

Freeman L, Becvarova I, Cave N, et al (2011) WSAVA Nutritional Assessment Guidelines. *J Small Anim Pract.* 52(7):385-96.

Woodward TM (2008) Pain management and regional anesthesia for the dental patient. *Top Companion Anim Med.* 23(2):106-14.

Beckman B (2013) Anesthesia and pain management for small animals. *Vet Clin North Am Small Anim Pract.* 43(3):669-88.

de Vries M, Putter G (2015) Perioperative anaesthetic care of the cat undergoing dental and oral procedures: key considerations. *Journal of Feline Medicine and Surgery* 17, 23-36.

Rodan I, Sundahl E, Carney H *et al* (2011) AAEP and ISFM Feline-friendly handling guidelines. *Journal of Feline Medicine and Surgery*. 13, 364-375.

Reid, J; Nolan, AM; Hughes, JML, *et al* (2007). Development of the short-form Glasgow Composite Measure Pain Scale (CMPS-SF) and derivation of an analgesic intervention score. *Animal Welfare*, Volume 16, Supplement 1, pp. 97-104(8)

Brodbelt, D.C, Blissitt, K.J., Hammond, R.A., *et al.* (2008) The risk of death: the confidential enquiry into perioperative small animal fatalities. *Veterinary Anaesthesia and Analgesia*. 35, 365-373.

Brodbelt DC, Pfeiffer DU, Young LE *et al.* (2007) Risk factors for anaesthetic-related death in cats: results from the confidential enquiry into perioperative small animal fatalities (CEPSAF). *British Journal of Anaesthesia*. 99, 617–623.

Matthews NS, Mohn TJ, Yang M, *et al* (2017) Factors associated with anesthetic-related death in dogs and cats in primary care veterinary hospitals. *J Am Vet Med Assoc*. ;250(6):655-665.

Alef M, von Praun F, Oechtering G (2008) Is routine pre-anaesthetic haematological and biochemical screening justified in dogs? *Vet Anaesth Analg*. 35(2):132-40.

de Miguel Garcia C, Whiting M, Alibhai H (2013): Cerebral hypoxia in a cat following pharyngoscopy involving use of a mouth gag. *Vet Anaesth Analg*.;40(1):106-8.

Stiles J, Weil AB, Packer RA, Lantz GC.(2012): Post-anesthetic cortical blindness in cats: twenty cases. *Vet J*.;193(2):367-73.

Martin-Flores M, Scrivani PV, Loew E, Gleed CA, Ludders JW.(2014) Maximal and submaximal mouth opening with mouth gags in cats: implications for maxillary artery blood flow. *Vet J*.;200(1):60-4.

Scrivani PV, Martin-Flores M, van Hatten R, Bezuidenhout AJ. (2014)Structural and functional changes relevant to maxillary arterial flow observed during computed tomography and nonselective digital subtraction angiography in cats with the mouth closed and opened.*Vet Radiol Ultrasound*. 55(3):263-71.

Barton-Lamb AL, Martin-Flores M, Scrivani PV, *et al* (2013) Evaluation of maxillary arterial blood flow in anesthetized cats with the mouth closed and open. *Vet J*. 196(3):325-31.

Mitchell SL, McCarthy R, Rudloff E, *et al.* (2000) Tracheal rupture associated with intubation in cats: 20 cases (1996–1998). *J Am Vet Med Assoc* 216: 1592–1595.

Stepaniuk K, Brock N (2008) Hypothermia and thermoregulation during anesthesia for the dental and oral surgery patient. *J Vet Dent*. 25(4):279-83.

Della RG, Di Salvo A, Marenzoni ML et al. Development and initial validation of a pain scale for the evaluation of odontostomatologic pain in dogs and cats: preliminary study. Proceeding of the Association of Veterinary Anaesthetists Meeting, 20-22nd April 2016, Lyon, France.

Reid et al (2017) Definitive Glasgow acute pain scale for cats: validation and intervention level. *Vet Rec* 180:449.

Simon BT, Steagall PV (2016) The present and future of opioid analgesics in small animal practice. *J Vet Pharmacol Ther.* (in press) doi: 10.1111/jvp.12377.

Bortolami E, Love EJ. (2015) Practical use of opioids in cats: a state-of-the-art, evidence-based review. *J Feline Med Surg.* 17(4):283-311.

Steagall PV, Monteiro-Steagall BP, Taylor PM. (2014) A review of the studies using buprenorphine in cats. *J Vet Intern Med.* ;28(3):762-70

Snyder CJ, Snyder LB (2013) Effect of mepivacaine in an infraorbital nerve block on minimum alveolar concentration of isoflurane in clinically normal anesthetized dogs undergoing a modified form of dental dolorimetry. *J Am Vet Med Assoc.* 15;242(2):199-204.

Aguiar J, Chebroux A, Martinez-Taboada F, Leece EA. (2015) Analgesic effects of maxillary and inferior alveolar nerve blocks in cats undergoing dental extractions. *J Feline Med Surg.* 17(2):110-6.

Gross ME, Pope ER, O'Brien D, Dodam JR, Polkow-Haight J (1997) Regional anesthesia of the infraorbital and inferior alveolar nerves during noninvasive tooth pulp stimulation in halothane-anesthetized dogs. *J Am Vet Med Assoc.* 211(11):1403-5.

Gross ME¹, Pope ER, Jarboe JM: (2000) Regional anesthesia of the infraorbital and inferior alveolar nerves during noninvasive tooth pulp stimulation in halothane-anesthetized cats. *Am J Vet Res.* 61(10):1245-7.

Modi M, Rastogi S, Kumar A. (2009) Buprenorphine with bupivacaine for intraoral nerve blocks to provide postoperative analgesia in outpatients after minor oral surgery. *J Oral Maxillofac Surg.* 67(12):2571-6.

I. Palmeira, M. J. Fonseca, C. Lafont-Lecuelle, P. Pageat, A. Cozzi, P. Asproni, J. Requicha and J.T. Oliveira (2017) Pain assessment in cats with dental pathology: the accuracy of a behavioral observation-based scale. *European Congress of Veterinary Dentistry Proceedings.* Pp 87.

Chadwick HS (1985) Toxicity and resuscitation in lidocaine- or bupivacaine-infused cats. *Anesthesiology* 1985; 63:385-390.

Feldman HS, Arthur GR, Covino BG (1989) Comparative systemic toxicity of convulsant and supraconvulsant doses of intravenous ropivacaine, bupivacaine, and lidocaine in the conscious dog. *Anesth Analg* 69, 794-801.

Feldman HS, Arthur GR, Pitkanen M et al. (1991) Treatment of acute systemic toxicity after the rapid intravenous injection of ropivacaine and bupivacaine in the conscious dog. *Anesth Analg* 73, 373-384.

Snyder LB, Snyder CJ, Hetzel S. (2016) Effects of Buprenorphine Added to Bupivacaine Infraorbital Nerve Blocks on Isoflurane Minimum Alveolar Concentration Using a Model for Acute Dental/Oral Surgical Pain in Dogs. *J Vet Dent.* ;33(2):90-96.

Shama T, Gopal L, Shanmugam MP, et al (2002): Comparison of pH-adjusted bupivacaine with a mixture of non-pH-adjusted bupivacaine and lignocaine in primary vitreoretinal surgery. *Retina.* 22(2): 202-7.

Krug W, Losey J. Area of desensitization following mental nerve block in dogs. *J Vet Dent.* 28(3):146-50.

Apra F, Vettorato E and Corletto F.(2011) Severe cardiovascular depression in a cat following a mandibular nerve block with bupivacaine. *Vet Anaesth Analg*; 38: 614–618.

Loughran CM, Rasis AL, Haitjema G, Chester Z.(2016)Unilateral retrobulbar hematoma following maxillary nerve block in a dog. *J Vet Emerg Crit Care (San Antonio).* 26(6):815-818.

Perry R, Moore D, Scurrill E.(2015) Globe penetration in a cat following maxillary nerve block for dental surgery. *J Feline Med Surg.* 17(1):66-72.

Smith MM¹, Smith EM, La Croix N, Mould J.(2003) Orbital penetration associated with tooth extraction. *J Vet Dent.* 20(1):8-17.

Guerreiro CE, Appelboam H, Lowe RC.(2014) Successful medical treatment for globe penetration following tooth extraction in a dog. *Vet Ophthalmol.*17(2):146-9.

Section 4: Oral Examination and Recording

A thorough oral diagnosis of every patient is based on the results of the case history, clinical examination and charting, dental radiography and laboratory tests if indicated. The examination must be performed in a systematic way to avoid missing important details. All findings should be recorded in the medical history.

1. Examination of Conscious Patient

Some procedures can be performed on a conscious patient during the first consultation. The results provide an overview of the level of disease and allows for the formation of the preliminary treatment plan. This should be thoroughly discussed with the owner, including the fact that this is only an initial plan and further therapy is often necessary based on the examination and radiographs obtained under anesthesia.

Oral/Dental Examination

The examination starts with a thorough history including symptoms which may indicate dental disorders such as: halitosis, change in eating habits, ptyalism, head shaking etc. The clinical investigation begins with the inspection of the head by evaluating the eyes, symmetry of the skull, swellings, lymph nodes, nose and lips. Next, the occlusion and the functionality of the temporomandibular joint (TMJ) should be evaluated. The dental examination includes noting the stage of dentition (primary/permanent), as well as any missing, fractured, or discolored teeth. The examination of the soft tissues of the oral cavity includes oral mucosa, gingiva, palate, dorsal and ventral aspect of the tongue, tonsils, salivary glands and ducts. The examiner should evaluate the oral soft tissues for masses, swelling, ulcerations, bleeding and inflammation. The conscious periodontal exam should focus on gingival inflammation, calculus deposits and gingival recession. Furthermore, a periodontal diagnostic test strip for measurement of dissolved thiol levels can be a very useful exam room indicator for gingival health and periodontal status (Manfra Maretta et al, 2012). This product has been shown to improve client compliance with dental recommendations.

Oral Health Index (OHI)

The first step in every case is the collection of a minimum clinical database. The Oral Health Index (OHI) (Gawor et al., 2006) is a useful tool created from a basic examination on a conscious patient and gives a good overall clinical impression. The examination includes not only the oral cavity and adjacent regions, but also life style and nutrition. The examined criteria are: lymph nodes, dental deposits, periodontal status, nutrition and oral care (professional and homecare). Each criteria is scored with respect to the clinical findings and a total score is then determined. The result helps in decision making and determining whether further examination and/or treatment is indicated. [link to PDF](#)

Occlusion

According to the nomenclature committee of the American Veterinary Dental College (AVDC) the ideal occlusion is described as: perfect interdigitation of the maxillary and mandibular teeth. In the dog, the ideal tooth positions in the arches are defined by the occlusal, inter-arch, and interdental relationships of the teeth of the archetypal dog (i.e. wolf)

(www.avdc.org/nomenclature). Abnormities are defined as either a skeletal malocclusion or malposition of single teeth (for more detail see chapter 1d: Malocclusion).

Checklist for dental occlusion: (Gorrel C, 2004)

1. Head symmetry
2. Incisor relationship
3. Canine occlusion
4. Premolar alignment
5. Caudal premolar/molar occlusion
6. Individual teeth positioning

2. Examination under General Anaesthesia

A thorough examination can only be performed under general anaesthesia. Pre-anaesthetic workup and anaesthesia are described within Section XX, Anaesthesia. Following induction of anaesthesia, the examination should be performed in a detailed and structured way with the charting performed simultaneously. After the visual inspection of the entire oral cavity, the tactile examination is performed in two steps utilizing the appropriate instruments. First, the teeth themselves are examined for defects such as tooth wear, resorption, caries, pulp exposure, and enamel disease with a dental explorer. Following this, pocket depth and furcation exposure are evaluated with a periodontal probe. It is crucial to know the anatomy of the involved structures to create a proper diagnosis (for more detail see chapter 1a: Oral and Dental Anatomy and Physiology). It is very helpful to work four-handed with one person examining and the other recording what is reported (Huffman LJ, 2010).

Examination step-by-step:

1. **Inspect the oropharynx:** it is advisable to make a quick inspection of the oropharynx before endotracheal intubation and placing a throat pack. (Fig 1)
2. **Take a preoperative photograph:** preoperative photographs should be taken before any procedure. It is recommended to take one of each side and one from the rostral aspect. The photographs serve as proof for pre-operative dental condition as well as provide visual evidence to the owner. It is recommended to use a lip retractor or dental mirror to better visualize the entire dentition and surrounding structures (Fig. 2)
3. **Decrease the bacterial load:** rinse the oral cavity with 0.12% chlorhexidine.
4. **Assess and identify the dentition:** primary, permanent, or mixed.
5. **Assess the soft tissue:** the entire oral cavity should be examined, including oral mucosa and mucous membranes (for colour, moistness, swelling), lips and cheeks, palate, tongue and sublingual tissue for alterations and oral masses.
6. **Initial scaling of the teeth:** for better visibility of the tooth surfaces and gingiva an initial cleaning with a dental scaler is recommended.

7. **Intraoperative photograph:** it is advised to take a photograph of any pathology revealed by the scaling (Fig. 3)

8. **Dental examination with dental explorer:** each tooth must be examined with a dental explorer, beginning with the first incisor of each quadrant and progressing distally caudally tooth by tooth to cover the entire arch. It is easier to examine a dry tooth (Baxter CJK, 2007) and a dental mirror can be very helpful. A normal tooth surface is very smooth; any roughness is an indication of pathology. The entire surface of each tooth should be explored, especially the area just below the gingival margin to detect resorptive lesions. The examination should note:
 - a. **Presence (or absence) of the teeth:** the absence of a tooth can mean hypodontia (congenitally missing teeth), an unerupted (or impacted) tooth, a retained tooth root, or a previously extracted or exfoliated tooth (Niemic BA, 2010). Occasionally, a “missing” tooth will actually be a malformed tooth. Dental radiographs are always indicated for every instance of a “missing” tooth (Niemic BA, 2011). Supernumerary teeth are possible.
 - b. **Tooth surface:** any irregularity is suspicious for a pathologic process. Various differentials for a roughened tooth surface include: tooth fracture (uncomplicated/complicated) (for more detail see chapter 1c: Fractured Teeth), enamel defect (e.g. hypocalcification), caries, attrition/abrasion, or tooth resorption (DuPont GA, 2010) (for more detail see chapter 2f: Tooth Resorption)
 - c. **Colour** (DuPont GA, 2010): Intrinsic staining (a purple, yellow, pink or gray tooth) indicates pulpitis (i.e. a non-vital tooth). (Fig 4) These teeth require root canal therapy or extraction. Extrinsic staining may be due to wear, metal chewing, and certain drugs in the developmental period. These teeth generally require no therapy, but dental radiographs are indicated.

9. **Periodontal examination:**
 - a. **Periodontal probing depth (PPD):** the periodontal probing depth has to be measured with a graduated periodontal probe on at least 4-6 spots on each root of every tooth (Holstrom SE et al., 2004). The normal PPD in dogs is 0-3 mm, and in cats in cats 0-1 mm (Niemic BA, 2012). (For more detail see chapter 1b: Periodontal Disease)
 - b. **Gingival enlargement:** enlargement of the gingiva can lead to pseudo pockets (Fig. 5)
 - c. **Gingival recession:** is an indication of periodontal disease although the PPD does not necessarily increase (Fig. 6)
 - d. **Furcation involvement:** furcation involvement indicates bone loss between the roots of multi rooted teeth. (Fig. 7)
 - e. **Mobility:** the grade of mobility has to be determined (Fig. 8)
 - f. **Total Mouth Periodontal Score (TMPS):** this method allows for a very accurate determination of the patient’s periodontal health, Harvey CE et al., 2008)

10. **Expose dental radiographs:** dental radiographs are a very important part of the dental examination and should be taken whenever possible (Niemiec BA, 2011). (Figure 9) For more detail see chapter 2c: Radiology
11. **Staging of periodontal disease:** staging can be performed by combining the clinical findings and the dental radiographs (American Veterinary Dental College, 2017)(Fig. 10)
12. **Definitive cleaning and polishing**
13. **Additional therapy:** Based on all available information (visual, tactile, and radiographic) determine and execute the final treatment plan. This can be done before or after definitive cleaning
14. **Postoperative radiographs and photographs** (Fig. 11)

Dental radiographs are a critical part of the oral exam, however at the time of this paper, they are not widely utilized (Hotlink to Required Equipment Section). In this situation, a thorough examination with a dental explorer, a periodontal probe and a mirror will give fairly accurate information about status of the oral cavity. Periodontal staging without dental x-ray is very inaccurate but if there is no option it still may be of some help. While it varies by tooth, the ratio of crown:root is roughly 40:60 on average. By measuring the crown, the length of the roots can be estimated and a staging can be approximated.

3. Recording

A thorough examination can only be performed on an anaesthetized patient. The results of the clinical examination must be recorded on a dental chart to enable the creation of a proper treatment plan in all tiers. They must also be kept as part of the medical record and may be used to illustrate, to the owner, when explaining the work performed.

Modified Triadan System

The most widely accepted dental scoring system is the Modified Triadan System (Floyd MR, 1991) which provides a consistent method of numbering teeth across different animal species. Each tooth has a three-digit number which identifies the quadrant, position and whether it is a primary or a permanent tooth. The first digit denotes the quadrant, which is numbered clockwise beginning at the upper right quadrant (1-4 for permanent dentition, 5-8 for primary dentition). The second and third digits refer to the position within the quadrant, with the sequence always starting at the midline with the first incisor (Fig. 12).

The advantages of the Modified Triadan System are that it allows for easy identification of a tooth, is understood throughout the world (no language barrier), issuitable for all species, faster than writing out the tooth description, and ideal for digitalized recording and statistics.

Manual Scoring

The clinical findings can be recorded manually (Fig. 13). Dental charts for several species are available for free download at (<http://cpd.vetdent.eu>). The results can either be hand drawn into a dental chart or marked in an attached multiple choice spreadsheet. The most common signs for dental recording are a circle for a missing tooth (O), a hash mark for a fractured tooth (#) and a cross for an extracted tooth (X). For more detailed instructions see the basic periodontal therapy section.

Electronic Scoring

The results can also be recorded digitally.

The European Veterinary Dental Society (UK charity 1128783) provides a free online dental charting software (**electronic Veterinary Dental Scoring**) available for all veterinarians in five screen languages (English, French, German, Spanish, Portuguese). It is a simple tool to support the practitioner in their daily work. The basic clinical findings can be scored with a simple mouse click onto the dental charts. The scored criteria are: missing tooth, persistent deciduous tooth in dogs/resorptive lesions in cats, fractured tooth, inflammation index, extraction. The reports may be saved in the clinic software as a PDF and/or printed out for the owner in one of six common languages (English, French, German, Italian, Spanish, Portuguese) or easily changed into any other by hand. With a few clicks the clinic data and logo can be inserted, and an individual report created which will increase the customer loyalty (Fig. 14). The programme is also equipped with a tutorial which is based on photographs. The feature serves as educational tool, diagnostic and treatment planning aid, and may be used for illustrating the condition to the client. Access to the program is via: www.evds.org.

Tier 2 & 3 are recommended to use a more detailed commercial programme. There are several options available (stand 2017 in alphabetical order: www.chartific.com; www.evds.org; www.vetdentalcharts.com).

Key Points:

- The conscious examination is important but is of very limited value, as a complete exam is only possible under general anesthesia. This is one of the many reasons this committee strongly discourages non-anesthesia dentistry (NAD).
- A thorough oral examination **MUST** be part of every dental procedure
- The Modified Triadan System should be used for dental charting/recording.
- The examination of the oral cavity must be performed in a structured and repeatable fashion
- Dental radiographs are an essential part of the examination
- If there is no x-ray unit available, a thorough examination with dental explorer and periodontal probe provides a fairly adequate picture of the dental condition
- Proper recording of clinical findings and treatments is critical

References:

- American Veterinary Dental College (2017), <http://www.avdc.org> (accessed 29 April 2017)
- Baxter CJK (2007) Oral and dental diagnostics. In: BSAVA Manual of Canine and Feline Dentistry. 3rd ed. Eds C. Tutt, J. Deeprose, D. Crossley. British Small Animal Veterinary Association, Gloucester. pp 22-40
- Dupont GA (2010) Pathologies of the dental hard tissue. In: Small Animal Dental, Oral & Maxillofacial Disease. Ed B. A. Niemiec. Manson Publishing Ltd., London. pp 127-157
- Floyd MR (1991) The modified Triadan system: Nomenclature for veterinary dentistry. *Journal of Veterinary Dentistry* 8(4): 18-19
- Gawor JP, Reiter AM, Jodkowska K (2006) Influence of Diet on Oral Health in Cats and Dogs. *Journal of Nutrition* 136: 2021S-2023S
- Gorrel C (2004) Odontoclastic resorptive lesions. In: Veterinary Dentistry for the General Practitioner, 1st edition. Ed C. Gorell. WB Saunders, Philadelphia, pp 119-129
- Harvey CE, Laster L, Shofer F, Miller B (2008) Scoring the full extent of periodontal disease in the dog: development of a total mouth periodontal score system (TMPS) system. *Journal of Veterinary Dentistry* 25(3): 174-178
- Holmstrom SE, Frost P, Eisner ER (2004) Dental prophylaxis and periodontal disease stages. In: Veterinary Dental Techniques, for the Small Animal Practitioner. 3rd edn. Eds S. E. Holstrom, P. Frost Fitch, E. R. Eisner. WB Saunders, Philadelphia. pp 175-232
- Huffman LJ (2010) Oral Examination. In: Small Animal Dental, Oral & Maxillofacial Disease. Ed B. A. Niemiec. Manson Publishing Ltd., London. pp 39-61
- Manfra Marretta S, Leesman M, Burgess Cassler A et al. (2012) Pilot evaluation of a novel test strip for the assessment of dissolved thiol levels, as an indicator of canine gingival health and periodontal status. *Canadian Veterinary Journal*: 1260-1265
- Niemiec BA (2010) Pathology in the Pediatric Patient. In: Small Animal Dental, Oral & Maxillofacial Disease. Ed B. A. Niemiec. Manson Publishing Ltd., London. pp 89-126
- Niemiec BA (2011) The Importance of Dental Radiology. *European Journal of Companion Animal Practice* 20(3): 219-229
- Niemiec BA (2012) The complete dental cleaning. In: Veterinary Periodontology. Ed B. A. Niemiec. Wiley-Blackwell, Ames. pp 129-153
- Clarke DE, Caiafa A (2014) Oral examination in the cat: a systematic approach. *J Feline Med Surg*. Nov;16(11): 873-886
- Wolf HF, Rateitschak EM, Rateitschak KH et al. Color atlas of dental medicine: periodontology, 3rd ed. Stuttgart: Georg Thieme Verlag, 2005.

Figures:

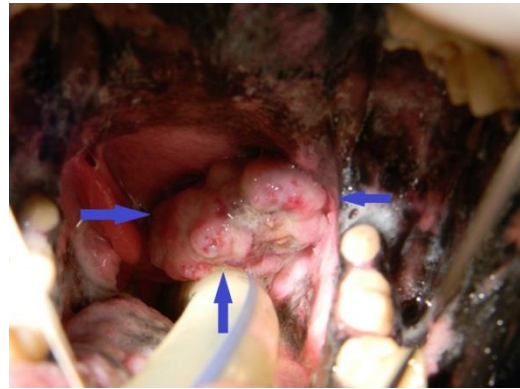
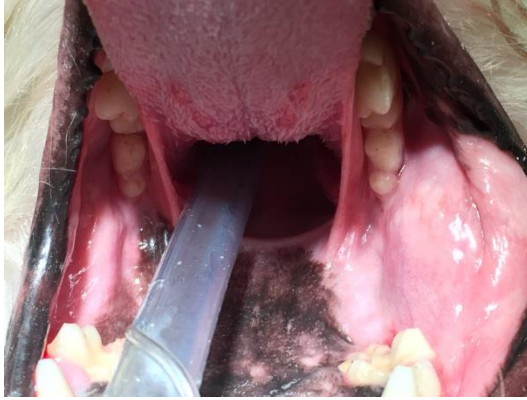

Fig.1 Oropharyngeal exam Normal (left) and abnormal (Oral Mass – right))

Fig. 2 Pre-op photograph

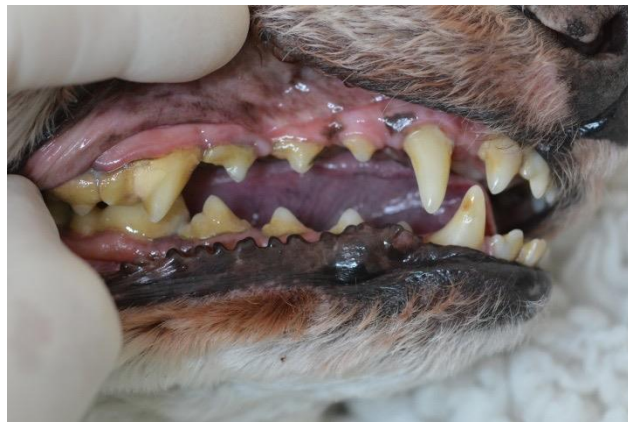

Fig. 3 Intra-op photograph

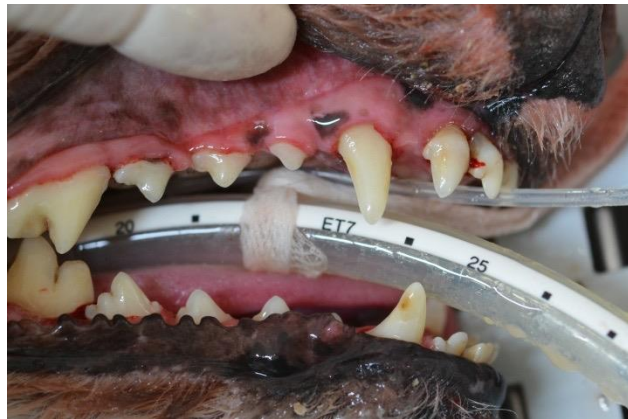

Fig. 4 Intrinsic Staining

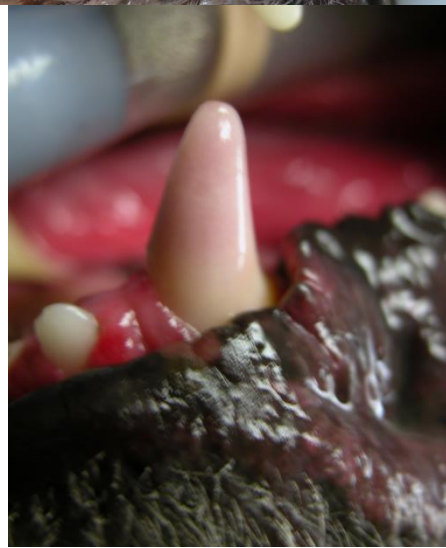

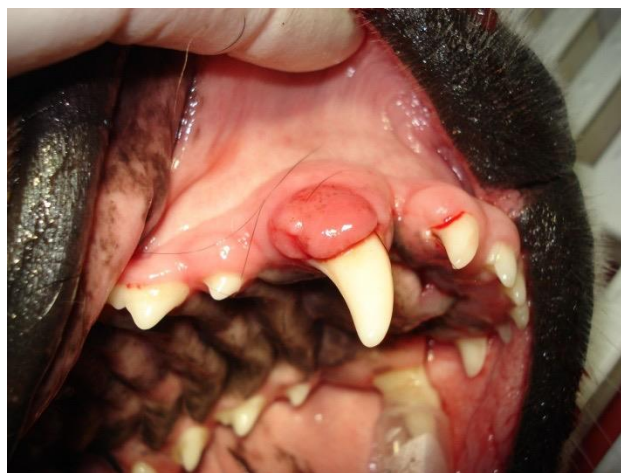


Fig. 5 Gingival enlargement

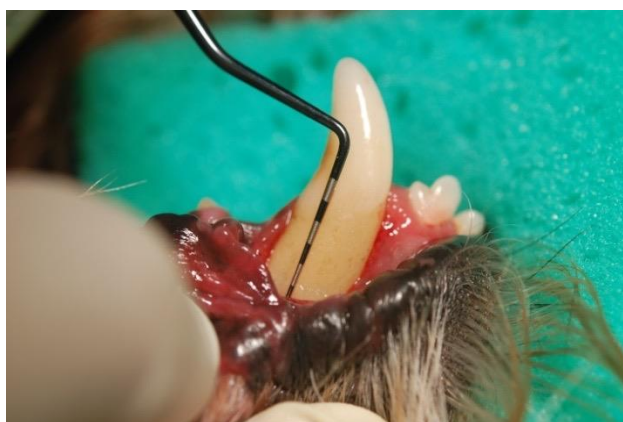

Fig. 6 Gingival recession

Furcation Index

Stage 1 (F1): Furcation 1 involvement exists when a periodontal probe extends less than half way under the crown in any direction of a multirooted tooth with attachment loss.

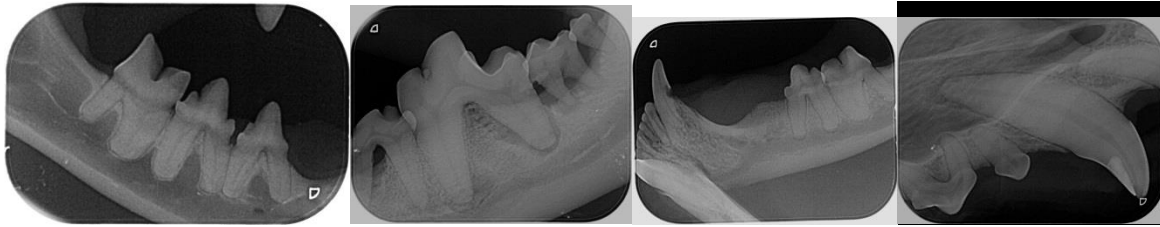
Stage 2 (F2): Furcation 2 involvement exists when a periodontal probe extends greater than half way under the crown of a multirooted tooth with attachment loss but not through and through.

Stage 3 (F3): Furcation exposure exists when a periodontal probe extends under the crown of a multirooted tooth, through and

Fig. 7

Fig. 8

Fig 9: Importance of dental radiographs



Stages of Periodontal Disease

The degree of severity of periodontal disease (**PD**) relates to a single tooth; a patient may have teeth that have different stages of periodontal disease.

Normal (PD0): Clinically normal; gingival inflammation or periodontitis is not clinically evident.

Stage 1 (PD1): Gingivitis only without attachment loss; the height and architecture of the alveolar margin are normal.

Stage 2 (PD2): Early periodontitis; less than 25% of attachment loss or, at most, there is a stage 1 furcation involvement in multirooted teeth. There are early radiologic signs of periodontitis. The loss of periodontal attachment is less than 25% as measured either by probing of the clinical attachment level, or radiographic determination of the distance of the alveolar margin from the cemento-enamel junction relative to the length of the root.

Stage 3 (PD3): Moderate periodontitis - 25-50% of attachment loss as measured either by probing of the clinical attachment level, radiographic determination of the distance of the alveolar margin from the cemento-enamel junction relative to the length of the root, or there is a stage 2 furcation involvement in multirooted teeth.

Stage 4 (PD4): Advanced periodontitis; more than 50% of attachment loss as measured either by probing of the clinical attachment level, or radiographic determination of the distance of the alveolar margin from the cemento-enamel junction relative to the length of the root, or there is a stage 3 furcation involvement in multirooted teeth.

www.avdc.org

Figure 10: staging of periodontal disease

Fig. 11 Post-op photograph

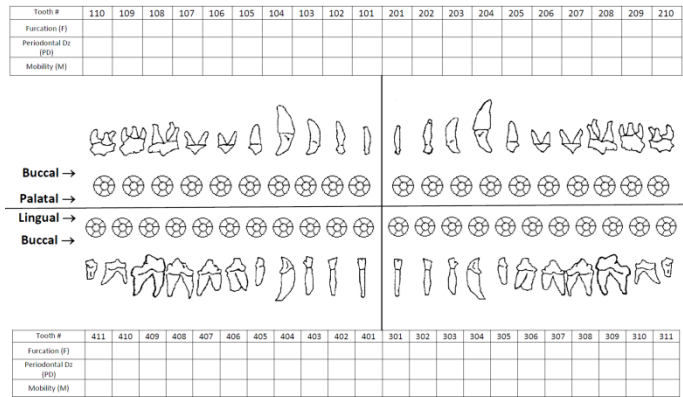
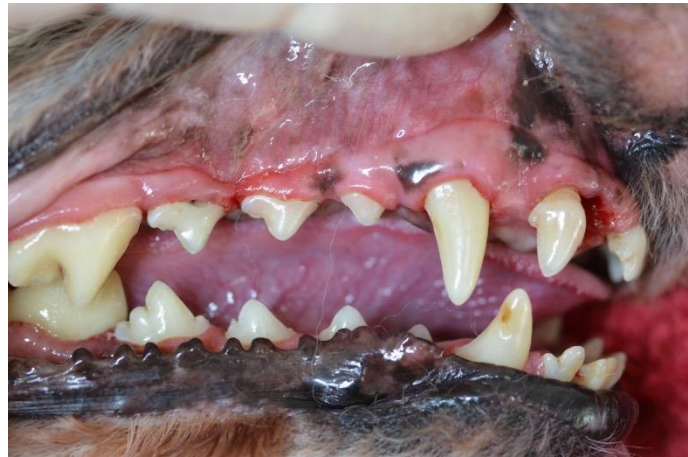

Fig 12: Dental chart with Modified Triadan System

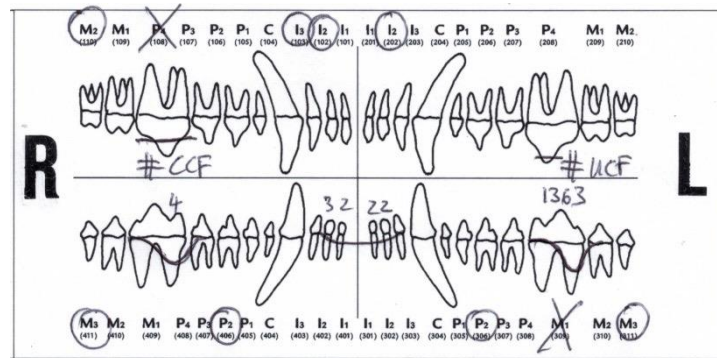


Fig 13: Manual scoring on a canine dental chart



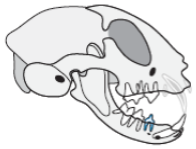
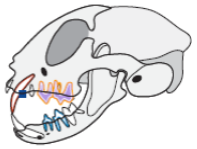
 World Small Animal Veterinary Association 72 Melville Street L6M 2A1 Ontario (Canada) Tel: 12344567890		Date: 12/02/2017 Patient name: YODA Client: Smith Albert																																																																																																																																																																																																																																																
<table border="1"> <thead> <tr> <th>I</th><th>M</th><th>F</th><th>TR</th><th>E</th><th></th></tr> </thead> <tbody> <tr><td></td><td></td><td></td><td></td><td></td><td>101 (I1)</td></tr> <tr><td></td><td></td><td></td><td></td><td></td><td>102 (I2)</td></tr> <tr><td></td><td></td><td></td><td></td><td></td><td>103 (I3)</td></tr> <tr><td></td><td></td><td></td><td></td><td></td><td>104 (C)</td></tr> <tr><td></td><td></td><td></td><td></td><td></td><td>105 (P1)</td></tr> <tr><td></td><td></td><td></td><td></td><td></td><td>106 (P2)</td></tr> <tr><td></td><td></td><td></td><td></td><td></td><td>107 (P3)</td></tr> <tr><td></td><td></td><td></td><td></td><td></td><td>108 (P4)</td></tr> <tr><td></td><td></td><td></td><td></td><td></td><td>109 (M1)</td></tr> <tr><td colspan="6" style="text-align: center;">Right</td></tr> <tr><td></td><td></td><td></td><td></td><td></td><td>409 (M1)</td></tr> <tr><td></td><td></td><td></td><td></td><td></td><td>408 (P4)</td></tr> <tr><td></td><td></td><td></td><td></td><td></td><td>407 (P3)</td></tr> <tr><td></td><td></td><td></td><td></td><td></td><td>406 (P2)</td></tr> <tr><td></td><td></td><td></td><td></td><td></td><td>405 (P1)</td></tr> <tr><td></td><td></td><td></td><td></td><td></td><td>404 (C)</td></tr> <tr><td></td><td></td><td></td><td></td><td></td><td>403 (I3)</td></tr> <tr><td></td><td></td><td></td><td></td><td></td><td>402 (I2)</td></tr> <tr><td></td><td></td><td></td><td></td><td></td><td>401 (I1)</td></tr> </tbody> </table>	I	M	F	TR	E							101 (I1)						102 (I2)						103 (I3)						104 (C)						105 (P1)						106 (P2)						107 (P3)						108 (P4)						109 (M1)	Right											409 (M1)						408 (P4)						407 (P3)						406 (P2)						405 (P1)						404 (C)						403 (I3)						402 (I2)						401 (I1)	<h3 style="text-align: center;">Dental assessment</h3> 	<table border="1"> <thead> <tr> <th>I</th><th>M</th><th>F</th><th>TR</th><th>E</th><th></th></tr> </thead> <tbody> <tr><td></td><td></td><td></td><td></td><td></td><td>201 (I1)</td></tr> <tr><td></td><td></td><td></td><td></td><td></td><td>202 (I2)</td></tr> <tr><td></td><td></td><td></td><td></td><td></td><td>203 (I3)</td></tr> <tr><td></td><td></td><td></td><td></td><td></td><td>204 (C)</td></tr> <tr><td></td><td></td><td></td><td></td><td></td><td>205 (P1)</td></tr> <tr><td></td><td></td><td></td><td></td><td></td><td>206 (P2)</td></tr> <tr><td></td><td></td><td></td><td></td><td></td><td>207 (P3)</td></tr> <tr><td></td><td></td><td></td><td></td><td></td><td>208 (P4)</td></tr> <tr><td></td><td></td><td></td><td></td><td></td><td>209 (M1)</td></tr> <tr><td colspan="6" style="text-align: center;">Left</td></tr> <tr><td></td><td></td><td></td><td></td><td></td><td>309 (M1)</td></tr> <tr><td></td><td></td><td></td><td></td><td></td><td>308 (P4)</td></tr> <tr><td></td><td></td><td></td><td></td><td></td><td>307 (P3)</td></tr> <tr><td></td><td></td><td></td><td></td><td></td><td>306 (P2)</td></tr> <tr><td></td><td></td><td></td><td></td><td></td><td>305 (P1)</td></tr> <tr><td></td><td></td><td></td><td></td><td></td><td>304 (C)</td></tr> <tr><td></td><td></td><td></td><td></td><td></td><td>303 (I3)</td></tr> <tr><td></td><td></td><td></td><td></td><td></td><td>302 (I2)</td></tr> <tr><td></td><td></td><td></td><td></td><td></td><td>301 (I1)</td></tr> </tbody> </table>	I	M	F	TR	E							201 (I1)						202 (I2)						203 (I3)						204 (C)						205 (P1)						206 (P2)						207 (P3)						208 (P4)						209 (M1)	Left											309 (M1)						308 (P4)						307 (P3)						306 (P2)						305 (P1)						304 (C)						303 (I3)						302 (I2)						301 (I1)
I	M	F	TR	E																																																																																																																																																																																																																																														
					101 (I1)																																																																																																																																																																																																																																													
					102 (I2)																																																																																																																																																																																																																																													
					103 (I3)																																																																																																																																																																																																																																													
					104 (C)																																																																																																																																																																																																																																													
					105 (P1)																																																																																																																																																																																																																																													
					106 (P2)																																																																																																																																																																																																																																													
					107 (P3)																																																																																																																																																																																																																																													
					108 (P4)																																																																																																																																																																																																																																													
					109 (M1)																																																																																																																																																																																																																																													
Right																																																																																																																																																																																																																																																		
					409 (M1)																																																																																																																																																																																																																																													
					408 (P4)																																																																																																																																																																																																																																													
					407 (P3)																																																																																																																																																																																																																																													
					406 (P2)																																																																																																																																																																																																																																													
					405 (P1)																																																																																																																																																																																																																																													
					404 (C)																																																																																																																																																																																																																																													
					403 (I3)																																																																																																																																																																																																																																													
					402 (I2)																																																																																																																																																																																																																																													
					401 (I1)																																																																																																																																																																																																																																													
I	M	F	TR	E																																																																																																																																																																																																																																														
					201 (I1)																																																																																																																																																																																																																																													
					202 (I2)																																																																																																																																																																																																																																													
					203 (I3)																																																																																																																																																																																																																																													
					204 (C)																																																																																																																																																																																																																																													
					205 (P1)																																																																																																																																																																																																																																													
					206 (P2)																																																																																																																																																																																																																																													
					207 (P3)																																																																																																																																																																																																																																													
					208 (P4)																																																																																																																																																																																																																																													
					209 (M1)																																																																																																																																																																																																																																													
Left																																																																																																																																																																																																																																																		
					309 (M1)																																																																																																																																																																																																																																													
					308 (P4)																																																																																																																																																																																																																																													
					307 (P3)																																																																																																																																																																																																																																													
					306 (P2)																																																																																																																																																																																																																																													
					305 (P1)																																																																																																																																																																																																																																													
					304 (C)																																																																																																																																																																																																																																													
					303 (I3)																																																																																																																																																																																																																																													
					302 (I2)																																																																																																																																																																																																																																													
					301 (I1)																																																																																																																																																																																																																																													
 <p>Occlusion: Normal occlusion</p> <p>Stomatitis level: 0</p>	<h4 style="text-align: center;">Legend</h4> <ul style="list-style-type: none"> I ■ Inflammation index (0-3) M ■ Missing tooth F ■ Fractured tooth TR ■ Tooth resorption E ■ Extraction 																																																																																																																																																																																																																																																	
<p>General notes:</p> <p>Notes: 204 (C): uncomplicated fracture; sealing</p>																																																																																																																																																																																																																																																		

Fig. 14: Printout for client

Section 5: Periodontal Therapy

Basic Professional Therapy

There are numerous therapeutic options available for periodontal disease, however, the basis of periodontal therapy remains plaque control.

Plaque removal and control consists of 4 aspects depending on the level of disease. These therapies include: (Niemic BA 2013)

1. The complete dental prophylaxis (cleaning, Oral ATP, (assessment, treatment, prevention) or COHAT (Comprehensive Oral Health Assessment and Treatment). (Bellows J 2010)
2. Homecare
3. Periodontal surgery
4. Extraction

This section will cover the complete dental prophylaxis/cleaning as well as basic indications for periodontal surgery and extractions. Homecare and basic extraction techniques will be covered elsewhere in this document, however periodontal surgery is beyond the scope of these guidelines.

Regardless of the name, the goal of this procedure is not only to clean and polish the teeth, but also to evaluate the periodontal tissues and entire oral cavity. Any professional periodontal therapy for veterinary patients must be performed under general anaesthesia, with a well-cuffed endotracheal tube (Colmery 2005, Niemic 2003, Niemic 2013, Holmstrom 1998, AAHA 2013). Only when the patient is properly anaesthetized can a safe and effective cleaning and oral exam be performed.

It is important to note that proper periodontal/dental/oral therapy takes time and patience. A minimum of one hour should be allotted for all dental cases and much more in many instances. Professional periodontal therapies must be performed with quality (not quantity) in mind.

Procedure:

A complete dental prophylaxis should include the following minimal steps (Bellows J 2010; Niemic BA 2013, Niemic BA 2003; Holmstrom et al 1998; Wiggs RB & Lobprise HB 1997).

Step 1: Pre surgical exam and consultation: (Huffman LJ 2010)

The veterinarian should perform a complete physical and oral examination. The physical exam, in combination with pre-operative testing, screens for general health issues which may exacerbate periodontal disease or compromise anaesthetic safety. (Joubert KE 2007) (See anesthesia section.)

The conscious oral examination should identify most obvious oral pathologies as well as allow for a preliminary assessment of periodontal status. The use of a periodontal diagnostic strip by the examining veterinarian can improve the accuracy of the conscious periodontal evaluation. The veterinarian can then discuss the various disease processes found on the examination as well

as the available treatment options with the owner. This face-to-face discussion will improve client understanding of the disease processes and associated sequela.

Based on the oral examination findings, the practitioner can create a more accurate estimate both of procedure time and financial costs to the client. The client should be made aware at this point that a complete oral examination is **not** possible on a conscious patient.

Staff and patient protection

Numerous studies have shown that ultrasonic and sonic scalers create significant bacteria laden aerosols (Szymańska J 2007; Harrel SK 2004; Pederson ED et al 2002). The infectious organisms are not only supplied by the patient's mouth, but also the water lines of the mechanized hand pieces (ultrasonic scalers and high speed hand-pieces). (Shearer BJ 1996; Meiller TF et al 1999; Wirthlin MR et al 2003) Staff members performing dental prophylactic (or **any** dental) procedures should be instructed to wear personal protective equipment (mask, goggles, and gloves) at all times to decrease contamination (Figure 2). (Pattison AM & Pattison GL 2006; Harrel SK et al 1998; Holmstrom SE et al 2002) Furthermore, a bacterial water filter or chlorhexidine flushing of the system is recommended to decrease contamination. (Bellows J 2004) Dental procedures also must **not** be performed in "sterile" environments such as surgical suites. Furthermore, they should not be performed near any sick or compromised patients, or near any clean procedures. (Bellows J 2004) Dental procedures are best confined to their own designated room. (Legnani P et al 1994; Osorio R et al 1995; Leggat PA & Kedjarune U 2001; Al Maghlouth A 2007)

Step 2: Chlorhexidine lavage:

The oral cavity is a contaminated area and thorough dental cleanings are mildly invasive. This means that dental cleanings often result in a transient bacteremia, which is more severe in patients with periodontitis. (Lafaurie GI et al 2007; Forner L et al 2006; Daly CG et al 2001) Dental cleanings cause bacterial aerosolization and contamination of the office environment when ultrasonic instruments are employed (as above Rinsing the oral cavity with a 0.12 or 0.2% solution of chlorhexidine gluconate prior to commencing the prophylaxis, has been shown to decrease the bacterial load. (Fine DH et al 1993; Bellows J 2004)

Step 3: Supragingival cleaning

Very large accumulations of calculus can be quickly removed using calculus forceps. However, this must be done very carefully to avoid tooth and gingival damage. Supragingival scaling can be performed via mechanical or hand scaling, but is best performed using a combination of the modalities (Pattison AM & Pattison GL 2006; Bellows J 2004).

Mechanical scalers

Mechanical scalers include both sonic and ultrasonic types. (Jahn CA 2006, Holmstrom SE et al 1998). The most common used mechanical scaler in veterinary dentistry today is the ultrasonic model. There are two main types (magnetostrictive and piezoelectric). (Wiggs RB & Lobprise HB 1997) Both of these ultrasonic scalers vibrate at approximately 25,000-45,000 Hertz. Both types of ultrasonic scalers are very efficient and provide the additional benefit of creating an antibacterial effect in the coolant spray (cavitation). (Felver B et al 2009; Arabaci T et al 2007)

Sonic scalers run on compressed air and vibrate at only 2,000-6,500 hertz, although rates of up to 9,000 Hz have been reported. At slower rates of vibration, they generate minimal heat, and therefore may be a safer alternative to ultrasonics

(See equipment section for a complete discussion of mechanical scalers).

Mechanical scaling

When using any of the mechanical scalers, the first concern is the power level setting of the instrument. Ultrasonic tips have a recommended oscillation (Hz) range and this should be determined and set prior to initiating scaling. The power should be set low and adjusted upward to the *minimum* required power. The area of maximum vibration for ultrasonic scalers is 1-3 mm from the tip. (DeBowes LJ 2010) Do not use the sharp pointed tip of the instrument, but the flat plane of the instrument, as the point is not effective for calculus removal and can potentially damage the enamel of the tooth.

Next, it is important to ensure that there is adequate coolant being delivered through the working end of the scaler. A fine but significant spray should be evident when the unit is activated. (Figure 1) Utilizing a mechanical scaler without sufficient coolant can cause numerous deleterious effects including tooth death. (Nicoll BK & Peters RJ 1998) It is important to note that standard periodontal tips must **not** be introduced under the gingival margin. (Wiggs RB & Lobprise HB 1997) The water coolant will not reach the working area of the instrument, which results in overheating and possible tooth damage, especially when using the magnetostrictive scalers. Specific low-powered periodontal tips are available for subgingival use, and clinicians and staff should familiarize themselves with this equipment prior to their use. Units supplied with periodontal tips also have settings on the machine appropriate for subgingival scaling.

The instrument should be gently grasped to increase tactile sensitivity, decrease operator fatigue and provide superior cleaning.

Place the side of the instrument in contact with the tooth surface with a very light touch. (Debowes LJ 2010) (Figure 2) Additional pressure on the instrument will **not** improve its efficiency, and can result in damage to both the instrument and the tooth (Brine EJ et al 2000). Excessive downward pressure on the scaler tip may stop the oscillation entirely.

Run the instrument across the *entire* tooth surface using numerous overlapping strokes in different directions. Keep the instrument in motion at all times to avoid tooth damage.

It has long been recommended to strictly limit the amount of time ultrasonic scalers linger on one tooth. Typically, it is recommended that they be kept in constant contact with tooth for no more than 15 seconds. In addition, heat damage is generally caused by lack of water cooling. (Nicoll BK & Peters RJ 1998; Vérez-Fraguela JL et al 2000)

Once the instrument loses contact with the tooth, the scaler can no longer be effective. The instrument should be kept in constant motion, running **slowly** over the tooth surface in overlapping, wide, sweeping motions. Plaque can be microscopically present on all surfaces of the tooth, regardless of the fact that the tooth appears clean, and such each square mm of every tooth surface should be treated.

Damage affecting the terminal 1-mm of the tip reduces efficiency of an ultrasonic scaler by 25% and 2-mm by 50%. (Bellows J 2004) Therefore, new tips should be used when old ones wear out.

Rotosonic scaling, while popular in the past, is no longer a recommended form of scaling. (Bellows J 2004) This is due to the fact that these instruments produce a significantly rougher surface compared to hand and ultrasonic/sonic power scalers. (Brine EJ et al 2000) In addition, they are by far the most damaging mechanical scaling instrument. (Wiggs RB & Lobprise HB 1997)

Hand Scaling:

Equipment

Supragingival hand scaling is performed with a scaler. This is a triangular instrument with two sharp cutting edges and a sharp tip. Typically, the blade is positioned at a 90 degree angle to the shaft, and this is called a universal scaler. Scalers are designed for supra-gingival use only, as the shape of the instrument as well as the sharp back and tip can easily damage the gingiva. (See the equipment section for a detailed description of periodontal hand instrumentation)

Note, periodontal hand instruments are only effective when sharp. This means they need to be sharpened on a regular basis (at least weekly if used regularly).

Technique

Hand instruments are typically held with a modified pen grasp (Figure 3), but, other grips may be necessary in certain situations. The instrument is gently held at the textured or rubberized end, between the *tips* of the thumb and index finger. The middle finger is placed near the terminal end of the shaft and is used to feel for vibrations which signal residual calculus or diseased/rough tooth/root surfaces. Finally, the 4th and 5th fingers are rested on a stable surface, generally the target tooth or nearby teeth. This grasp and described method of cleaning allow for maximum control during the scaling procedure.

Hand instruments must also be used with a gentle touch. The instrument is held with the terminal shank parallel to the tooth surface and the blade placed at the gingival margin (Figure 4). Hand scalers are used in a pull stroke fashion, which helps avoid inadvertent laceration of the gingiva by pulling away from the soft tissue (Pattison AM & Pattison GL 2006; Bellows J 2004).

Step 4: Subgingival plaque and calculus scaling

This is the most important step of the dental cleaning, as *supragingival* plaque control is insufficient to treat periodontal disease. (Westfelt E et al 1998)

Subgingival scaling has classically been performed by hand with a curette, but advances in sonic and ultrasonic tips now allow their use under the gingival margin. While some may get satisfactory results using ultrasonic scalers alone, it is generally recommended to use a combination of ultrasonic (or sonic) and hand scaling for best results (Holmstrom 1998, Pattison AM & Pattison GL 2006; Bellows J 2004).

Hand scaling

A curette has two cutting edges (however only the one which lies against the tooth is actually used) with a blunted toe and bottom. The blunted bottom will not cut through the delicate periodontal attachment, assuming excessive force is not applied. There are two types of standard curette, universal and Gracey. Universal curettes usually have a 90 degree angle and are designed to be used throughout the mouth providing that the instrument is adapted to the tooth correctly. Gracey curettes are area specific, and are designed with different angles to provide superior adaptation to specific areas of the dentition. The proper curette should be selected based on its angulation. Curettes are labelled by numbers which correlate as: the lower the number (i.e. 1-2) the smaller the terminal angle of the shank, and the further rostral in the mouth the instrument is used. (Niemiec BA 2013) (See equipment for a complete discussion of hand instruments).

Manual subgingival scaling is a very technically demanding procedure and although it will be described here, the practitioner is directed to continuing education programs to hone their skills. Subgingival scaling is performed as follows.

1. Place the blade of the instrument on the tooth surface just coronal to the free gingival margin, with the lower shank parallel to the tooth surface. (Figure 5)
2. Rotate the instrument so that the flat “face” of the blade is against the tooth surface.
3. Insert the instrument *gently* to the base of the sulcus or pocket. (Figure 6)
4. Once the bottom of the pocket is reached, the instrument is rotated to create a 90 degree working angulation. This is when the terminal portion (or shank) is parallel to the tooth (Figure 7).
5. *Slight* pressure is applied down onto the tooth surface.
6. Remove the instrument from within the pocket in the coronal direction with a firm/short stroke. (Figure 8) This technique is repeated with numerous overlapping strokes in different apical to coronal directions until the tooth/root feels smooth.

Mechanical scaling

Traditional ultrasonic scalers (especially magnetostrictive) should not be used subgingivally to avoid damage to the gingiva, periodontal tissues, and pulp (Jahn CA 2006) Recently, sonic and ultrasonic scalers with specialized periodontal tips have been developed for subgingival use. These instruments are much easier to use and thus may provide a superior cleaning in the hands of novices, however this has not been confirmed by clinical studies (Kocher T et al 1997 (a & b)). To accomplish subgingival scaling, these instruments are used in a similar fashion as supragingival scaling described above, but more care should be taken not to damage the root surface. Again, this technique is performed with a *gentle* touch using numerous overlapping strokes until the root feels smooth.

Step 5: Residual plaque and calculus identification

After scaling, it is recommended to check the teeth with an explorer (Figure 8), feeling for any rough areas which indicate small areas of dental pathology or residual calculus. Residual plaque and calculus may also be identified by utilizing a plaque disclosing solution or by drying the tooth surfaces with air (residual calculus will appear chalky) (Pattison AM & Pattison GL 2006).

Step 6: Polishing

Dental scaling (both mechanical and hand) will result in microabrasion and roughening of the tooth surface, which will result in increased plaque adherence. (Silness J 1980; Berglundh T 2007) Polishing smooths the surface of the teeth, thus retarding plaque attachment.

Practitioners can choose to use a commercially available polish, or make their own slurry of flour of pumice and chlorhexidine solution or water. These can be mixed in a dappen dish for each patient.

The polishing procedure is typically performed with a rubber prophylaxis cup, on a slow-speed hand-piece with a 90 degree angle (prophy angle). (Fichtel T et al 2008) The hand-piece should be run at a slow speed, no greater than 3,000 RPM. Faster rotation will not improve the speed or quality of the procedure, and may result in overheating the tooth. In addition, it is important to use an adequate amount of polish at all times. Running the prophylaxis cup without paste is not only inefficient; it may also overheat the tooth.

As with scaling, every mm² of tooth surface should be polished. Slight pressure must be placed down onto the tooth to flare the edges of the prophylaxis cup so as to polish the subgingival areas. (Figure 9) One tooth may be polished for a maximum of five seconds at a time, to avoid overheating.

Step 7: Sulcal lavage

During the cleaning and polishing steps, debris such as calculus and prophylaxis paste (some of which is bacteria laden) accumulates in the gingival sulcus (or periodontal pockets). The presence of these substances allows for continued infection and inflammation, and therefore a gentle lavage of the sulcus is strongly recommended to improve healing. Sulcal lavage is performed with a small (22-25) gauge blunt-ended cannula. The cannula is placed gently into the sulcus and the solution injected while slowly moving along the arcades.

Sterile saline can be used as a lavage solution, but most dentists favor a 0.12% Chlorhexidine solution. (Jahn CA 2006)

Step 8: Periodontal probing, oral evaluation, and dental charting

This is a critically important step of a complete dental prophylaxis, but is unfortunately often poorly performed or completely omitted. The entire oral cavity must be systematically evaluated using both visual and tactile senses.

The periodontal evaluation should begin with measuring pocket depth. The only accurate method for detecting and measuring periodontal pockets is with a periodontal probe, as pockets are not always diagnosed by radiographs. (Carranza FA & Takei HH 2006; Tetradis S et al 2006, Niemiec BA 2010, Niemiec BA 2013, Niemiec BA 2011)

The periodontal evaluation should be initiated at the first incisor of one of the quadrants. The measurements are then continued distally one tooth at a time. Starting at midline and moving systematically distal in this fashion will decrease the chance of a tooth being skipped. Periodontal probing is performed by gently inserting the probe into the pocket until it stops and

then slowly “walking” the instrument around the tooth (Figure 10). (Carranza FA & Takei HH 2006; Niemiec BA 2008; Bellows J 2004) Depth measurements should be taken at six spots around every tooth. (Carranza FA & Takei HH 2006) The normal sulcal depth in dogs is 0-3 mm, and in cats is 0-0.5 mm. (Wiggs RB & Lobprise HB 1997; Debowes LJ 2010)

All abnormal findings must be recorded on the dental chart. Dental charting is easier and more efficient if performed 4-handed. (Huffman LJ 2010) This means that one person evaluates the mouth and calls out the findings of pathology to the assistant who records it on the chart. Using the modified Triadan system will also greatly increase efficiency of this step.

The modified Triadan system uses numbers to identify the teeth. (Floyd MR 1991; Huffman LJ 2010) First, each quadrant is numbered starting with the maxillary right quadrant as the 100 series. This progresses clockwise so that the maxillary left is 200, mandibular left is 300, and the mandibular right is the 400 series. Next, starting at the rostral midline, the teeth are counted distally starting with the first incisor which is tooth 01. The canines are always number 04 and the first molars are 09. For example, the maxillary left fourth premolar is tooth 208. This has been extrapolated from the fact that the complete dentition of the ancestral carnivore has been determined by anatomists to consist of each quadrant containing 3 incisors, 1 canine tooth, 4 premolars and 3 molars.

It is important that dental charts be of sufficient size to allow for accurate placement of pathology. (see oral exam section).

Step 10: Dental radiographs

When available, dental radiographs should be taken at a minimum of every area of pathology noted on dental exam. (See oral exam section.) This includes any periodontal pocket which is larger than normal, fractured or chipped teeth, masses, swellings, or missing teeth. In addition, numerous studies support full mouth radiographs on all dental patients to further eliminate missed pathology. (Tsubawa AJ & Verstraete FJ 2000; Verstraete FJ et al 1998 (a & b))

Step 11: Treatment planning

In this step, the practitioner uses all available information (visual, tactile, and radiographic findings) to determine appropriate therapy. It is important to consider overall patient health, the owner’s interest and willingness to perform homecare, and all necessary follow-up. (Niemiec BA 2008)

It is very important to note that if a patient requires extensive treatment that would entail a lengthy anesthesia, or if the practitioner would be unduly rushed, rescheduling the remainder of the dental work is definitely an acceptable alternative. The two parameters which directly affect long-term morbidity and mortality in anesthetized patients are hypothermia and hypotension, (Torossian A 2008, Brodbelt DC 2008) which become more pronounced with extended anesthesia time. In fact, anesthetic length has been shown to increase the complication rate in both humans and animals. (Tiret L et al 1986; Brodbelt DC 2008) (See anesthesia section).

Step 12 (optional): Application of a dental sealant

There are 2 commercially available sealants to prevent the re-attachment of plaque and calculus after dental cleaning. One wax based sealer which changes the electrostatic charge of the teeth has been clinically proven to decrease plaque and calculus (Gengler WR 2002). Following a prophylaxis, the teeth are dried and the product is then applied according to the manufacturer's directions. Continued applications are performed by the client at home on a weekly basis. The other, a resin sealant is applied subgingivally with a brush that uses polymer technology to prevent plaque extending subgingivally. It has been reported to decrease plaque and calculus for at least 30 days. (Sitzman C 2013)

Key Points:

- A complete dental prophylaxis is an involved procedure with numerous steps.
- All dental prophylactic procedures must be performed under general anesthesia.
- Each step must be properly performed to achieve a positive outcome.
- Sufficient time must be allotted for the procedure to have significant clinical benefit.
- Subgingival scaling is the most important step of a prophylaxis.
- A complete oral exam and charting is a critical part of the procedure.

References:

Niemiec BA (2013) *Veterinary Periodontology*. Ames, Wiley Blackwell.

Bellows J (2010) Treatment of Periodontal Disease. In *Feline Dentistry: Oral Assessment, Treatment, and Preventative Care*. Ames, Iowa, Wiley-Blackwell publishing, PP 181-95.

Colmery B (2005) The gold standard of veterinary oral health care, in Holmstrom SE (ed) *Veterinary clinics of North America*. 35(4): pp 781-7.

Niemiec BA (2003) Professional Teeth Cleaning. *J Vet Dent*. 2003, 20(3): 175-80.

Bellows J (2004) Equipping the Dental Practice. In: *Small Animal Dental Equipment, Materials, and Techniques, a Primer*. Blackwell, pp. 13-55.

Holmstrom SE, Frost P, Eisner ER (2002) Dental Prophylaxis and periodontal disease stages, in *Veterinary Dental Techniques*, (ed 3). Philadelphia, PA, Saunders, pp 175-232.

Bellows J (2004) Periodontal equipment, Materials, and Techniques. In: *Small Animal Dental Equipment, Materials, and Techniques, a Primer*. Blackwell, 2004, pp. 115-73.

Holmstrom SE, Frost P, Eisner ER (2002) Dental Prophylaxis and periodontal disease stages, in *Veterinary Dental Techniques*, (ed 3). Philadelphia, PA, Saunders, pp 175-232.

Wiggs RB, Lobprise HB: (1997) Periodontology, in Veterinary Dentistry, Principals and Practice. Philadelphia, PA, Lippincott – Raven, pp 186-231.

Huffman LJ: Oral examination. In: Small Animal dental, oral and maxillofacial disease, A color handbook (Niemiec BA ed.). London, Manson, 2010, pp39-61.

Holmstrom SE, Frost P, Eisner ER (1998) Periodontal Therapy and Surgery. in Veterinary Dental Techniques, (ed 2). Philadelphia, PA, Saunders, 1998, pp 167-213.

Joubert KE (2007) Pre-anesthetic screening of geriatric dogs. J S Afro Vet Assoc;78(1):31-5.

Holmstrom SE, Bellows J, Juriga S, Knutson K, Niemiec BA, Perrone J; American Veterinary Dental College.. 2013 AAHA dental care guidelines for dogs and cats. J am Anim Hosp Assoc. 2013 Mar-Apr;49(2):75-82.

Szymańska J.(2007) Dental bioaerosol as an occupational hazard in a dentist's workplace. Ann Agric Environ Med.;14(2):203-7.

Harrel SK. (2004) Airborne spread of disease--the implications for dentistry. J Calif Dent Assoc. 32(11):901-6.

Pederson ED, Stone ME, Ragain JC Jr, Smack (2002) JW. Waterline biofilm and the dental treatment facility: a review. Gen Dent;50(2):190-5

Shearer BJ (1996) Biofilm and the dental office. J Am Dent Assoc. 127:181-9.

Meiller TF, Depaola LG, Kelley JI, Baqui AA, Turng BF, Falkler WA. (1999) Dental unit waterlines: biofilms, disinfection and recurrence. J Am Dent Assoc. 130(1):65-72.

Wirthlin MR, Marshall GW Jr, Rowland RW. (2003) Formation and decontamination of biofilms in dental unit waterlines. J Periodontol. 74(11):1595-609.

Pattison AM, Pattison GL: (2006) Scaling and root planing, in Carranza's Clinical Periodontology. St. Louis, Mo, WB Saunders, pp 749-97

Harrel SK, Barnes JB, Rivera-Hidalgo F (1998) Aerosol and splatter contamination from the operative site during ultrasonic scaling. J Am Dent Assoc. 129:1241.

Holmstrom SE, Frost P, Eisner ER: (1998) Ergonomics and general health safety in the dental workplace. in Veterinary Dental Techniques, (ed 2). Philadelphia, PA, Saunders, pp 497-506.

Bellows J (2004) The Dental Operatory. In: Small Animal Dental Equipment, Materials, and Techniques, a Primer. Blackwell, pp. 3-12.

Legnani P, Checchi L, Pelliccioni GA, D'Achille C. (1994) Atmospheric contamination during dental procedures. Quintessence Int. 25(6):435-9.

Osorio R, Toledano M, Liébana J, Rosales JI, Lozano JA. (1995) Environmental microbial contamination. Pilot study in a dental surgery. *Int Dent J.* 45(6):352-7.

Leggat PA, Kedjarune U.(2001) Bacterial aerosols in the dental clinic: a review. *Int Dent J.*51(1):39-44, 2001.

Al Maghlouth A, Al Yousef Y, Al-Bagieh NH.(2007) Qualitative and quantitative analysis of microbial aerosols in selected areas within the College of Dentistry, King Saud University. *Quintessence Int.* 2007 May;38(5): e222-8.

Lafaurie GI, Mayorga-Fayad I, Torres MF, Castillo DM, Aya MR, Barón A, Hurtado PA.(2007) Periodontopathic microorganisms in peripheric blood after scaling and root planing. *J Clin Periodontol.* 34(10):873-9.

Fornier L, Larsen T, Kilian M, Holmstrup P.(2006) Incidence of bacteremia after chewing, tooth brushing and scaling in individuals with periodontal inflammation. *J Clin Periodontol.* 33(6):401-7.

Daly CG, Mitchell DH, Highfield JE, Grossberg DE, Stewart D.(2001) Bacteremia due to periodontal probing: a clinical and microbiological investigation. *J Periodontol.*72(2):210-4.

Fine DH, Yip J, Furgang D, Barnett ML, Olshan AM, Vincent J. (1993) Reducing bacteria in dental aerosols: pre-procedural use of an antiseptic mouth rinse. *J Am Dent Assoc.* 124(5):56-8

Jahn CA (2006) Sonic and ultrasonic instrumentation, in Carranza's Clinical Periodontology. St. Louis, Mo, WB Saunders, pp 828-835

Holmstrom SE, Frost P, Eisner ER: (2002) Dental Equipment and Care. in *Veterinary Dental Techniques*, (ed 3). Philadelphia, PA, Saunders, pp 31-106.

Wiggs RB, Lobprise HB: (1997) Dental Equipment, in *Veterinary Dentistry, Principles and Practice*. Philadelphia, PA, Lippincott – Raven pp 1-28

Felver B, King DC, Lea SC, Price GJ, Damien Walmsley A. (2009) Cavitation occurrence around ultrasonic dental scalers. *Ultrason Sonochem.* 16(5):692-7.

Arabaci T, Çiçek Y, Canakçi CF: (2007) Sonic and ultrasonic scalers in periodontal treatment: a review. *International Journal of Dental Hygiene*:5(1):2–12.

Debowes LJ (2010) Problems with the gingiva. In: *Small Animal dental, oral and maxillofacial disease, A color handbook* (Niemic BA ed.). London, Manson, pp159 – 181.

Nicoll BK, Peters RJ. (1998) Heat generation during ultrasonic instrumentation of dentin as affected by different irrigation methods. *J Periodontol.* 69(8):884-8.

Brine EJ, Marretta SM, Pijanowski GJ, Siegel AM.(2000) Comparison of the effects of four different power scalers on enamel tooth surface in the dog. *J Vet Dent.* 2000 Mar;17(1):17-21.

Vérez-Fraguela JL, Vives Vallés MA, Ezquerro Calvo LJ. (2000) Effects of ultrasonic dental scaling on pulp vitality in dogs: an experimental study. *J Vet Dent.* 17(2):75-9.

Westfelt E, Rylander H, Dahlen G, Lindhe J: (1998) The effect of supragingival plaque control on the progression of advanced periodontal disease. *J Clin Periodontol.* 25(7): 536-41.

Kocher T, Rühling A, Momsen H, Plagmann HC (1997) . Effectiveness of subgingival instrumentation with power-driven instruments in the hands of experienced and inexperienced operators. A study on manikins. *J Clin Periodontol.*24(7):498-504.

Kocher T, Riedel D, Plagmann HC. (1997) Debridement by operators with varying degrees of experience: a comparative study on manikins. *Quintessence Int.* 28(3):191-6.

Silness J: (1980) Fixed prosthodontics and periodontal health. *Dent Clin North Am.* 24(2):317-29.

Berglundh T, Gotfredsen K, Zitzmann NU, Lang NP, Lindhe J.(2007) Spontaneous progression of ligature induced peri-implantitis at implants with different surface roughness: an experimental study in dogs. *Clin Oral Implants Res.* 18(5):655-61.

Fichtel T, Chra M, Langerova E, Biberaur G, Vla in M: (2008) Observations on the effects of scaling and polishing methods on enamel. *J Vet Dent.* 25(4): 231-5.

Jahn CA (2006) Supragingival and subgingival irrigation. in Carranza's Clinical Periodontology. St. Louis, Mo, WB Saunders, pp 836-844.

Tetradis S, Carranza FA, Fazio RC, Takei HH (2006) Radiographic aids in the diagnosis of periodontal disease, in Carranza's Clinical Periodontology. St. Louis, Mo, WB Saunders, pp 561-578

Niemiec BA (2010) Veterinary dental radiology. In: Small Animal dental, oral and maxillofacial disease, A color handbook (Niemiec BA ed.). London, Manson, pp 63-87.

Niemiec BA (2011) The Importance of Dental Radiology. *Eur J Comp Anim Pract.* 20(3): 219-29.

Carranza FA, Takei HH (2006) Clinical diagnosis, in Carranza's Clinical Periodontology. St. Louis, Mo, WB Saunders, pp 540-60.

Wiggs RB, Lobprise HB (1997) Oral exam and diagnosis, in *Veterinary Dentistry, Principals and Practice.* Philadelphia, PA, Lippincott – Raven, pp 87-103

Tsugawa AJ, Verstraete FJ.(2000) How to obtain and interpret periodontal radiographs in dogs. *Clin Tech Small Anim Pract* 15(4): 204-10.

Verstraete FJ, Kass PH, Terpak CH. (1998) Diagnostic value of full-mouth radiography in cats. *Am J Vet Res.* 59(6):692-5.

Verstraete FJ, Kass PH, Terpak CH.(1998) Diagnostic value of full-mouth radiography in dogs. *Am J Vet Res*;59(6):686-91.

Torossian A.(2008) Thermal management during anaesthesia and thermoregulation standards for the prevention of inadvertent perioperative hypothermia. *Best Pract Res Clin Anaesthesiol.* 22(4):659-68.

Brodbelt, D.C, Blissitt, K.J., Hammond, R.A., et al. (2008) The risk of death: the confidential enquiry into perioperative small animal fatalities. *Veterinary Anaesthesia and Analgesia.* 35, 365-373.

Tiret L, Desmonts JM, Hatton F, Vourch G.(1986) Complications associated with anaesthesia--a prospective survey in France. *Can Anaesth Soc J.* 33:336-44.

Gengler WR, Kunkle BN, Romano D, Larsen D: (2003) Evaluation of a barrier sealant in dogs. *J Vet Dent* 22(3): 157-9.

Sitzman C (2013) Evaluation of a hydrophilic gingival dental sealant in beagle dogs. *J Vet Dent.*30(3):150-5.

Floyd MR (1991) The modified Triadan system: Nomenclature for veterinary dentistry. *Journal of Veterinary Dentistry* 8(4): 18-19.

Dental Homecare

Introduction

Homecare is a critical aspect of periodontal care. Bacterial plaque attaches to the tooth surface within twenty-four hours of cleaning. (Wiggs RB & Lobprise HB 1997, Boyce EN et al 1995) In addition, without homecare, gingival infection/inflammation quickly returns. (Fiorellini JP et al 2006; Rober M 2007; Corba NH 1986) Periodontal pockets become reinfected within two weeks of a prophylaxis if homecare is not performed and pocket depth returns to pre-treatment depths within 6 weeks of therapy. (Rober M 2007) Furthermore, it was found in a human review that professional cleanings were of little value without homecare (Needleman I *et al.* 2005). In fact, one consensus review emphatically states “Forty years of experimental research, clinical trials, and demonstration projects in different geographical and social settings have confirmed that effective removal of dental plaque is essential to dental and periodontal health throughout life”. (Quintessence 1998).

Homecare discussion/instructions

The benefits of routine homecare must be conveyed to each client on a regular basis. Dental care (including homecare) should be discussed with the client on their first visit to the practice, which is often the well puppy/kitten or vaccination visit, and should come from the whole staff. (Wiggs RB & Lobprise HB 1997) Early institution of homecare not only leads to the greatest benefit, it also makes training easier.

Goals of home plaque control

The primary goal of homecare is to reduce the amount of bacterial plaque on the teeth. (Perry DA 2006) This in turn should decrease the level of gingival inflammation and ultimately periodontal disease.

It is important to note that supragingival plaque and calculus has little to no effect on periodontal disease. It is the plaque at and below the gumline that creates inflammation and initiates periodontal disease. (Westfelt E et al 1998, Niemiec BA 2008) Keep this in mind when determining which homecare methods to recommend. Information on the suitability of different methods for marginal and subgingival plaque control is covered along with their descriptions below.

Brushing is by far the most effective means to mechanically remove the plaque. (Hale FA 2003) Chew based products can be effective if properly formulated, however, oral sprays, rinses, and water additives are generally an insufficient. This is due to the tenacity with which plaque adheres to the teeth, and the increased resistance of the plaque biofilm to antiseptics (which is reported to be up to 500,000 times that of singular bacteria. (Williams JE 1995; Quirynen M et al 2006)

Types of homecare

The two major types of home plaque control are active and passive. Both types can be effective if performed correctly and consistently, but active homecare is currently the gold standard. Active homecare involves the participation of the pet's owner, such as brushing or rinsing. Passive methods are typically based on chewing behaviours via treats or specially formulated diets. It has been shown that active homecare is most effective on the rostral teeth (incisors and canines). (Capik I 2007) In contrast, passive homecare (chew based) is more effective on the caudal teeth (premolars and molars) (Capik I 2007; Bjone S et al 2007) This difference is intuitive because the front teeth are easier for clients to access, while passive homecare is more effective on the caudal teeth where chewing occurs.

Active homecare

Tooth brushing

When properly performed, tooth brushing has been proven to be the most effective means of plaque control. (Hale FA 2003) Therefore, it should be the goal of all veterinarians to promote tooth brushing for their patients by educating their clients.

Materials and methods for tooth brushing

Brushes: The only critical piece of equipment is a tooth brush. There are numerous veterinary brushes available, and a proper brush should be selected based on patient size. Double and triple sided as well as circular feline brushes are effective products and should be considered depending on patient size and temperament. Gauze and washcloths are generally not recommended due to their inability to clean below the gumline. (Holmstrom SE et al 1998)

In addition to veterinary products, soft human tooth brushes with nylon filaments may be substituted. A child's toothbrush is often the correct size for small patients, and may be more effective than the larger veterinary version. An infant brush may work best for toy breed dogs, cats, or juvenile patients.

Mechanized (sonic and especially rotary) brushes have been shown to be superior to traditional brushes in human studies. (Moritis K et al 2008; Deery C et al 2004) In addition to the numerous human product options, there is currently a mechanized veterinary brush available. The only negative aspect to these brushes is that the movement/vibration of these instruments can feel awkward and/or may scare the patients. (Holmstrom SE et al 1998) Therefore, mechanized brushes should only be used patients with accepting temperament.

Pastes

There are a number of veterinary toothpastes available, which greatly increase the acceptance of the toothbrush by the pet. Toothpastes may also contain a calcium chelator which has been shown to decrease the level of calculus deposits on the teeth. (Hennet P et al 2007; Liu H et al 2002) It is important to note however, that calculus itself is largely non-pathogenic. As such, the paste is not a significant player in the reduction of plaque and gingivitis. The mechanical removal of plaque by the movement of the brush/instrument is the key to control. (Hale FA 2003) Human tooth pastes are not recommended as they contain detergents or fluoride which may cause gastric upset or fluorosis if swallowed, and products such as baking soda (sodium bicarbonate) may change urinary pH. (Niemiec BA 2008, Wiggs RB & Lobprise HB 1997)

Antimicrobial preparations (see chlorhexidine rinses below) are also available. These products will improve plaque and gingivitis control beyond that of pastes when used with brushing, and therefore should be considered instead of toothpaste in high-risk patients and in cases of established periodontal disease. (Eaton KA et al 1997. Hennes P 2002)

Brushing technique

To safely and effectively initiate tooth brushing in veterinary patients, the following training is recommended. Keep in mind, the ideal technique may only be possible in the most tractable patients. Clients should be encouraged to work toward this level of care, but to accept any success as valuable. Forcing homecare on a patient is counterproductive and may damage the client-animal bond (Niemi BA 2013, Wiggs RB & Lobprise HB 1997).

The keys to compliance with brushing can be stated as follows.

1. **Start early:** young patients are more amenable to training.
2. **Go slow:** Start with just holding the mouth and then progress to a finger and finally start brushing slowly.
3. **Be consistent:** make this a learned behaviour.
4. **Make it positive:** using food, treats, or playtime as a reward will greatly increase the likelihood of acceptance.
5. **Discuss the risks:** Handling animals near their mouths can potentially put the owner at risk of being bitten. Always counsel owners of this risk as part of the tooth brushing discussion.

Proper tooth brushing technique begins with the brush held at a 45-degree angle to the long axis of the tooth. The brush is then placed at the gingival margin and moved along the arcades utilizing a rotary motion. The buccal surfaces of the teeth are the most accessible and fortunately are the most important, as these are the surfaces which generally have higher levels of calculus deposition. Make sure to counsel owners not to attempt to open the pet's mouth on initiation of this procedure. Most veterinary patients greatly dislike their mouth being forced open, and this approach may result in increased resistance. Instead, clients should be instructed to begin by effectively brushing the buccal surfaces with the mouth closed. The distal teeth can be accessed by gently inserting the brush inside the cheek to reach these teeth, relying on tactile feel and experience to ensure proper positioning. If the patient is amenable, the client should progress to caring for the palatal/lingual surfaces of the teeth. To open the mouth, begin by placing the thumb of the non-dominant hand behind the lower canines. This is the safest place in the mouth to rest the finger.

Regarding the frequency of brushing, once a day is ideal, as this level of care is required to stay ahead of plaque formation. Furthermore, every other day brushing was not found to be effective at gingivitis control. (Gorrel C & Rawlings JM 1996) Three days a week is considered the minimum frequency for patients in good oral health. Tromp JA et al 1986) Brushing once a week is not considered sufficient to maintain good oral health. For patients with established periodontal disease, daily brushing is required to maintain oral health, and twice daily may be recommended. (Gorrel C & Rawlings JM 1996; Corba NH et al 1986 a & b; Tromp JA et al 1986) Finally, it should be noted that consistency with homecare is critical. If brushing is suspended for as little as a month, the level of gingival inflammation will return to the same level as patients with no therapy. (Ingham KE & Gorrel C 2001)

Antiseptic rinses

The other option for active homecare is the application of antiseptic/antiplaque solutions. The traditional antiseptic of choice is chlorhexidine. Outside of *Pseudomonas spp.*, there is no known bacterial resistance to this product, and it is very safe. (Robinson JG 1995 Roudebush P et al 2005) Chlorhexidine has been shown in numerous studies to decrease gingivitis if applied consistently over time. (Hamp SE et al 1973 (a & b); Hennes P 2002, Tepe JH et al 1983) Chlorhexidine reportedly has a quick onset and minimal systemic uptake, making it an excellent choice for oral antiseptics. (Salas Campos L et al 2000) An additional benefit of this product is that it maintains antiseptic effects for up to 7 hours after application. (Cousido MC et al 2009; Bonesvoll P 1977) One concern with the use of these products is the lack of palatability, which may hinder homecare efforts. (Holmstrom et al 1998)

Proper application of these products requires only a small amount of the solution be used. Ideally, the rinse should be directly applied to the surface of the teeth and gingiva. In most cases, however, getting the solution between the cheek and teeth is the best the client can achieve.

An additional option for active home oral care is the use of soluble zinc salts. Studies show that these products can be effective in decreasing viable plaque biomass. (Wolinsky LE et al 2000) One veterinary labelled oral zinc ascorbate gel has been proven to decrease plaque and gingivitis, (Clarke DE 2001) and provides the additional advantage of being tasteless, which should improve acceptance. Furthermore, this product also contains ascorbic acid which has been shown to support/induce collagen synthesis, which may improve healing following dental scaling and/or oral surgery. (Pinnel SR et al 1987; Murad S et al 1981)

Barrier Sealants

A final option for active homecare is the application of a commercially available barrier sealant. One function by changing the electrostatic charge of the teeth and creates a hydrophobic surface which is designed to prevent plaque attachment. This has been shown to decrease the accumulation of plaque and calculus. (Homola AM et al 1999; Gengler WR 2005) An additional sealant has been reported to decrease plaque and calculus for at least 30 days. (Sitzman C 2013)

Passive Homecare

Since passive homecare requires minimal effort by the owner, compliance is more likely. This is important since long term consistency is the key factor in the efficacy of home dental care (Ingham & Gorrel, 2001). It has been shown that the compliance rate with tooth brushing with *highly motivated* pet owners is only around 50% after 6 months (Miller & Harvey, 1994). In fact, one study showed that passive homecare may be superior to active homecare simply due to the fact that it is actually performed (Vrieling et al., 2005).

Pet foods, supplements and treats are often used as adjuncts to or substitutes for tooth brushing for home plaque control. These products and techniques should always be used in combination with professional dental care. These methods are considered “passive” forms of homecare, meaning the client is not “actively” removing the plaque or applying rinses or gels (Niemiec, 2013).

Dental foods or treats may help as an adjunct for control of plaque and calculus. It is critical to remember that tartar is generally non-pathogenic and plaque control above the gingival margin does not improve periodontal disease (Westfelt et al., 1998, DeBowes, 2010, Niemiec, 2008). As an example, wild carnivores have reportedly had significantly less calculus on their teeth but had a similar level of periodontal disease to their domestic counterparts (Verstraete et al., 1996; Clarke & Cameron, 1998; Steenkamp & Gorrel, 1999). Furthermore, one human study found that clinical attachment gains were not related to the degree of residual calculus (Sherman, 1990). Therefore, when making recommendations to our clients we must look for products which clean down to the gum line for subgingival effect (see below).

Pet Food Regulations and the Veterinary Oral Health Council (VOHC)

Many diets and treats claim that they improve dental health. These claims may include cleans teeth, freshens breath, promotes healthy gums, or aids in prevention of periodontal disease (Logan et al., 2006). While by labelling regulation, claims should be true, some can be too vague to come under the regulations and therefore may have little evidence as to their effectiveness. The Association of American Feed Control Officials (AAFCO) and the European Pet Food Industry Federation (FEDIAF) do not allow claims for prevention of treatment of dental (or any other) disease for pet foods or treats (AAFCO.org; FEDIAF.org), although AAFCO does discuss claims for dental tartar (AAFCO, 2010).

The best way to determine if a product is effective is to look for published-peer reviewed research which validates the claims. If this is available, you can recommend it as effective, so make sure to ask representatives for study information. However, this research will take a bit of effort, therefore a valuable tool for busy practitioners is the Veterinary Oral Health Council (VOHC) (vohc.org). The VOHC provides an objective means of recognising commercially available products that meet pre-set standards of effectiveness in controlling accumulation of dental plaque and calculus (tartar) in dogs and cats (Harvey, 2003). If a pet food or treat is approved by the VOHC, there is reasonable assurance that it is effective in preventing or decreasing plaque or calculus. However, as stated above, published studies and the VOHC only provide whole tooth scoring, which may or may not actually improve periodontal status. The VOHC is a non-regulatory agency which includes representatives from professional dental colleges as well as allied veterinary groups. The VOHC council consists of nine veterinary dentists and dental scientists with experience of scientific protocols and study design, and a non-voting Director.

The VOHC does not test products; rather they establish the protocols and standards and review the research. The research is performed by the company itself and a detailed report of the testing submitted for review. The VOHC provides independent and objective reviews of the tests of products submitted. Claims may be based on mechanical or chemical means of improving dental health. The VOHC awards a Seal of Acceptance for two categories: helps control plaque and helps control tartar. Furthermore, to obtain VOHC approval, the product must also be a safe consistency for the patient to chew and not damage the teeth.

Pet food effects on oral health

Passive homecare alone will not be able to maintain clinically healthy gingiva and is only a part of the plaque control regimen. The downfall of most chew-based products is that pets typically do not chew with the entire mouth and therefore areas will be missed. Passive homecare is most effective on the chewing teeth, and in contrast, active homecare is superior for the incisor and canine teeth (Capik, 2007). Therefore, a combination of active and passive homecare is best.

Wet, dry and homemade diets

The diet can affect the oral environment via maintenance of tissue integrity, metabolism of plaque bacteria, effects on salivary flow and composition, and the effects of contact on the tooth and oral surfaces (Logan & Allen, 2003). A common conception in small animal practice is that feeding dry pet foods decreases plaque and calculus and canned foods promote plaque formation. This is because the crunching action of biting into a hard kibble should clean the teeth. Further, dry food leaves less residue in the mouth for oral bacteria to feed on and so plaque accumulates at a slower rate. Despite that, many animals fed on commercial dry diets still have heavy plaque and calculus accumulations and periodontal disease (Logan et al., 2006; Harvey et al., 1996). In one study, dogs and cats eating soft foods did have more plaque and gingivitis than animals eating a more fibrous food (Watson, 1994). In other studies, moist foods have shown a similar effect to a typical dry food on plaque and calculus accumulation (Boyce & Logan 1994; Harvey et al., 1996). Finally, standard dry foods break apart at the incisal edge of the teeth, providing minimal to no cleaning at the gingival margin, which is where it matters (Niemiec, 2008, Westfelt, et al., 1998; Niemiec, 2013). A study comparing home prepared foods vs commercial wet and/or dry foods showed that feeding a home prepared diet increased the probability of oral health problems in cats. There was a significant benefit of feeding commercial food compared to home prepared when at least part of the diet was a dry pet food for dogs and cats (Buckley et al., 2011). Another study showed an improvement in periodontal disease, dental deposits (tartar) and decreased prevalence of lymphadenopathy in cats fed a dry food compared to a soft or homemade food (Gawor et al 2006).

For dry diets, the kibble size, texture and composition significantly affect the effect of the kibble on the mouth. The effects include alteration of plaque bacteria, cleaning of the tooth, and maintenance of tissue integrity. Dietary fibre also exercises the gums, promotes gingival keratinization and has some teeth cleaning effects (Logan, 2006). Dietary fibre can affect plaque and calculus formation; however, as the pet bites into most standard kibbles they may shatter and crumble, which provides little to no mechanical cleaning (Logan et al., 2010).

Dental diets

Several commercial dry diets for adult dogs and cats have been formulated with increased oral cleaning ability compared with standard pet foods. The mechanical action of these foods is provided by a kibble with a larger size and texture which promotes chewing and maximizes contact with the teeth. Foods with the right shape, size and physical structure can provide plaque, stain and calculus control (Logan, 2006; Jensen et al 1995). The type of fibre in the dental diets is also thought to exercise the gums, promote gingival keratinisation and clean the teeth (Logan et al 2010). One important point is that even though these products may decrease plaque and

calculus, they are typically most effective on the areas around the cusp tips and not at the gingival margin (Stookey & Warrick, 2005). If the diet is properly designed, the teeth sink into the kibble before it splits. As the tooth is penetrating the kibble, the fibre in the food gently abrades the tooth surface, thereby removing plaque (Jensen, et al., 1995). Studies have shown that some dental foods can provide significant plaque, calculus and stain control in cats and dogs, especially when used with dental prophylaxis (Logan et al., 2002; Jensen et al., JVD 1995; Theyse et al., 2003). Currently, only one diet has published evidence to actually have a positive effect on gingival inflammation. A six-month study comparing feeding this dental diet to a typical maintenance diet revealed approximately a 33% reduction of plaque and gingival inflammation with dental diet (Logan et al., 2002). These diets are usually high-fibre maintenance diets for adult animals, which would not be appropriate to support growth, gestation/lactation, or any pet with a high calorie requirement. Dental diets are intended to be fed as the main food source. Research has found that the best results were obtained when a dental diet is the main food, but that there was still a measurable but declining benefit when a prescription diet was fed as 75%, 50% and even 25% of the total calorie intake. Using a dental diet simply as a treat will not meet expectations for the product (Hale, 2003).

Dental treats

Plain baked biscuit treats and chew toys (e.g. string and rope toys) have not shown to be of benefit for the prevention of periodontitis (Roudebush et al., 2005). Dental chews made from a compressed wheat, cellulose incorporated into treats, and rawhide chews have good evidence for efficacy (Roudebush et al., 2005; Beynen et al., 2011; Stookey., 2009; Hooijberg et al., 2015). Some have received VOHC approval, although there are no dental chews with a VOHC seal of approval for plaque reduction in cats (vohc.org). Of the available products, only a handful have been clinically proven to decrease gingivitis (Gorrel & Bierer, 1999; Stookey,2009; Mariani et al., 2009; Gorrel et al., 1999; Warrick et al., 2001; Brown & McGenity, 2005).

As above, the canine teeth and incisors are not effectively cleaned by chew based products. A new entry into this area contains an anti-plaque agent (delmopinol), which is spread throughout the mouth and may provide positive effects on these teeth. This product also has a consistency which allows the teeth to chew through the entire treat, thus cleaning to the gingival margin. Finally, there is evidence that this product helps control halitosis

Risks of dental chews

While uncommon, esophageal foreign body obstruction due to dental chews has been reported in dogs, especially in smaller breeds (Leib and Sartow, 2008). In addition, there have been two case reports of tongue entrapment by a chew toys with a round opening (Rubio et al., 2010). Some dental chews are relatively high calorie, and can contribute to weight gain and obesity if the calorie content is not taken into account in the pet's overall consumption. Excess consumption of chews can also unbalance the diet as they are usually not formulated to be a complete source of nutrients.

There are several reports of rawhide chews being associated with the onset of Fanconi's syndrome in dogs (Hooper & Roberts, 2011; Igase et al., 2015; Major et al., 2014). Those treats which can be chewed and swallowed may also result in gastrointestinal upset in some pets.

Tooth fractures are a risk for very hard dental treats such as antlers, hooves, or nylon bones. The British Veterinary Dental Association notes that "Many veterinary dentists are reporting that they are seeing fractured teeth as a direct result of chewing on antler bars. In particular, the maxillary fourth premolar tooth" (BVDA). Recommendations of techniques that can be utilized to evaluate for excessive treat hardness excess include being able to dent the treat with a fingernail, or being willing to be hit on the knee with the treat (Hale, 2003).

Additives

Some diets and treats contain antiseptics or additives to retard or inhibit plaque or calculus accumulation. Sodium hexametaphosphate (HMP) forms soluble complexes with cations (e.g. calcium) and decreases the amount available for forming calculus. (Stookey & Warrick, 2005; White et al., 2002; Hennes, 2007). Adding HMP to a dry diet decreased calculus in dogs by nearly 80% (Stookey et al., 1995), however, remember that tartar is not a major player in the development of gum disease. In addition, studies have shown no difference in plaque or calculus when HMP-coated biscuits were fed to dogs for 3 weeks (Logan et al., 2010, Stookey et al., 1996). Finally, the amount of sodium and phosphorous in HMP may be a concern for animals with overt or subclinical renal disease.

The addition of antiseptics to treats or water additives are an attractive method for treating periodontal disease. However, as previously noted, plaque bacteria has resistance to concentrations of antiseptics up to 500,000 times of that which would kill singular bacteria. (Williams, 1995). Therefore, while the substance may have a positive effect on singular bacteria, in most cases it is insufficient for plaque reduction.

Chlorhexidine has been proven to have efficacy as an oral antiseptic which may reduce plaque, especially as a perioperative or pre-prophylaxis rinse (Roudebush et al., 2005) although it may enhance mineralisation of plaque to calculus (Hale 2003). However, sufficient contact time is likely not achieved when using as a rinse. In addition, reports of efficacy do vary and the addition of chlorhexidine has not been found to increase the efficacy of a rawhide chew (Brown and McGenity, 2005).

Enzyme systems may contain glucose oxidase and lactoperoxidase, lysozyme or lactoferrin (Logan et al, 2003). There is low grade evidence for efficacy in dogs and cats for oral anti-bacterial effects (Hale 2003).

Vitamin and mineral deficiencies

Deficiencies in vitamin A, C, D and E and the B vitamins folic acid, niacin, pantothenic acid and riboflavin have been associated with gingival disease (Logan et al., 2010). Diets deficient in calcium may result in nutritional secondary hyperparathyroidism, which can cause periodontal disease (Logan & Allen 2003). These vitamins and minerals are adequate in diets which meet

AAFCO or FEDIAF guidelines but can be deficient in diets which don't meet those guidelines, such as many homemade diets.

Natural diets and feeding raw bones

Proponents of feeding raw bones have claimed that this improves the cleanliness of teeth in pets. Further claims are sometimes made that feeding commercial pet food contributes to the high prevalence of periodontal disease in domesticated cats and dogs; however, a study in foxhounds fed raw carcasses, including raw bones, showed that they had varying degrees of periodontal disease as well as a high prevalence of tooth fractures (Robinson and Gorrel, 1997) The skulls of 29 African wild dogs eating a "natural diet", mostly wild antelope, also showed evidence of periodontal disease (41%), teeth wearing (83%) and fractured teeth (48%) (Steenkamp and Gorrel, 1999). A study in small feral cats on Marion Island (South Africa) which had been eating a variety of natural foods (mostly birds) showed periodontal disease in 61% of cats, although only 9% had evidence of calculus (Verstraete et al 1996). In a study in Australia of feral cats eating a mixed natural diet there was less calculus compared to domestic cats fed dry or canned commercial food, although again there was no difference in the prevalence of periodontal disease between the two groups (Clarke and Cameron, 1998). In a study on eight Beagle dogs fed cortical bone (bovine femur) there was an improvement in dental calculus, although no effect on plaque was reported. (Marx et al, 2016).

These studies show that feeding raw bones may confer some protection against dental calculus; however, there are currently no published studies that they are beneficial for periodontal disease. There is also the risk of fractured teeth and potentially of the spread of zoonotic disease (LeJeune and Hancock, 2001; Lenz et al, 2009).

Water additives

A study on the effects of a xylitol drinking water additive showed reduced plaque and calculus accumulation in cats (Clarke, 2006). Concerns about xylitol will limit the use of this ingredient, as it may cause hypoglycaemia. However, the concentration as supplied in veterinary products is low when used as the recommended dose. Another veterinary product has human studies which show that the active ingredients have some efficacy, but there is currently no peer reviewed evidence that support its use in veterinary patients. (Chapek CW et al 1995; Hamp SE & Emilson CG 1973)

Probiotics

Nitric oxide (NO), an important inflammatory mediator, has been shown to be increased in human periodontitis (Matejka et al, 1998; Lappin et al, 2000; Hirose et al, 2001) and agents blocking the production of NO or its effects might be therapeutically valuable (Paquette and Williams 2000). *Lactobacillus brevis* (*L brevis*) is a probiotic bacteria which contains high levels of arginine deiminase. High levels of arginine deiminase inhibit NO generation by competing with nitric oxide synthase for the same arginine substrate. Studies in humans showed topical application of probiotics containing *L brevis* decreased inflammatory mediators involved in periodontitis (Leraido et al, 2010). Studies using probiotics in treatment of periodontal disease in humans have shown improved gingival health, as measured by decreased gum bleeding. The probiotic strains used in these studies include *L. reuteri* strains, *L. brevis* (CD2), *L. casei* Shirota, *L. salivarius* WB21, and *Bacillus subtilis*. *L. reuteri* and *L. brevis* (Haukioja, 2010), Preliminary results of a study of topical *L brevis* CD2 in dogs showed a reduction of gingival inflammatory infiltrates (Vullo,2014),

Conclusions:

Homecare is a critical aspect of periodontal therapy, but it is often ignored. Early and consistent client education is the key to compliance. There are numerous options available, but tooth brushing remains the gold standard. While the common myth of dry food cleaning the teeth is appealing, standard dry foods do not appear to significantly decrease the risk of periodontitis. Dental diets or treats may confer some benefit and it is recommended to look for products that have published peer reviewed research and/or the VOHC seal of approval, especially for plaque. Products need to clean down to and below to the gingival margin. Feeding standard dry foods or raw bones may decrease dental calculus, but there is not much evidence for a decrease in the risk of periodontitis.

Key Points:

- Daily homecare is recommended since plaque accumulates in 24 hours.
- Without homecare, the efficacy of professional periodontal therapy is severely limited.
- Tooth brushing is the gold standard and is most effective on rostral teeth.
- Passive homecare methods may or may not be effective, and any provided benefit will be mainly on the caudal teeth.
- Standard dry dog food is not beneficial for oral health.
- A combination of active and passive methods is likely the best choice.

References:

www.AAFCO.org

Beynen A.C., Van Altena F., Visser E.A. (2010) Beneficial effect of a cellulose-containing chew treat on canine periodontal disease in a double-blind, placebo-controlled trial. *American Journal of Animal and Veterinary Science*. 5(3):192-195.

Boyce E.N., Logan E.I. (1994) Oral health assessment in dogs: Study design and results. *Journal of Veterinary Dentistry* 11: 64-74.

Brown W.Y. and McGenity P. (2005) Effective periodontal disease control using dental hygiene chews *Journal of Veterinary Dentistry* 22(1);15-19.

Buckley C., Colyer A., Skrzywanek M. et al. (2011) The impact of home-prepared diets and home oral hygiene on oral health in cats and dogs. *British Journal of Nutrition*; 106 Suppl 1(0):S124-S127.

<http://www.bvda.co.uk/position-statements>

Clarke D.E. (2006) Drinking water additive decreases plaque and calculus accumulation in cats. *Journal of Veterinary Dentistry*; 23(2):79-82.

Clarke D.R. and Cameron A. (1998) Relationship between diet, dental calculus and periodontal disease in domestic and feral cats in Australia. *Australian Veterinary Journal* 76(10):690-693.

Engelberg J. (1965) Local effect of diet on plaque formation and development of gingivitis in dogs. 3. Effect of hard and soft diets. *Odontologisk Revy* 16:31-41.

www. FEDIAF.org

Finney O., Logan E.I., Simone A.J., et al. (1996) Effects of diet on existing plaque, calculus and gingivitis in dogs. In: Proceedings. Tenth Annual Veterinary Dental Forum, Houston, TX, 1996: 143-146.

Gawor J.P., Reiter A.M., Jodkowska K, et al (2006) Influence of diet on oral health in cats and dogs. *Journal of Nutrition*. 136:2021S-2023S.

Hale F. (2003) Home care for the dental patient. Proceedings of Hill's European Symposium on Oral Care. Amsterdam 19th to 20th March 2003, pp50-59.

Harvey C.E. (2003) Veterinary Oral Health Care Council: What Do We Do? Proceedings of Hill's European Symposium on Oral Care. Amsterdam 19th to 20th March 2003. Pp27-33.

Harvey C.E., Shofer F.S., Laster L. (1996) Correlation of diet, other chewing activities and periodontal disease in North American client-owned dogs. *Journal of Veterinary Dentistry*; 13: 101-105.

Haukioja A. (2010) Probiotics and oral health. *European Journal of Dentistry* ;4(3):348-55.
Hirose M., Isihara K., Saito A., et al (2001) Expression of cytokines and inducible nitric oxide synthase in inflamed gingival tissue. *Journal of Periodontal Research*: 72:590-597.

Hooijberg E.H., Furman E., Leidinger J., et al (2015) Transient renal Fanconi syndrome in a Chihuahua exposed to Chinese chicken jerky treats. *Tierärztliche Praxis Kleintiere Heimtiere* 43(3):188-92.

Hooper A.N. and Roberts B.K. (2011) Fanconi syndrome in four non-basenji dogs exposed to chicken jerky treats. *Journal of the American Animal Hospital Association* 47(6):e178-87.

Horiuchi M., Yamamoto T., Tomofuji T., et al (2002) Tooth brushing promotes gingival fibroblast proliferation more effectively than removal of dental plaque. *Journal of Clinical Periodontology*. 29(9):791-795.

Igase M., Baba K., Shimokawa T., Miyama T.S, et al. (2015) Acquired Fanconi syndrome in a dog exposed to jerky treats in Japan. *Journal of Veterinary Medical Science*; 77(11):1507-10.

Jensen L., Logan E.I., Finney O., et al. (1995) Reduction in accumulation of plaque, stain and calculus in dogs by dietary means. *Journal of Veterinary Dentistry* 12: 161-163.

Lappin D.F., Kjeldsen M., Sander L., et al. (2000) Inducible nitric oxide synthase expression in periodontitis. *Journal of Periodontal Research* 35:369-373.

Leib M. and Sartor L.L. (2008) Esophageal foreign body obstruction caused by a dental chew treat in 31 dogs (2000-2006). *Journal of the American Veterinary Medical Association* 232(7):1021-1025.

LeJeune J.T. and Hancock D.D. (2001) Public health concerns associated with feeding raw meat diets to dogs. *Journal of the American Veterinary Medical Association* 219(9):1222-1225.

Lenz J., Joffe D., Kauffman M., Zhang Y., LeJeune J. (2009) Perceptions, practices, and consequences associated with foodborne pathogens and the feeding of raw meat to dogs. *Canadian Veterinary Journal* 50(6):637-43.

Lerairdo G., Bossù M., Tarantine D., et al. (2010) The arginine-deiminase enzymatic system of gingivitis: preliminary paediatric study. *Annali di Stomatologia* LIX:8-13.

Logan E.I. (2006) Dietary influences on periodontal health in dogs and cats. *Veterinary Clinics of North America, Small Animal Practice*. Ed Kirk CA and Bartges JW. 36 (6):1385-1402.

Logan E.L., Allen T.A., Debraekeleer A. (2003) Nutritional Support of the Dental Patient: An Overview. Proceedings of Hill's European Symposium on Oral Care. Amsterdam, 19th to 20th March, pp 66-75.

Logan E.I., Finney O., and Herrerren J.J. (2002) effects of a dental food on plaque accumulation and gingival health in dogs. *Journal of Veterinary Dentistry* 19(1):15-18.

Logan E.I., Wiggs R.B., Schert D., and Cleland P. (2010) Periodontal disease. In *Small Animal Clinical Nutrition 5th Edn*. Editors: Hand MS, Thatcher CD, Remillard RL, Roudebush P and Novotny BJ. Mark Morris Institute, Topeka, Kansas, US. pp 989 – 1001.

Major A., Schweighauser A., Hinden S.E., and Francey T. (2014) Transient Fanconi syndrome with severe polyuria and polydipsia in a 4-year old Shih Tzu fed chicken jerky treats. *Schweiz Archiv fur Tierheilkunde* 156(12):593-598.

Marx F.E., Machado G.S., Pezzali J.G., Marcolla C.S., et al. (2016). Raw beef bones as chewing items to reduce dental calculus in Beagle dogs. *Australian Veterinary Journal* 94(1-2):18-23.

Matejka M., Partyka L., Ulm C., et al. (1998). Nitric oxide synthesis is increased in periodontal disease. *Journal of Periodontal Research* 33:517-518.

Miller B.R. and Harvey C.E. (1994) Compliance of with oral hygiene recommendations following periodontal treatment in client owned dogs. *Journal of Veterinary Dentistry* 11(1):18-19.

Robinson J.G.A. and Gorrel C. (1997) The oral status of a pack of foxhounds fed a “natural” diet. In: Proceedings. World Veterinary Dental Congress, Birmingham, UK: 35-37.

Roudebush P., Logan E.I., Hale F.A. (2005) Evidence-based veterinary dentistry: a systematic review of homecare for prevention of periodontal disease in dogs and cats. *Journal of Veterinary Dentistry* 22(1):6-15.

Rubio A., van Goethem B., Verhaert L. (2010) Tongue entrapment by chew toys in two dogs. *J Sm Anim Pract* 51(10):558-560.

Steenkamp G and Gorrell C (1999) Oral and dental conditions in adult African wild dog skulls: a preliminary result. *Journal of Veterinary Dentistry* 16(2):913-918.

Stookey G.K. (2009) Soft rawhide reduces calculus formation in dogs. *Journal of Veterinary Dentistry* 26(2):82-85.

Stookey G.K., Warrick J.M., Miller L.L. (1995) Sodium hexametaphosphate reduces calculus formation in dogs. *American Journal of Veterinary Research* 56: 913-918.

Theyse L. (2003) Hill's Prescription Diet Feline t/d: Results of a Field Study. Proceedings of Hill's European Symposium on Oral Care. Amsterdam 19th to 20th March 2003 pp 60-63.

Verstraete F.J., van Aarde R.J., Nieuwoudt B.A., et al. (1996) The dental pathology of feral cats on Marion Island; part II: periodontitis, external odontoclastic resorption lesions and mandibular thickening. *Journal of Comparative Pathology* 115(3):283-297.

vohc.org

Vullo C. (2014) Lactobacillus brevis CD2 and odontostomatological diseases. Probiotics in veterinary medicine - an update and perspectives. The Sivoy Study The Sivoy Study Group, Rome 17 March, Abstract

Warrick J.M., Stookey G.K., Blickman T.R., et al. The role of plaque and calculus in the etiology of periodontal disease. In: Proceedings 17th Annual Veterinary Dental Forum, November 6-9, 2003, San Diego, CA: 169-174.

Watson A.D. (1994). Diet and periodontal disease in dogs and cats. *Australian Veterinary Journal* 71(10):313-318.

Wiggs RB, Lobprise HB (1997) Periodontology, in *Veterinary Dentistry, Principals and Practice*. Philadelphia, PA, Lippincott – Raven, pp 186-231.

Boyce EN, Ching RJ. Logan EI. Hunt JH. Maseman DC. Gaeddert KL. King CT. Reid EE. Hefferren JJ (1995): Occurrence of gram-negative black-pigmented anaerobes in subgingival plaque during the development of canine periodontal disease. *Clin Infect Dis*. 20 Suppl 2:S317-9.

Fiorellini JP, Ishikawa SO, Kim DM (2006) Clinical Features of Gingivitis, in: Carranza's *Clinical Periodontology*. St. Louis, Mo, WB Saunders, pp 362- 72.

Rober M (2007) Effect of scaling and root planing without dental homecare on the subgingival microbiota. Proceedings of the 16th European congress of veterinary dentistry: pp 28-30.

Needleman I, Suvan J, Moles DR, Pimlott J. (2005) A systematic review of professional mechanical plaque removal for prevention of periodontal diseases. *J Clin Periodontol.* 32 Suppl 6:229-82.

Proceedings of the European workshop on mechanical plaque control, Chicago, 1998, Quintessence.

Perry DA (2006) Plaque control for the periodontal patient. in: Carranza's Clinical Periodontology. St. Louis, Mo, WB Saunders, pp 728-748

Westfelt E, Rylander H, Dahlen G, Lindhe J (1998) The effect of supragingival plaque control on the progression of advanced periodontal disease. *J Clin Periodontol.* 25(7): 536-41.

Niemiec BA (2008) Periodontal therapy. *Top Companion Anim Med.* 23(2):81-90, 2008.

Hale FA (2003) Home care for the veterinary dental patient. *J Vet Dent* 20(1) 52-4.

Williams JE (1995) Microbial Contamination of Dental Lines, in *Current and Future Trends In: Veterinary Dentistry: Proceedings of the Upjohn Worldwide Companion Animal Veterinary Dental Forum.* 8-11.

Quirynen M, Teughels W, Kinder Haake S, Newman MG: (2006) Microbiology of Periodontal diseases, in: Carranza's Clinical Periodontology. St. Louis, Mo, WB Saunders, pp 134-169

Capik I (2007) Periodontal health vs. different preventative means in toy breeds – clinical study. *Proceedings of the 16th European congress of veterinary dentistry:* pp 31-4.

Bjone S, Brown W, Harris A, Genity PM (2007) Influence of chewing on dental health in dogs. *Proceedings of the 16th European congress of veterinary dentistry:* pp 45-6, 2007.

Holmstrom SE, Frost P, Eisner ER (1998) Dental Prophylaxis, in *Veterinary Dental Techniques,* (ed 2). Philadelphia, PA, Saunders, 1998, pp 133-166.

Moritis K, Jenkins W, Hefti A, Schmitt P, McGrady M. (2008) A randomized, parallel design study to evaluate the effects of a Sonicare and a manual toothbrush on plaque and gingivitis. *J Clin Dent.*;19(2):64-8.

Deery C, Heanue M, Deacon S, Robinson PG, Walmsley AD, Worthington H, Shaw W, Glenny AM. (2004)The effectiveness of manual versus powered toothbrushes for dental health: a systematic review. *J Dent.* 2004, 32(3):197-211.

Hennet P, Servet E, Soulard Y, Biourge V (2007) : Effect of pellet food size and polyphosphates in preventing calculus accumulation in dogs. *J Vet Dent.* Dec;24(4):236-9.

Liu H, Segreto VA, Baker RA, Vastola KA, Ramsey LL, Gerlach RW: (2002) Anticalculus efficacy and safety of a novel whitening dentifrice containing sodium hexametaphosphate: a controlled six-month clinical trial. *J Clin Dent.*;13(1):25-8.

Eaton KA, Rimini FM, Zak E, et al: (1997) The effects of a 0.12% chlorhexidine-digluconate containing mouthrinse versus a placebo on plaque and gingival inflammation over a 3-month period. A multicentre study carried out in general dental practices. *J Clin Periodontol.* 24(3): 189-97.

Hennet P (2002) Effectiveness of a dental gel to reduce plaque in beagle dogs. *J Vet Dent.* 19(1): 11-4.

Niemiec BA (2012): Home Plaque Control. In: *Veterinary Periodontology.* John Wiley and Sons. Ames. Pp 175-85.

Gorrel C, Rawlings JM. (1996) The role of tooth-brushing and diet in the maintenance of periodontal health in dogs. *J Vet Dent.*13(4):139-43

Tromp JA, Jansen J, Pilot T. (1986) Gingival health and frequency of tooth brushing in the beagle dog model. Clinical findings. *J Clin Periodontol.*;13(2):164-8.

Corba NH, Jansen J, Pilot T (1986) Artificial periodontal defects and frequency of tooth brushing in beagle dogs (II). Clinical findings after a period of healing. *J Clin Periodontol.*;13(3):186-9.

Corba NH, Jansen J, Pilot T (1986) Artificial periodontal defects and frequency of tooth brushing in beagle dogs (I). Clinical findings after a period of healing. *J Clin Periodontol.*;13(3):158-63.

Tromp JA, van Rijn LJ, Jansen J (1986) Experimental gingivitis and frequency of tooth brushing in the beagle dog model. Clinical findings. *J Clin Periodontol.*;13(3):190-4.

Ingham KE, Gorrel C. (2011) Effect of long-term intermittent periodontal care on canine periodontal disease. *J Small Anim Pract.*42(2):67-70.

Robinson JG (1995) Chlorhexidine gluconate – the solution to dental problems. *J Vet Dent.* 12(1), 29-31.

Roudebush P, Logan E, Hale, FA (2005) Evidence-based veterinary dentistry: a systematic review of homecare for prevention of periodontal disease in dogs and cats. *J Vet Dent.* 22(1): 6-15.

Hamp SE, Emilson CG (1973) Some effects of chlorhexidine on the plaque flora of the beagle dog. *J Periodontol Res.* 12: 28-35.

Hamp SE, Lindhe J, Loe H. (1973) Long term effects of chlorhexidine on developing gingivitis in the beagle dog. *J Periodontol Res.* 8: 63-70.

Tepe JH, Leonard GJ, Singer Re, et al (1983) The long term effect of chlorhexidine on plaque, gingivitis, sulcus depth, gingival recession, and loss of attachment in beagle dogs. *J Periodontal Res.* 18: 452-8.

Salas Campos L, Gómez Ferrero O, Villar Miranda H, Martín Rivera B (2000) Antiseptic agents: chlorhexidine. *Rev Enferm.* 23(9):637-40.

Cousido MC, Tomás Carmona I, García-Caballero L, Limeres J, Alvarez M, Diz P.(2009) In vivo substantivity of 0.12% and 0.2% chlorhexidine mouth rinses on salivary bacteria. *Clin Oral Investig.*

Bonesvoll P: (1977) Oral pharmacology of chlorhexidine. *J Clin Periodontol* 4: 49-65.

Wolinsky LE, Cuomo J, Quesada k, et al. (2000) A comparative pilot study of the effects of a dentifrice containing green tea bioflavonoids, sanguinarine, or triclosan on oral bacterial biofilm formation. *J Clin Dent.* 11: 535-559.

Clarke DE (2001) Clinical and microbiological effects of oral zinc ascorbate gel in cats. *J Vet Dent.* 18(4) 177-183.

Pinnel SR, Murad S, Darr D (1987) Induction of collagen synthesis by ascorbic acid. A possible mechanism. *Arch Dermatol.*, 123(12):1684-6.

Murad S, Grove D, Lindberg KA, Reynolds G, Sivarajah A, Pinnell SR (1981) Regulation of collagen synthesis by ascorbic acid. *Proc Natl Acad Sci U S A.*78(5):2879-82.

Homola AM, Dunton RK (1999) Methods, Compositions, and dental delivery systems for the protection of the surfaces of teeth. U.S. Patent No. 5,665,333 issues Sept 9, 1997 and U.S. Patent No. 5,961,958 issued October 5.

Gengler WR, Kunkle BN, Romano D, Larsen D: (2005) Evaluation of a barrier sealant in dogs. *J Vet Dent* 22(3): 157-9.

Sitzman C (2013). Evaluation of a hydrophilic gingival dental sealant in beagle dogs. *J Vet Dent.* 30(3):150-5.

Miller BR, Harvey CE (1994) Compliance with oral hygiene recommendations following periodontal treatment in client-owned dogs. *J Vet Dent.* 11(1), 18-19.

Vrieling HE, Theyse LF, van Winkelhoff AJ, Dijkshoorn NA, Logan EI, Picavet P.(2005) Effectiveness of feeding large kibbles with mechanical cleaning properties in cats with gingivitis. *Tijdschr Diergeneeskd.*;130(5):136-40.

Debowes LJ (2010) Problems with the gingiva. In: *Small Animal dental, oral and maxillofacial disease, A color handbook* (Niemic BA ed.). London, Manson, 2010, pp159 – 181.

Verstraete FJ, van Aarde RJ, Nieuwoudt BA, et al (1996) The dental pathology of feral cats on Marion Island, part II: periodontitis, external odontoclastic resorption lesions and mandibular thickening. *J Comp Pathol.* 115(3): 283-97.

Clarke DE, Cameron A (1998) Relationship between diet, dental calculus, and periodontal disease in domestic and feral cats in Australia. *Aust Vet J.* 76(10): 690-3.

Steenkamp G, Gorrel C. (1999) Oral and dental conditions in adult African wild dog skulls: a preliminary report. *J Vet Dent.* 16; 65-8.

Sherman PR, Hutchens LH Jr, Jewson LG. (1990) The effectiveness of subgingival scaling and root planing. II. Clinical responses related to residual calculus. *J Periodontol.* 61(1):9-15.

Association of American Feed Control Officials, inc (AAFCO). Official publication of the Association of American Feed Control Officials, Oxford IN, 2010.

Harvey CE, Shofer FS, Laster L: (1996) Correlation of diet, other chewing activities, and periodontal disease in North American Client-owned dogs. *J Vet Dent.* 13: 101-5.

Stookey GK, Warrick JM (2005) Calculus prevention in dogs provided diets coated with HMP. Proceedings of the 19th annual American Veterinary Dental Forum, Orlando, pp. 417-421.

Gorrel C, Bierer TL: (1999) Long-term effects of a dental hygiene chew on the periodontal health of dogs. *J Vet dent* 16(3):109-13.

Stookey GK: (2009) Soft rawhide reduces calculus formation in dogs. *J Vet Dent.* ;26(2):82-5.
Gorrel C, Warrick J, Bierer TL. (1999) Effect of a new dental hygiene chew on periodontal health in dogs. *J Vet Dent.* 16(2):77-81.

Mariani C, Douhain J, Servet E, Hennet P, Biourge V: (2009) Effect of toothbrushing and chew distribution on halitosis in dogs. Proceedings of the 18th congress of veterinary dentistry, Zurich, pp. 13-15.

Warrick JM, Stookey GK, Inskeep GA, Inskeep TK (2001) Reducing calculus accumulation in dogs using an innovative rawhide treat system coated with Hexametaphosphate. Proceedings of the 15th annual American Veterinary Dental Forum, San Antonio, pp. 379-382.

Brown WY, McGenity P: (2005) Effective periodontal disease control using dental hygiene chews. *J Vet Dent* 22(1): 16-9.

White DJ, Cox ER, Suszcynskymeister EM, Baig AA (2002) In vitro studies of the anticalculus efficacy of a sodium hexametaphosphate whitening dentifrice. *J Clin Dent.* 13(1):33-7.

Stookey GK, Warrick JM, Miller LL, et al (1996): Hexametaphosphate-coated snack biscuits significantly reduce calculus formation in dogs. *J vet dent* 13(1), 27-39.

Chapek CW, Reed OK, Ratcliff PA.(1995) Reduction of bleeding on probing with oral-care products. *Compend Contin Educ Dent.*16(2):188, 190, 192.

Section 6: Dental Radiology

Dental radiography for dogs and cats

Full-mouth dental radiographs are performed as part of the dental patient diagnostic work-up, especially if the animal is presented for the first time, or if the clinical condition has changed significantly since the previous visit. Dental radiographs aid in diagnosis and guide treatment. They are also an important part of the legal record, and can be extremely valuable in client education. Full-mouth dental radiographs will reveal about 40% more pathology than was found on the clinical examination. (Verstraete FJ et al 1998a, b) (see oral pathology section) Due to costs, practitioners are often forced to balance the desire for a full-mouth set of radiographs with their client's financial constraints. However, at least obtaining dental radiographs of the teeth clinically found to be diseased is mandatory.

Equipment and techniques

Dental radiography requires a dental x-ray unit (e.g., wall-mounted, mobile, hand-held) and a detection system (e.g., conventional intraoral dental films, "direct" digital radiography (DR), or computed radiography (CR)). (Niemic BA 2010, Niemic BA et al 2004, Wiggs RB Lobprise HB 1997) However, in tier 1 countries, medical x-ray equipment with extra-oral plates will provide diagnostic information. (Mulligan TM et al 1998) (see section on equipment)

There are three standard techniques to obtain dental radiographs: parallel technique (for mid to caudal mandibles), extra-oral or near-parallel technique (for caudal maxillae in cats), and bisecting angle technique for all other areas. (AVDC 2016a, Niemic BA et al 2004, Niemic BA Furman R 2004, Oaks A 2000, Wiggs RB Lobprise HB 1997), All radiographs are obtained with the patient under general anaesthesia. (See anesthesia section)

Parallel technique

Place the film/sensor/phosphor plate intra-orally, positioned lingually to the teeth to be radiographed, so that the film is parallel to the long axis of the target teeth. The film must project beyond the ventral margin of the mandible and dorsal to the crowns of the tooth/teeth. When imaging large teeth with a size 2 sensor, two radiographs may be necessary. A clear 3 mm margin of film must be evident around the tooth being radiographed. Position the x-ray tube so that the central x-ray beam (black arrows, Fig. 1) is perpendicular to the film, and bring the x-ray tube as close as possible to the object (tooth) (Figs. 1, 2 left). Finally, make sure the area of interest is within the circumference of the tube. (AVDC 2016a)

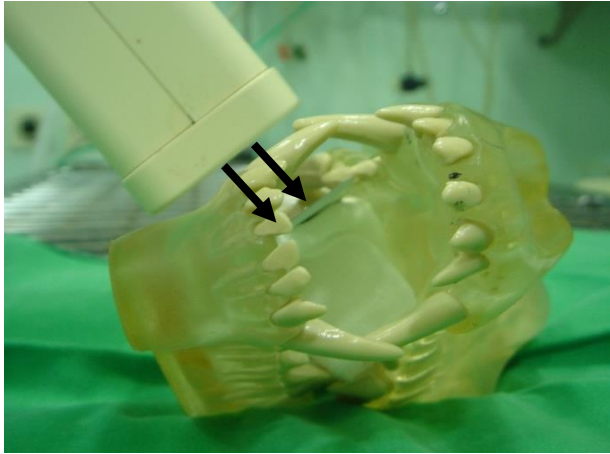

Fig. 1 Representation of the parallel technique to radiograph caudal mandibular premolar and molar teeth using a clear dog skull model. Black arrows indicate the central x-ray beam, which is positioned perpendicular to the film.

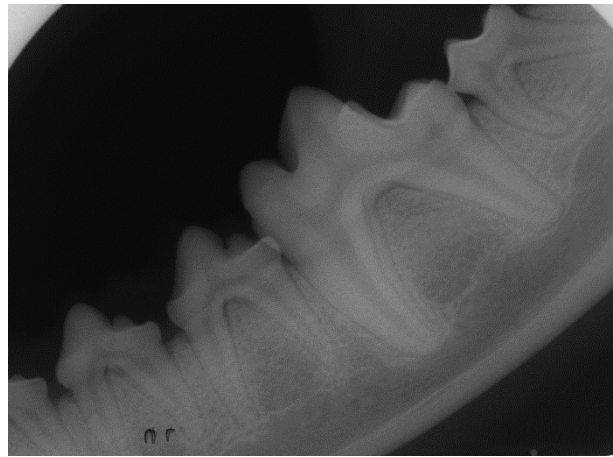
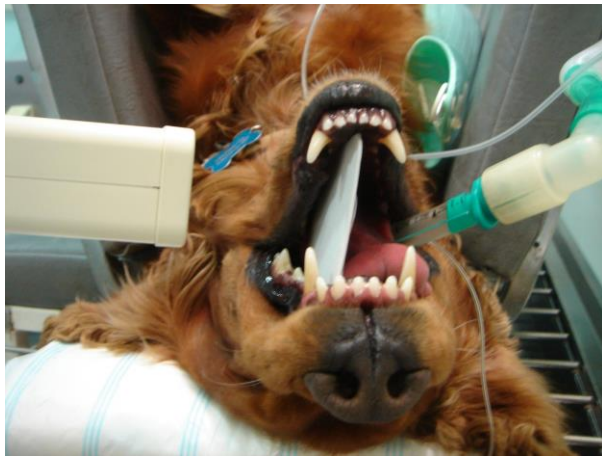

Fig. 2 Representation of the parallel technique using a conventional dental film #4 size to radiograph left mandibular fourth premolar and first molar tooth in an anaesthetised patient (left) and the resulting radiograph (right). Note the 3 mm clear margin beyond the roots of both teeth being examined.

Bisecting angle technique

The bisecting angle technique is used when the film cannot be placed parallel to the tooth and perpendicular to the x-ray beam due to anatomy of the oral cavity and teeth – i.e. for all maxillary and rostral mandibular teeth. The film is placed in the mouth so that the tip of the film will rest on the crown of the tooth being examined while the remainder of the film will span across the mouth/palate. Visualize the angle formed by the long axis of (tip of the root to tip of the crown) the tooth to be radiographed (black line, Fig. 3) and the plane of the film. Then bisect this angle with an imaginary line (red line, Fig. 3) and position the x-ray tube so that the central x-ray beam is perpendicular to the imaginary bisecting line (black arrows, Fig. 3). Place the x-ray tube as close as possible to the tooth and check that the teeth of interest are within the

circumference of the tube. (AVDC 2016a) If using size #4 or #5 draw the tube slightly away from the tooth/jaw so that the divergent beam leaving the tube will expose the whole plate. If too close, coning-off will happen (part of the plate is not exposed).

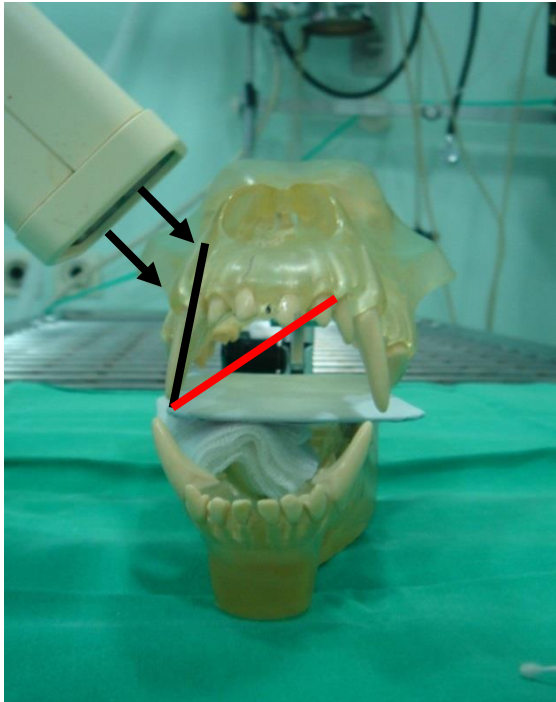


Fig. 3 An example (lateral view of the right maxillary canine tooth in a dog) of the bisecting angle technique using a clear dog skull model. Black line indicates the long axis of the canine tooth and red line indicates the bisecting line between the long axis of the canine tooth and film plane. Black arrows indicate the central x-ray beam, which is perpendicular to the bisecting (red) line.

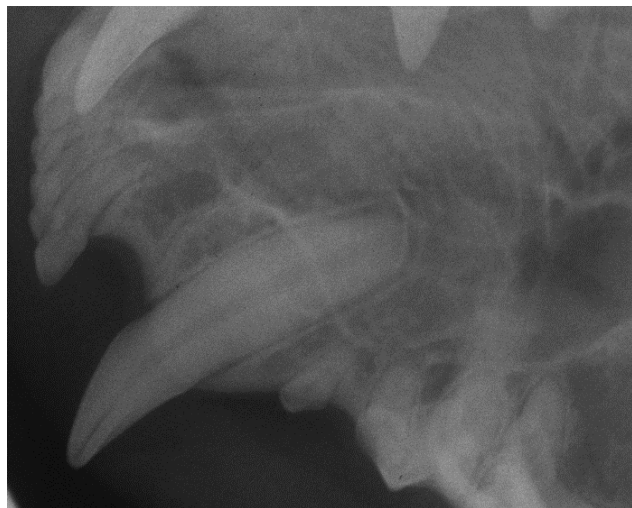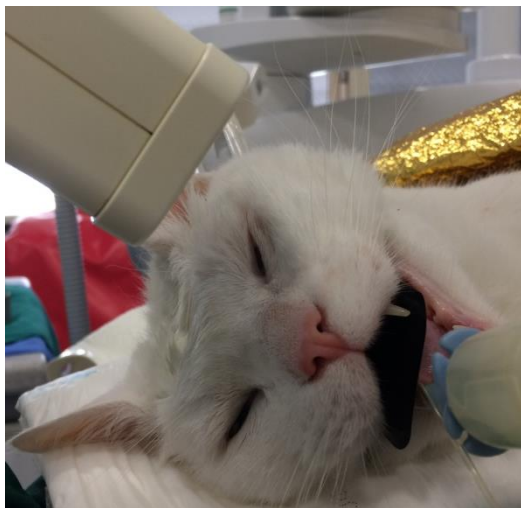


Fig. 4 Representation of the bisecting angle technique using a #2 size intraoral imaging plate in a barrier envelope to radiograph left maxillary canine tooth (lateral view) in an anaesthetised patient (left) and the resulting radiograph (right). The canine is well centred on the radiograph.

Extra-oral technique

The extra-oral near-parallel technique is used to radiograph the maxillary premolar and molar teeth in cats to avoid superimposition of the zygomatic arch over the roots of the teeth of the caudal maxilla, which often happens when using the intraoral bisecting angle technique. (AVDC 2016a, Oaks A 2000, Niemiec BA and Furman R 2004) Position the cat in lateral recumbency and place a film on the table under the cat's head/maxilla (the side to be radiographed is closer to the table/film). The patient's mouth is held open using a gentle gag (only use a gag for a short period of time – e.g., just to obtain the radiograph – to avoid possible complications associated with mouth gag use – See anaesthesia section). Then, one option (Fig. 5 left) is to position the cat's head slightly obliquely (to avoid superimposition of the contralateral maxillary teeth) and position the x-ray tube so that the central x-ray beam is perpendicular to the film. To use the maximum amount of the film (e.g., if using #2 size film), position the head so that the tips of the cusps of the teeth to be radiographed are lined up along the edge of the film.

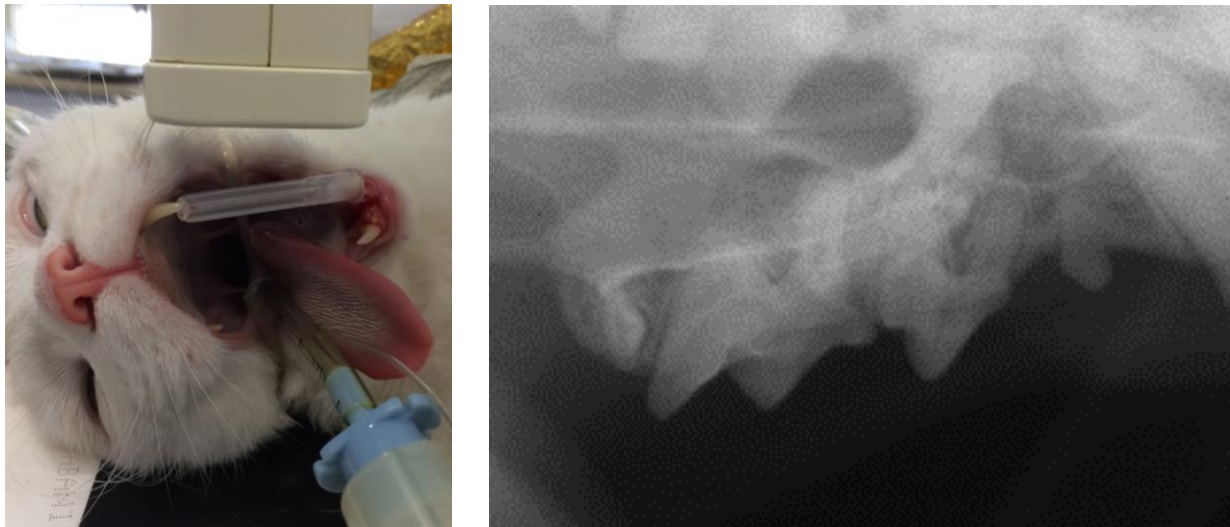


Fig. 5 Representation of the extra-oral near-parallel technique using a #4 size intraoral imaging plate in a barrier envelope to radiograph the right maxillary premolar and molar teeth in an anaesthetised patient (left) and the resulting radiograph (right). Always mark this view as “right maxilla – extra-oral”. Note separation of the mesial roots of right maxillary P4 – also note that the zygomatic arch is superimposed on the crowns of these teeth and not on the root apices.

Intra-oral near-parallel technique

To utilize this technique, the film is placed diagonally across the mouth, keeping the mouth open (acting somewhat as a mouth gag). It should rest on the palatal surface of the opposite maxillary teeth and on the lingual surface of the ipsilateral mandibular teeth. The beam is then placed almost parallel to the plate (almost perpendicular to the tooth roots). (Woodward TM 2009) (Figure 6).

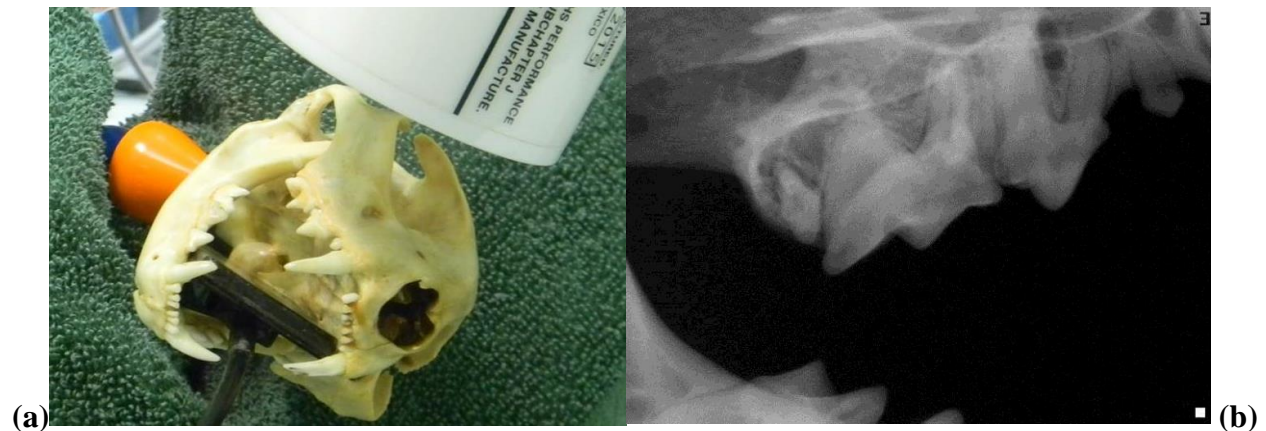

Figure 6: Near-parallel imaging of the right maxillary dentition.

- a) Correct positioning for the near parallel technique.
- b) Proper resultant image with minimal zygomatic arch interference over the roots.

Standard views (AVDC 2016a)

Standard views for the dog include 1) occlusal view of maxillary incisors and canine teeth (bisecting angle technique), 2) lateral view of the maxillary canine teeth (bisecting angle technique), 3) rostral maxillae (P1-P3; bisecting angle technique), 4) caudal maxillae (P4-M2; bisecting angle technique), 5) occlusal view of the mandibular incisors and canine teeth (bisecting angle technique), 6) lateral view of the mandibular canine teeth (bisecting angle technique), 7) rostral mandibles (P1-P3; bisecting angle technique) and 8) caudal mandibles (P4 - M3; parallel technique).

Standard views for the cat include 1) occlusal view of the maxillary incisors and canine teeth (bisecting angle technique), 2) lateral view of the maxillary canine teeth (bisecting angle technique), 3) extra-oral (near-parallel) view of the maxillae (P2-M1), 4) occlusal view of the mandibular incisor and canine teeth (bisecting angle technique), 5) lateral view of the mandibular canine teeth (bisecting angle technique), 6) caudal mandibles (P3-M1; parallel technique).

In addition, other view(s) for separation of the superimposed mesiobuccal and mesiopalatal roots of the maxillary fourth premolar teeth should be included. (AVDC 2016a, Niemiec BA and Furman R 2004)

The simplified approach to dental radiology was developed by Dr. Tony Woodward. (Woodward TW 2008,) This technique does not utilize direct measurement of any angle, but instead relies on approximate angles to create diagnostic images. There are only 3 angles used for all radiographs in this system 20, 45, and 90 degrees.

The *mandibular* premolars and molars are exposed at a 90 degree angle (parallel technique). *Maxillary* premolars and molars have roots that are approximately vertical from the crowns, and the sensor is positioned essentially flat across the palate, creating a 90 degree angle. Therefore, the maxillary premolars and molars are imaged with a 45-degree x-ray sensor bisecting angle.

The roots of the canines and incisors curve distally approximately 40 degree angle to the palate/mandibular gingiva and therefore are imaged with a 20 degree angle rostro-caudally. Note, the mandibular canines are more

Interpretation of dental radiographs

Technical quality

Once the radiographs are obtained, they should be evaluated for technical quality (e.g., Is the area of interest on the image? Is there any elongation/foreshortening of teeth? What is the quality of exposure? Are there any processing errors?). (Mulligan et al 1998, Eisner ER 2000)

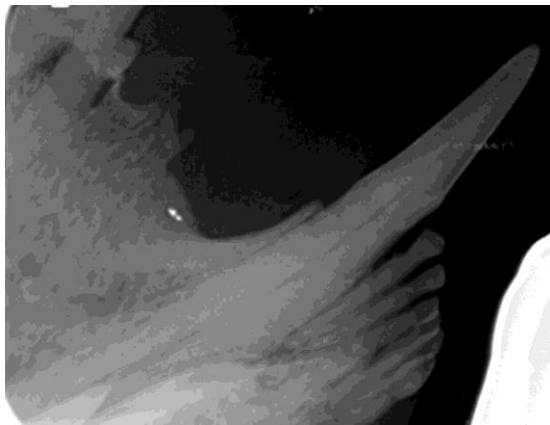


Fig. 7 An example of elongation of the right mandibular canine tooth on a lateral view in a cat. This results from an improper use of bisecting angle technique (the x-ray beam is oriented almost perpendicular to the long axis of the tooth).

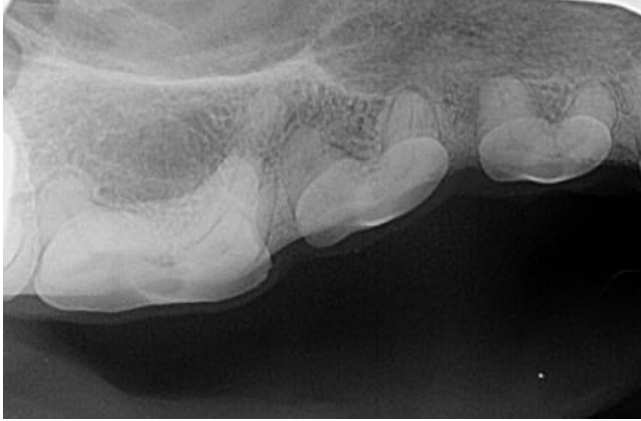


Fig. 8 An example of foreshortening of the right maxillary second, third and fourth premolar teeth in a dog. This results from an improper use of bisecting angle technique (the x-ray beam is oriented almost perpendicular to the film).

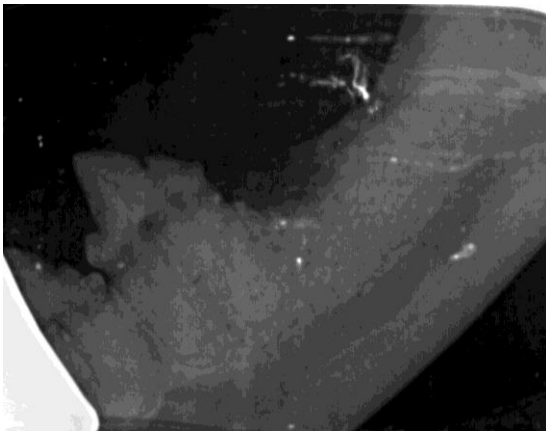

Fig. 9 An example of blood on the imaging plate causing aretfacts which are visible on the processed image and interefering with interpretation of the area of the missing mandibular left first molar tooth in a cat.

Mounting of dental radiographs

Radiographs should be oriented using “labial mounting”

- 1) If using conventional dental films ensure that the embossed dot/orientation mark faces up for all radiographs, where intra-oral technique was used.
 - a. Ensuring dot orientation is not necessary on digital systems as it is standard orientation on digital systems.
- 2) Crowns of the maxillary teeth should point down and crowns of mandibular teeth up.
- 3) Occlusal views are in the center, with first incisor teeth at the midline.
- 4) Molar teeth are on the periphery.

This orientation results in the radiographs of the teeth from the patient’s left side to be on the right side and vice-versa (note positioning of extra-oral views). (AVDC 2016b).

Interpretation of dental radiographs

Diagnostic quality radiographs must be systematically examined. Interpretation of dental radiographs requires knowledge of normal dental radiographic anatomy in order to be able to diagnose any anatomical / developmental abnormalities, periodontal pathologies, endodontal pathologies and other abnormalities. (Niemic BA 2005, Dupont G and Debowes LJ 2009). **(See Oral Pathology Section)**

References

DuPont G, DeBowes LJ (2009). Atlas of dental radiography in dogs and cats. St. Louis: Saunders Elsevier.

AVDC (2016a)

AVDC (2016b) http://www.avdc.org/rad_set_SA_inform.pdf 10.10.2016

Niemic BA (2010). Veterinary dental radiology. In: Niemic BA (ed.). A color handbook of small animal dental, oral and maxillofacial disease. Boca Raton: CRC Press, Taylor & Francis Group; p. 63-87.

Verstraete FJ, Kass PH, Terpak CH (1998a). Diagnostic value of full-mouth radiography in cats. Am J Vet Res 59(6):692-695.

Verstraete FJ, Kass PH, Terpak CH (1998b). Diagnostic value of full-mouth radiography in dogs. Am J Vet Res 59(6):686-691.

Niemic BA, Sabitino D and Gilbert T (2004) Equipment and basic geometry of dental radiography. Journal of Veterinary Dentistry, 21:48–52.

Wiggs RB and Lobprise HB.(1997) Dental and oral radiology. In: Veterinary Dentistry: Principles and Practice. Philadelphia, Lippincott–Raven, 140-66.

Niemic BA, Furman R (2004) Canine dental radiography. J Vet Dent.21(3):186-90.

Niemic BA, Furman R (2004). Feline dental radiology. J Vet Dent 21(4):252–7.

Oakes A. (2000) Introduction: Radiology Techniques. In: An Atlas of Veterinary Dental Radiology. DeForge DH, Colmery BH (eds), Ames, Iowa State University Press. xxi-xxvi.

Woodward TM. (2009) Dental radiology. Top Companion Anim Med. 24(1):20-36.

Niemic BA (2005) Dental radiographic interpretation. Journal of Veterinary Dentistry, 22:53–9.

Mulligan TW, Aller MS, Williams CA (1998) Technical errors and troubleshooting. In: *Atlas of Canine and Feline Dental Radiography*. Veterinary Learning Systems, Trenton, pp. 45–64.

Mulligan TW, Aller MS, Williams CA (1998) Extraoral Imaging Techniques. In: *Atlas of Canine and Feline Dental Radiography*. Veterinary Learning Systems, Trenton, pp. .

Eisner ER (2000) Film artifacts, visual illusions, and technical errors. In. *An Atlas of Veterinary Dental Radiology*. (eds. DH DeForge, BH Colmery) Iowa State University Press, Ames, pp. 201–14.

Section 7: Dental Extractions

Introduction

Dental extractions are a very commonly performed procedure in most veterinary practices, yet they are not a simple undertaking. They are typically performed to remove an infected and/or painful tooth. Indications include, but are not limited to endodontic disease (i.e. fractured or intrinsically stained teeth), severe periodontal disease, traumatic malocclusion, persistent deciduous teeth, tooth resorption, infected teeth, caudal stomatitis, and unerupted teeth. Complete extraction of the diseased tooth almost invariably resolves the existing disease state. However, when extractions are improperly performed, even simple procedures can have numerous iatrogenic complications, including hemorrhage, osteomyelitis, oronasal fistula, forcing of a root tip into the mandibular canal or nasal cavity, jaw fracture, and ocular damage. (Taylor TN 2004, Holmstrom SE et al 1998, Niemiec BA 2014) However, the most common iatrogenic complication is retained tooth roots. (Woodward TM 2006, Moore JI & Niemiec BA 2014) This generally results in continued infection in and around the retained root. (Woodward TM 2006) A guideline for proper and successful closed dental extractions is summarized in the following 10 steps. These steps constitute the technique for a single rooted tooth; however multi-rooted teeth are treated the same way following sectioning. Finally, large teeth and those with root malformations are best treated with an “open” approach including mucoperiosteal flap creation and bone removal.

Step 1: Obtain Consent

Never extract a tooth without prior owner consent, no matter how advanced the problem, or how obvious it is that extraction is the proper therapy. (Holmstrom SE et al 1998) This consent is preferably written, but acceptable verbally via a phone call. If the client cannot be reached and prior consent was not obtained, do not extract the tooth. (Niemiec BA 2008)

Step 2: Obtain pre-operative dental radiographs

Dental radiographs should be made of all teeth prior to commencing the extraction (note in tier 1 countries conventional radiology may be acceptable (See equipment section). (Niemiec BA 2009, Holmstrom SE et al 2009) Radiographs allow the practitioner to determine the amount of disease present, any root abnormalities, or resorption/ankylosis. (Niemiec BA 2009, Blazewski S et al 2006) Significant mandibular alveolar bone loss secondary to periodontal disease weakens the bone, and predisposes patients to an iatrogenic pathologic fracture. Dentoalveolar ankylosis makes extraction by traditional elevation practically impossible. For this reason, crown amputation and intentional root retention is acceptable for advanced Type 2 feline tooth resorption, as determined via dental radiographs (DuPont 1995). In summary, dental radiographs provide critical information for treatment planning and the successful outcome of dental extraction procedures. Finally, radiographs provide solid evidence in the medical record. (Niemiec BA 2009)

Step 3: Ensure proper visibility and accessibility

Patients should be positioned to allow maximum visibility of the oral procedure area, and to allow for the surgeon to be most comfortable and therefore more successful. (Holmstrom SE et al 1998) Surgical lighting should be bright and focused on the surgical field. Suction, air/water

syringes, and gauze should be utilized continually to keep the surgical field clear. Finally, magnification can be useful. (Niemic BA 2008)

Step 4: Pain Management

Extractions are surgical procedures and are moderately to severely painful. Depending on patient health, a multimodal analgesic approach should be employed, as this provides superior analgesia. (Kelly DJ et al 2001, Lanz GC 2003)) (See anesthesia section)

Step 5: Cut the gingival attachment

This can be performed with a scalpel blade, periosteal elevator, or dental elevator. The selected instrument is placed into the gingival sulcus with the tip of the blade angled toward the tooth, which helps keep the instrument within the periodontal ligament space. Failure to do so may result in creating a mucosal defect or cutting through the gingiva. The blade is then advanced apically to the level of the alveolar bone, and carefully worked around the entire tooth circumference. (Niemic BA 2008, Hobson P 2005)

Step 6: Elevation

Elevation/luxation is the most delicate and dangerous step in the extraction procedure. Remember that elevators are sharp surgical instruments and there are numerous critical and delicate structures in the area. There have been many reports of eyes that have been injured by extraction instruments as well as at least one confirmed fatality due to an elevator puncturing a patient's brain. (Smith MM et al 2003) In order to avoid causing iatrogenic trauma in the event of instrument slippage or upon encountering diseased bone, the index finger is placed near the tip of the instrument. (Niemic BA 2008, Blazejewski S et al 2006)

It is important to select an instrument which matches the curvature and size of the root.(Woodward TM 2006) In general "go small", as this will result in less pressure and damage being created.

There are numerous instruments available, including the classic elevator as well as luxating and winged types. Classic elevators and winged elevators are used in an "insert and twist" motion to tear the periodontal ligament, whereas luxators are used in a rocking motion during insertion to fatigue as well as cut the periodontal ligament. Veterinarians may be tempted to gently twist luxators for elevation, but they are not designed for this and can be easily damaged when used in this manner.

Elevation is initiated by inserting the instrument firmly yet gently into the periodontal ligament space (between the tooth and the alveolar bone). (Niemic BA 2014) The insertion should be performed while keeping the instrument at a 10 - 20 degree angle toward the tooth, to avoid slippage. (Harvey CE & Emily PP 1993) Once in the space between the bone and the tooth, the instrument is gently twisted (Wiggs RB & Lobprise HB 1997). Hold the position for 10-30 seconds to fatigue and tear the periodontal ligament. (Holmstrom SE et al 1998) One important point is that the tooth should move at least slightly during elevation. If the tooth does not move, no damage is being done to the periodontal ligament.

Luxation is performed by gently inserting the luxator into the gingival sulcus and "rocking" it as the instrument is advanced apically. Many veterinary dentists use a combination of luxation and elevation when utilizing luxating elevators.

The periodontal ligament is very effective in resisting short, intense forces. (Proffit WR et al 2000) It is only by the exertion of prolonged force (i.e. 10-30 seconds) that the ligament will become weakened. Increased pressure will transfer much of the force to the alveolar bone and tooth which can result in the fracture of one of these structures. Therefore, it is important to moderate the force. After holding for 10 - 30 seconds, reposition the instrument about 1/8 of the way around the tooth and repeat the above step. Continue 360 degrees around the tooth, each time moving the elevator apically as much as possible (Niemic BA 2014, Holmstrom SE et al 1998, Wiggs RB & Lobprise HB 1997)

The key to successful elevation is PATIENCE. Only by slow, consistent elevation will the root loosen without breaking. It is always easier to extract an intact root than to remove fractured root tips. (Woodward TM 2006, Niemic BA 2008, Blazejewski S et al 2006)

If the elevation is not resulting in tooth mobility in a short period of time, there is a problem. This may be due to faulty extraction technique, or an area of dentoalveolar ankylosis. If the extraction is not going well, a surgical approach is a good option. Consider repeating the radiographs to determine if there are reasons for the lack of success.

Step 7: Extract the tooth

Removing the tooth should only be attempted after the tooth is very mobile and loose. This is accomplished by grasping the tooth with the extraction forceps and gently pulling the tooth from the socket. If the root is amenable (meaning round and not significantly curved) gentle rotation is acceptable, as long as the torque is maintained for a minimum of 10 seconds. Do not apply undue pressure as this may result in root fracture. (Wiggs RB & Lobprise HB 1997, Niemic BA 2008, Niemic BA 2014)

It is helpful to think of the extraction forceps as an extension of your fingers. Undue pressure should not be applied. If the tooth does not come out easily, more elevation is necessary. Start elevation again until the tooth is loose enough to be easily removed from the alveolus. This is an important point, because root fractures appear to occur more commonly with extraction forceps than with elevators. (Niemic BA 2015)

Step 8: Alveoloplasty

This step is performed to remove diseased tissue or bone, or any rough bony edges that could irritate the gingiva and delay healing. Diseased tissue can be removed by hand with a curette. Bone removal and smoothing is best performed with a coarse diamond bur on a water-cooled high-speed air driven hand-piece. (Smith MM 1998, Taney KG & Smith MM 2006, Wiggs RB & Lobprise HB 1997, Frost Fitch P 2003, Harvey CE & Emily PP 1993, Niemic BA 2014)

Step 9: Obtain a post-operative dental radiograph

Dental radiographs should be exposed post-extraction to document complete removal of the tooth. (Holmstrom et al 2005, Niemic BA 2009, (Figure 20) A recent study reported that 92% of extracted carnassial teeth in dogs and cats have retained roots. (Moore JI & Niemic BA 2014)

A retained root tip may become infected, or more commonly act as a foreign body and creating significant inflammation. (Wiggs RB & Lobprise HB 1997Ulbricht RD 2003) There are rarely any clinical signs observed with this complication, but the retained root is painful and/or

infected. Occasionally, this problem causes a draining tract from the retained roots, which may result in a malpractice claim. (Holmstrom SE et al 1998)

Step 10: Closure of the extraction site

This is a controversial subject among veterinary dentists, and thus some texts recommend suturing only in large extractions. However, many authors recommend suturing almost all extraction sites. Closure of the extraction site promotes hemostasis and improves post-operative comfort and aesthetics. It is always indicated in cases of larger teeth, or any time that a gingival flap is created to allow for easier extraction. This is best accomplished with size 3/0 to 5/0 absorbable sutures on a reverse cutting needle. Closure is performed with a simple interrupted pattern with sutures 2 to 3-mm apart. (Figure 18) It is further recommended to utilize one additional throw over manufacturer's recommendations in order to counteract tongue action. (Smith MM 1998, Taney KG & Smith MM 2006, Wiggs RB & Lobprise HB 1997, Frost Fitch P 2003, Harvey CE & Emily PP 1993, Niemiec BA 2014)

In regards to flap closure, there are several key points associated with successful healing. (Wiggs RB & Lobprise HB 1997) The first and most important is that there must be no tension on the incision line. (Blazejewski S et al 2006, Frost Fitch P 2003) If there is any tension on the suture line, it will dehiscence. Tension can be removed by extending the gingival incision along the arcade (called an envelope flap) or by creating vertical releasing incisions and fenestrating the periosteum. (Blazejewski S et al 2006, Frost Fitch P 2003) The periosteum is a very thin fibrous tissue which attaches the buccal mucosa to the underlying bone. (Evans HE 1993 Grant DA et al 1998) Since it is fibrotic, it is inflexible and will interfere with the ability to close the defect without tension. The buccal mucosa is very flexible and therefore will stretch to cover large defects. If there is no tension, the flap should stay in position when placed using fingers, then sutured in place. Fenestration can be performed with a scalpel blade, however LaGrange scissors offer more control. Finally, ensure that all tissue edges have been thoroughly debrided as intact epithelial tissues will not heal. (Blazejewski S et al 2006) This is most important when closing an oronasal fistula.

Extraction of multirooted teeth

Section all multi-rooted teeth into single rooted pieces. (Smith MM 1998, Charmichael DT 2002) The roots of almost all multi-rooted teeth are divergent, which will cause the root tips to break off if extractions are attempted in one piece. (Wiggs RB & Lobprise HB 1997 Manfra Marretta S 2002) With mobile teeth, the sectioning step alone often allows for simple extraction.

The best tool for sectioning teeth is a bur on a high-speed air driven hand piece. Charmichael DT 2002, Blazejewski S et al 2006) Besides being the most efficient tool, it also has air and water coolant that will avoid overheating the surrounding bone, possibly creating necrosis. Many different styles of burs are available, however many authors prefer a cross-cut taper fissure bur (699 for cats and small dogs, 701 for medium dogs and 702 for large breeds). (Niemiec BA 2008, Wiggs RB & Lobprise HB 1997)

The best way to section the teeth is to start at the furcation and work towards the crown of the tooth. (Niemiec BA 2014) This method is used for two major reasons. First, it avoids the possibility of missing the furcation and cutting down into a root, weakening it and increasing the risk of root fracture. (Smith MM 1998) Secondly, this technique also avoids the possibility of cutting past the tooth and inadvertently damaging the gingiva or alveolar bone.

Two rooted teeth are generally sectioned in the middle to separate the tooth into two halves. The mandibular first molar in the cat is an exception due to its disproportionate roots (see below). Proper sectioning of a three rooted molar tooth in a dog is performed by cutting between the buccal cusp tips and then just palatally to them. (Figure 23) After the tooth has been properly sectioned, follow the above steps for each single rooted piece.

Open Extractions:

Difficult extractions are best performed via an open approach. (Niemiec BA 2008) This is typically thought of as the canine and carnassial (maxillary fourth premolar and mandibular first molar) teeth. However, it is also beneficial for teeth with root malformations or pathology and retained roots. (Woodward TM 2006, Blazejewski S et al 2006, Frost Fitch P 2003), An open approach allows the practitioner to remove a small amount of buccal cortical bone, promoting an easier extraction process.

An open extraction is initiated by creating a gingival flap. This can be a horizontal flap along the arcade (an envelope flap) or a flap with vertical releasing incisions (a full flap). (Blazejewski S et al 2006).

An envelope flap is created by releasing the gingival attachment with a periosteal elevator along the arcade including one to several teeth on either side of the tooth or teeth to be extracted. (Grant DA et al 1988, Niemiec BA 2015) (Figure 25) The flap is created by incising the gingiva in the interdental spaces gingiva along the arcade and then releasing the tissue to or below the level of the mucogingival junction (MGJ). The advantage to this flap is that the blood supply is not interrupted and there is less suturing.

The more commonly used flap includes one or two vertical releasing incisions. (Holmstrom SE et al 1998, Niemiec BA 2015), (Figure 26) This method allows for a much larger flap to be created, which (if handled properly) will enable closure of larger defects. Classically, the vertical incisions are created at the line angle of the target tooth, or one tooth mesal and distal to the target tooth. (Smith MM 2003). If there is space between the teeth, either a naturally occurring diastema or from previous extraction, the incision can be made in the space rather than extending it to a healthy tooth. (Niemiec BA 2014)

The incisions should be made slightly apically divergent (wider at the base than at the gingival margin). (Carmichael DT 2002, Manfra Marretta S 2002) It is important that the incisions be created full thickness and in one motion (rather than slow and choppy). A full thickness incision is created by incising all the way to the bone, and the periosteum is thus kept with the flap. (Manfra Marretta S 2002, Frost Fitch P 2003) Once created, the entire flap is *gently* reflected with a periosteal elevator. Care must be taken not to tear the flap, especially at the muco-gingival junction.

Following flap elevation, buccal bone can be removed with a carbide bur. The amount is controversial, with some dentists removing the entire buccal covering and others removing only 1/3 of the root length of bone on the mandible and 1/2 for maxillary teeth. (Smith MM 1998, Frost Fitch P 2003) This should only be performed on the buccal side. If this does not allow for an expedient extraction, more can be removed.

Following bone removal, multirooted teeth should be sectioned (as above). Please note there are some authors that recommend sectioning prior to creating a flap. Then follow the steps outlined

for single root extractions for each piece. After the roots are removed (and radiographic proof obtained) the alveolar bone should be smoothed before closure (see aveoloplasty).

Closure is initiated with a procedure called fenestrating the periosteum. (See above) The periosteum is a very thin fibrous tissue which connects the buccal mucosa to the underlying bone. (Niemiec BA 2014, Grant DA 1988) Since the periosteum is fibrotic, it is inflexible and will interfere with the ability to close the defect without tension. The buccal mucosa however, is very flexible and will stretch to cover large defects. Consequently, incising the periosteum takes advantage of this attribute. The fenestration should be performed at the base of the flap, and must be very shallow as the periosteum is very thin. This step requires careful attention, as to not cut through or cut off the entire flap. This can be performed with a scalpel blade; however, a LaGrange scissor allows superior control.

After fenestration, the flap should stay in desired position without sutures. If this is not the case, then tension is still present and further release is necessary prior to closure. Once the release is accomplished, the flap is sutured as described above in the closure section.

Crown Amputation

Treatment of choice for teeth with TRs is extraction. However, crown amputation is an acceptable treatment option for advanced type 2 lesions (Dupont, 1995). Crown amputation results in significantly less trauma to the patient and faster healing than complete extraction. This procedure, although widely accepted, is still controversial. Most veterinary dentists employ this technique, however in widely varying frequency. Veterinary dentists typically use this treatment option only when there is significant or complete root replacement by bone. Unfortunately, the majority of general practitioners use this technique far too often. Crown amputation can only be performed if certain criteria are met (Niemiec BA 2015).

These are: (Figure 33)

- Radiographically confirmed type 2 TRs
- No evidence of endodontic disease (periapical rarefaction)
- No evidence of periodontal bone loss,
- No radiographically evident root canal
- No radiographic evidence of a periodontal ligament
- Not treating caudal stomatitis.

The authors tend to only utilize this technique for mandibular canines and third premolars. In addition, mandibular first molars (particularly the distal root) and maxillary canines are occasionally treated in this manner. The other teeth can generally be extracted, regardless of radiographic findings. Those practitioners without dental radiology should not perform crown amputation. In these cases, the teeth should either be fully extracted or the patient referred to a facility with dental radiology.

Technique

Crown amputation is initiated by creating a small gingival flap around the target tooth. (a) Next, use a cross cut taper fissure bur on a high-speed handpiece to remove the entire crown to the level of the alveolar bone. (b) The bone and tooth should then be smoothed with a coarse

diamond bur. (c) Following radiographic conformation that the tooth is removed to at least the level of the bone, the gingiva is sutured over the defect. (d) This may require slight fenestration to relieve tension.

Conclusion

Extractions are a very common procedure in veterinary medicine and can at times be very frustrating, especially for the novice. When performed correctly, this treatment is an excellent means to alleviate oral pain and infection. However, if extraction procedures are not treated with proper respect, they can (and will) result in problems such as fractured root tips and/or more serious iatrogenic problems.

By following the steps outlined above, and utilizing PATIENCE, extractions will become not only easier, but also more successful and rewarding.

Key Points

- Extractions are surgical procedures and must be treated with the same level of respect as any surgery to avoid complications.
- All extractions can be broken down into simple, single root extraction via sectioning and buccal cortical bone removal. Therefore, master the basics and any extraction can be performed.
- Extractions are painful procedures, therefore proper pain management, including regional anesthesia, should be provided for every patient.
- Crown amputation is an accepted method of therapy for advanced type 2 lesions in cats, but only if certain criteria (clinical and radiographic) are met.
- Never extract a tooth without client consent.

References:

Holmstrom SE, Frost P, Eisner ER: (1998) Exodontics, in *Veterinary Dental Techniques* (2 ed). Philadelphia, PA, Saunders, pp 238-242

Wiggs RB, Lobprise HB (1997) Oral Surgery, in *Veterinary Dentistry, Principles and Practice*. Philadelphia, PA Lippincott – Raven, pp 312-377

Taylor TN, Smith MM, Snyder L (2004) Nasal displacement of a tooth root in a dog. *J Vet Dent*. 21(4):222-5.

Blazejewski S, Lewis JR, Reiter AM: (2006) Mucoperiosteal flap for extraction of multiple teeth in the maxillary quadrant of the cat. *J Vet Dent*. 23(3): 200-305.

Woodward TM: Extraction of fractured tooth roots. (2006) *J Vet Dent*. 23(2): 126-9.

Smith MM. (1998) Exodontics in: *Vet clin N Am sm anim pract*. 28(5): 1297-319.

Moore JI, Niemiec B: (2014) Evaluation of extraction sites for evidence of retained tooth roots and periapical pathology. *J Am Anim Hosp Assoc*.50(2):77-82.

Niemiec BA (2008) Extraction Techniques. *Top Companion Anim Med*. 23(2):97-105.

Niemiec BA (2009) Case based dental radiology. *Top Companion Anim Med*.24(1):4-19.

DuPont G (1995). Crown amputation with intentional root retention for advanced feline resorptive lesions: a clinical study. *Journal of Veterinary Dentistry* **12**, pp:9–13.

- Kelly DJ, Ahmad M, Brull SJ. (2001) Preemptive analgesia I: physiological pathways and pharmacological modalities. 48(10):1000-10.
- Kelly DJ, Ahmad M, Brull SJ. (2001) Preemptive analgesia II: recent advances and current trends. *Can J Anesth.* 48(11):1091-101,
- Lanz GC: (2003) Regional anesthesia for dentistry and oral surgery. *J Vet Dent.* 20(3): 181-186.
- Hobson P: (2005) Extraction of retained primary teeth in the dog. *J Vet Dent* 22(2): 132-7.
- Smith MM, Smith EM, La Croix N, Mould J: (2003) Orbital penetration associated with tooth extraction. *J Vet Dent.* 20(1): 8-17.
- Harvey CE, Emily PP. (1993) Oral Surgery, in *Small Animal Dentistry*. Mosby, St. Louis, pp 213-265
- Niemiec BA (2014) Dental extractions made easier. Practical Veterinary Publishing, San Diego.
- Proffit WR, Fields HW (2000) *Contemporary Orthodontics* (ed 3). St. Louis, Mo, Mosby, pp 297-306.
- Niemiec BA (2015): Extractions. In: *Feline Dentistry for the General Practitioner*. San Diego, Practical Veterinary Publishing.
- Charmichael DT (2002): Surgical extraction of the maxillary fourth premolar tooth in the dog. *J Vet Dent.* 19(4): 231-3.
- Frost Fitch P: (2003) Surgical extraction of the maxillary canine tooth. *J Vet Dent.* 20(1): 55-8.
- Ulbricht RD, Marretta SM, Klippert LS (2003). Surgical extraction of a fractured, nonvital deciduous tooth in a tiger. *Journal of Veterinary Dentistry* 20(4): 209–12.
- Taney KG, Smith MM: (2006) Surgical extraction of impacted teeth in a dog. *J Vet Dent.* 23(3): 168-77.
- Evans, HE: (1993) The skeleton, in *Miller's anatomy of the dog* (3rd ed) Philadelphia, PA, W.B. Saunders, pp 122-218
- Grant DA, Stern IB, Listgarten MA (1988) Alveolar Process, in, *Periodontics*. St. Louis, MO, C.V. Mosby, pp 94-118
- Manfra Marretta S (2002) Surgical extraction of the mandibular first molar tooth in the dog. *J Vet Dent.* 19(1):46-50.
- Grant DA, Stern IB, Listgarten MA:(1998) Periodontal flap, in, *Periodontics*. St. Louis, MO, C.V. Mosby, pp 786-822
- Smith MM: (2003) Line angle incisions. *J Vet Dent.* 20(4): 241-244.
- Frost Fitch P (2003) Surgical extraction of the maxillary canine tooth. *J Vet Dent.* 20(1): 55-8.

Section 8: The university's role in dental education

The WSAVA Dental Standardization project committee highly encourages teaching veterinary dentistry in the university settings at both undergraduate and graduate levels.

Training in veterinary school

Although oral and dental disease is very common in small animals, veterinary dentistry is still largely neglected in the veterinary medicine curriculum in most universities. There are few veterinary faculties worldwide that include dentistry in the regular curriculum, and only a handful more offer veterinary dentistry as an elective/optional course, usually with limited enrolment (Perry 2014). Veterinary dentistry training in all universities should include, at minimum: lectures on oral and dental anatomy and physiology, oral/dental examination techniques (including dental radiography), and the most common pathology and diseases. In addition, hands-on wetlabs on oral/dental exam, dental radiography, periodontal treatment, regional anaesthesia and basic principles of tooth extraction should be provided. Rotations through the dentistry department of the teaching hospital should be made available to provide “day-1 competence” skills as described in detail in the “Joint EVDS/EVDC Statement on Clinical Competencies in Small Companion Animal Dentistry and Oral Surgery”. (Available also at: <http://www.evds.org/policystatements/day1skills>)

Veterinary dentistry as a specialty should be included in clinical activities to provide the necessary teaching environment with clinical cases for veterinary students. (Esteghamati et al. 2016) Establishing a veterinary dentistry department requires some investment in equipment; however, it is generally achievable in a cost-effective manner. (See equipment section) Moreover, veterinary teaching hospitals should strive to provide veterinary dentistry services at a specialist level. This can be achieved through employment of a Board-certified veterinary dentist (Dipl. AVDC, Dipl. AVDC-Eq, Dipl. EVDC, Dipl. EVDC-Eq) who provides clinical services as well as training to undergraduate and postgraduate (i.e. interns and residents) students. Alternatively, students should be given an option to complete their rotations in veterinary dentistry as externships with veterinary dentistry specialists in private practice. If no board-certified veterinary dentist is available in the country, a veterinarian with documented advanced training in veterinary dentistry (Fellow of the Academy of Veterinary Dentistry PhD, MSc or similar) should be included in teaching veterinary dentistry. (see CE section)

Postgraduate training

PhD training

A PhD is currently the highest degree achievable in postgraduate training, and emphasizes research. In the future, veterinary dentistry-focused PhD training programs should ideally be formed and followed by a residency or vice-versa to train clinician-scientists. (DeLuca et al. 2016)

Residency training

Residency in veterinary dentistry can currently be obtained through one of the two registered colleges worldwide - AVDC (American Veterinary Dental College, www.avdc.org) or EVDC

(European Veterinary Dental College, www.evdc.org). Residency training is clinically-oriented training, although a resident needs to be involved in some research activities.

To enter into residency training, a veterinarian needs to fulfill certain criteria as described by the AVDC (<http://www.avdc.org/register.html>) or EVDC

(http://176.32.230.22/evdc.info/?page_id=40). Usually at least 1 year internship (or the equivalent) is needed before enrollment. Once registered and in training, the resident has to

prove a high level of knowledge and clinical skill as described in detail in the AVDC or EVDC documents. It can take between 2.5 – 6 years (a minimum of 3 years for an approved standard residency training program, and a minimum of 5 years for an approved alternative residency training program in EVDC; a minimum of 78 weeks for any approved AVDC training program)

before the resident is eligible for the entry examination to the College. Only after the candidate successfully passes the practical and written examination are they awarded Diplomate status.

Ideally in the future, residency training is followed by or combined with PhD training (DeLuca et al. 2016, Esteghamati et al. 2016, Bourgeois et al. 2015)

Currently, the level of university involvement in veterinary dentistry training is poor to nonexistent. Establishing training and residency programs in veterinary dentistry should be one of the main priorities of veterinary faculties worldwide.

Key Points:

- Veterinary dentistry is a largely neglected field in the veterinary medicine curriculum in most of the universities.
- Teaching veterinary dentistry at an undergraduate level should include lectures and hands-on workshops on basic examination techniques, most common oral/dental diseases and treatments.
- Teaching hospitals should establish a veterinary dentistry department, striving at providing dentistry services at a specialist level to create the necessary teaching environment.
- Postgraduate training in veterinary dentistry should include residency training, ideally in the future combined with PhD training.
- Effective teaching of veterinary dentistry in the veterinary school is the key to progression in this field of veterinary medicine.

References:

Bourgeois, J. A., Hategan, A., Azzam, A. (2015) Competency-based medical education and scholarship: Creating an active academic culture during residency. *Perspectives on Medical Education* 4(5): 254-258.

DeLuca, G. C., Ovseiko, P. V., Buchan, A. M. (2016) Personalized medical education: Reappraising clinician-scientist training. *Science Translational Medicine* 8(321):321fs2.

Esteghamati, A., Baradaran, H., Monajemi, A., Khankeh, H. R., Geranmayeh, M. (2016) Core components of clinical education: a qualitative study with attending physicians and their residents. *Journal of Advances in Medical Education and Professionalism* 4(2):64-71.

Perry, R. (2014) Final year veterinary students' attitudes towards small animal dentistry: a questionnaire-based survey. *Journal of Small Animal Practice* 55(9):457-464.

The WSAVA's position on Non-Anesthesia Dentistry (NAD)

This document has a recurrent message, which is that anesthesia is required to perform any useful dental procedure. This includes a professional dental cleaning, a proper oral exam, dental radiology, extractions, and any other necessary therapy.

The ineffectiveness and inappropriateness of NAD has been brought up in almost every section, including anesthesia and welfare. This is because all authors of these guidelines agree that this is a completely worthless procedure. Not only does it provide no medical benefit, it is dangerous and stressful to the patient. Furthermore, because it cleans the surface of the teeth, it falsifies the results of the conscious oral exam. This is based on the fact that most clients and veterinarians base the need for professional care on the mistaken belief that the level of dental calculus is an accurate indicator of the level of disease. This gives clients (and veterinarians) a false sense of security that the procedure is effective.

Based on this lack of outward signs, definitive care is often delayed, resulting in these patients often suffering from chronic pain and infection. Veterinarians are forced to extract teeth with clean crowns on a regular basis because the area below the gums was not cleaned, and the infection continued.

For all the issues above, the WSAVA Dental Guidelines committee feels that NAD poses a significant animal welfare concern as well as being below the standard of care. Thus the WSAVA joins the following Veterinary Associations in vehemently opposing this practice.

International Societies:

- American Veterinary Dental College
- Academy of Veterinary Dentistry
- American Veterinary Dental Society
- European Veterinary Dental College (EVDC) <http://www.evdc.info>
- European Veterinary Dental Society (EVDS) <http://www.evdc.info>
- Federation of European Companion Animal Veterinary Associations (FECAVA)
<http://www.fecava.org/>
- American College of Anesthesia and Analgesia

National Societies:

American Animal Hospital Association
Australian Veterinary Association
Japanese Small Animal Dental Society

Europe:

Austria

- Austrian Society of Veterinary Dentistry (ÖEGTZ -Österreichische Gesellschaft für Tierzahnheilkunde)

Belgium

- Belgian-Dutch Scientific dental Society (NWTD -Nederlandstalige Wetenschappelijke Tandheelkundige Dierenartsenkring)

Croatia

- Croatian Small Animal Veterinary Section (CSAVS)

Czech Republic

- Czech Veterinary Dental Society (CVDS)

Finland

- Suomen Elinlääkripraktikot ry (SEP)
<http://www.sep.fi/>

France

- French Veterinary Dental Group (*GEROS*-Groupe d'Etude et de Recherche en Odontostomatologie)

Germany

- German Veterinary Dental Society (DGT – Deutsche Gesellschaft für Tierzahnheilkunde)
<http://www.tierzahnaerzte.de/>

Greece

- Hellenic Companion Animal Veterinary Society (HCAVS)

Ireland

Italy

- Italian Society of Veterinary Dentistry and Oral Surgery (*SIODOCOV*-Società Italiana Di Odontostomatologia e Chirurgia Orale Veterinaria)
<https://www.facebook.com/pages/Siodocov-Società-Italiana-di-OdontostomatologiaChirurgia-Orale-Veterinaria>

Netherlands

- Dental Working Group of the Netherlands (WVT -Werkgroep Veterinaire Tandheelkunde)

Norway

- Norwegian Small Animal Veterinary Association
<http://www.vetnett.no/svf>

Poland

- Dental Working Group in Polish Small Animal Veterinary Association

Portugal:

- Portuguese Society of Veterinary Dentistry (SPMEDVE – Sociedade Portuguesa de Medicina Estomatológico-dentária Veterinária e Experimental)
<http://www.spmedve.com>

Romania

- Romanian Society of Veterinary Dentistry (ARVS-Asociația Română Veterinară de Stomatologie)
<http://www.arvs.ro/>

Russia

- Russian Small Animal Veterinary Association (RSAVA)
- www.rsava.org

Slovenia

- Slovenian Small Animal Veterinary Association (SZVMŽ-Slovensko združenje veterinarjev za male živali)
- <http://www.zdruzenje-szvmz.si/>

Spain

- Spanish Veterinary Dental Society (SEOVE -Sociedad española de odontología veterinaria)
- <http://www.seove.com>

Sweden

- Swedish Veterinary Dental Society (SSDt)
- www.ssd.se

Switzerland

- Swiss Society of Veterinary Dentistry (SSVD)
- www.ssvd.ch

UK:

- British Veterinary Dental Association (BVDA)
- [http:// www.bvda.co.uk](http://www.bvda.co.uk)

In addition, the following Veterinary Medical Boards have regulations prohibiting its performance

- California VMB
- Nevada VMB
- Ontario (Canada) VMB
- Royal College of Veterinary Surgeons

Section 9: Necessary equipment

Oral Examination

Assessment of the conscious patient

The oral examination ought to be one of the most commonly performed procedures in small animal practice. WSAVA believes that an oral examination must be an integral part of any wellness examination. A systematic approach with examination of both normal and abnormal is necessary for a thorough oral examination.

Equipment required for a detailed intraoral conscious examination includes: adequate room lighting, magnification, and a pen light. It is advisable that the clinician wear examination gloves to assess the oral cavity, both to protect the veterinarian and patient, as well as to decrease the risk of infection transmission. While light may seem obvious, many clinicians attempt to perform an examination in a poorly lit room with the unaided eye, to less than satisfying results. A pen light (or oto/ophthalmoscope) can be used to improve visualization as well as to transilluminate the tooth to determine vitality.

Proper patient position should provide the mouth at an appropriate level for comfortable evaluation by the inspecting veterinarian (ergonomic positioning is advantageous).

Required equipment for conscious oral examination in tier 1, 2, 3 countries:

1. A good light source
2. Examination gloves

Examination under general anaesthesia

After general anaesthesia and intubation have been achieved, a complete and thorough oral examination can and should be performed. All dental procedures must be performed under general anaesthesia (see anaesthesia section)

Endotracheal intubation is critical for dental procedures. Further protection of the respiratory tract with a pharyngeal pack is recommended, as well as properly sized e-tubes to avoid tracheal injury. Use of a laryngoscope will aid with intubation and inspection of the oropharyngeal area.

(FIG)

Objects used to hold the mouth open and aid in visualization during a COHAT and other dental procedures performed should consist of appropriately sized props rather than spring loaded gags. Be aware of the risk of blindness with extended mouth opening in cats (Martin-Flores M et al 2014, Scrivani PV et al 2014, Barton-Lamb Al et al 2013).

- Temperature maintenance equipment:
 - Tier 1: hot water warming device
 - Tiers 3&2: Forced warm air device

- Anesthetic techniques: Inhalational anesthesia, total intravenous anesthesia (TIVA), access to oxygen for preoxygenation and further use during inhalation anaesthesia, equipment for local nerve blocks
- Anesthesia monitoring body temperature, recording of pulse, respiratory rate, recording of blood pressure, measurement of expired CO₂, (tiers 3,2)
- Additional equipment: IV infusion pump (tier 3)

Following induction of anaesthesia, the clinician should closely evaluate the soft tissues including the tongue, gingiva, mucosa, oropharyngeal and tonsillar areas. Next, assessment of the hard tissues (including maxilla and mandibles) and dentition, both as a whole and individually, should be noted, including any missing, rotated and/or fractured teeth. An assessment of periodontal health is then made including probing depths (up to 6 probing points per tooth), gingival recession and hyperplasia, mobility, furcation involvement and other oral pathology. Both normal and abnormal findings should be recorded on a dental chart. (See examination section)

Minimum equipment (Tier 1,2,3) required for a detailed intraoral examination includes:

1. A good light source
2. Magnification (e.g. loupes or magnifying glass)
3. Photography (camera or video - a mobile phone is acceptable)
4. Periodontal probe/explorer
5. Dental mirror
6. Lip retractor
7. Mouth gag (properly sized syringe case or plastic gag)
8. Personal protective gear (eyewear, mask and examination gloves)

Periodontal probes are used to measure the depth of the gingival sulcus and periodontal pockets. They are typically a metal or plastic tapered rod with a blunt end attached to a handle, with graduated millimeter markings. There are several types available. The Williams, Marquis, Michigan-O, UNC and Nabors, are commonly available. FIG

The probe allows the clinician to measure and assess gingivitis index (bleeding on probing), depth of the sulcus or pocket, degree of gingival enlargement and/or recession, and furcation exposure (in multi-rooted teeth).

An explorer is often found on the opposite end of the periodontal probe. It is a sharp tipped instrument that may be used by the clinician to explore calculus both supra- and sub-gingivally; dental defects such as resorptive lesions, pulp exposure, attrition, abrasion, lost enamel or dentine may also be assessed. FIG

A dental mirror is an important diagnostic aid for the assessment of the palatal or lingual surfaces of dentition as well as the caudal part of dentition. FIG

The lip retractor is used to improve the visualization of the caudal dentition either for assessment or for photography. It may be used during dental procedures to improve visibility of the surgical area. FIG

Another option for diagnosis are plaque disclosing solutions: the greater the thickness of plaque on the tooth surface, the darker the dye. The most common one stage dye is erythrosine. Prior to cleaning the teeth, a drop of 2% erythrosine is placed on the supra-gingival tooth surface and washed off with a gentle stream of water. Fluorescein may also be utilized. Another tool utilizes a blue light (approximately 405 nm wavelength) that causes mature plaque to glow red (due to porphyrins within the plaque). This quantitative light-fluorescence or QLF tool can be used in a darkened consultation room to demonstrate mature plaque. FIG

Radiology/Radiography

Oral radiology and radiography are important for adequate diagnosis and decision making in veterinary dentistry. Performing dentistry without radiography greatly increases the likelihood of missing pathology as well as creating iatrogenic trauma.

To produce a diagnostic radiograph, the necessary equipment includes an x-ray generator, dental film and developer solution, or a digital dental system and a computer with appropriate software. For dental purposes, it is always better to use dental X ray machine, however diagnostic images can be obtained with the use of the full body X-Ray and appropriate technique. It should be pointed out that full body radiographs will generally be of insufficient detail for proper dental diagnosis and are very difficult to expose. Therefore dental generators and intraoral film/sensors are always recommended. When radiographing small objects (i.e. toes) or small patients (e.g. pocket pets), the dental X-Ray machine may be utilized as a full body device. FIG

There are several options for obtaining diagnostic dental images:

- 1) Conventional veterinary x-ray generator (Tier 1)
- 2) Dental radiology generator plus:
 - a. Non-screen intra-oral dental film (Tier 2)
 - b. Phosphor – stimuable (PSP) plates (CR system)

c. Digital sensors (DR system)

Digital dental radiology should be used in all tier 3 countries.

Manual processing can be performed using wet chemistry within a dark-room (a room which has light blocked from entering it) or in a light proof chamber in daylight (termed a chair-side developer). These methods require the operator to place the film into tanks containing developer and fixer for a pre-determined time. The result is a wet film.

Processing can also be performed automatically, using an automatic processor. This which still utilizes wet chemistry, but internal rollers to move the film through the developer and fixer bathes at a set rate, and the film produced is dry.

Processing can also be performed using a computer software program that transmit the x-rays detected on a plate or sensor to a radiographic image on a computer screen.

Phosphor plates (CR technology) FIG

These are flexible polyester films that support photostimulable phosphor deposited in a resin on the surface. After the initial exposure, excited electrons in the phosphor material remain 'trapped' in centers in the crystal lattice until stimulated by the second illumination. These mobilized electrons release a blue-violet 400 nm luminescence produced in proportion to the number of trapped electrons which is in direct relationship to the original X-ray beam. It is then collected enabling the resulting signal to be converted into a digital image. Phosphorus plates are available in many sizes: from 0 to 4, are reusable and replacement is quite affordable.

Digital sensors (DR technology) FIG

There are numerous human and veterinary direct digital systems. These are excellent means of obtaining dental radiographs. The only major drawback is the lack of a number 4 plate with direct digital systems (sensors). The major advantages to the direct digital systems are the decrease in radiation exposure, rapidity of image creation, and the ability to reposition the sensor and/or tubehead if the view is not correct the first time.

Equipment to Clean Teeth

A. The basic PROPHY KIT (Tier 1) should contain:

Diagnostic instrumentation:

See above

Scaling instrumentation:

Tier 1:

1. Tartar removing forceps FIG,
2. A scaler (for supragingival scaling) FIG
3. A selection of curettes (for subgingival scaling) FIG
4. Sharpening stone and oil

Tier 2 & 3 should have the above plus:

1. A dental unit (high speed and low-speed) FIG
2. Mechanical scaling: sonic or ultrasonic (piezoelectric, magnetostrictive)
 - a. Appropriate supra and subgingival tips. FIG
3. Prophy paste/pumice FIG

Equipment for Supragingival scaling

Hand scalers

Hand scalers have a handle connected to a blade, which has a double-sided cutting edge that converges to a sharp point. The blade is triangular in cross section. The sharp blade is used to remove plaque, calculus and other deposits from the supra-gingival tooth surface. They are held in a modified pen type grasp. The blade is placed on the tooth surface at the gingival margin and used in a pull stroke that pulls the blade away from the gingiva. Hand scalers come in different patterns, one of which is the sickle scaler. The most common are the Universal (or H6/H7), the Jacquette and the Morse. FIG

Ultrasonic scalers

Ultra-sonic scalers are commonly used for removal of supra-gingival plaque and calculus. Ultrasonic scalers operate at >25kHz. The principle action of plaque and calculus removal is by a mechanical kick, or oscillation. This is achieved by the vibrating tip contacting the calculus and breaking it off. In addition, ultrasonic scalers create an effect called “cavitation” where the sound waves derived from physical vibrations of the tip energize the water spray, which then further cleans the tooth surface.

Ultrasonic scalers run via electricity and the working tip has one of three types of movement. The magnetostrictive type utilizes a stack of parallel nickel strips that lengthen and shorten when subjected to alternating electrical current. This causes the tip of the scaler to move in an elliptical figure eight motion. There are two classes of stacks, one vibrates at 25kHz, the other at 30 kHz. The ferrite rod type scalers use a rod, which vibrates by expansion and contraction. This causes the titanium scaler tip to move in a circular or elliptical fashion. Piezo electric scalers utilize a quartz crystal in the handle which expands and contracts when subject to alternating current. This causes the scaler tip to move in a linear back and forth motion. It vibrates at 25 to 45 kHz.

The handle of the ultrasonic scaler is held in a pen-like grip. FIG The tip is placed against the tooth surface at the gingival margin and in light contact with the calculus. The tip is moved using light strokes over the surface of the tooth. The operator should allow the vibrations to shatter the calculus. If the tip is used like a hand-held scaler, and force is placed against the calculus, the tip is likely to get damaged and stop oscillating.

Ultrasonic scalers can be safely used on any tooth surface that you can visualize. The tip of the magneto-strictive and piezo scaler become very hot with normal use. Coolant is absolutely required to prevent this from overheating the tooth and causing painful pulpitis and possible tooth death. The water spray should be directed at the end of the tip to dissipate heat. Care must be taken at all times to make sure the coolant is reaching the tip properly, especially if the

ultrasonic is used sub-gingivally. Properly designed subgingival tips will allow the water coolant to get to the tip and be used subgingivally.

If the ultrasonic scaler does not remove the calculus from the developmental ridges and cusps, a hand-held scaler should be employed.

Sonic scalers

Sonic scalers work using high-pressure air from a compressor or gas cylinder. The sonic scaler has a working tip that vibrates at 18-20 kHz and produces less heat when compared to ultrasonics. They usually have a jet of water spray for cooling the tooth and flushing away debris. The advantage is the reduced harm to the tooth via overheating or frequency of tip vibrations, but they can be slower with heavy calculus build-up and they may cause more tooth damage

Sub-gingival scaling (root planing) and curettage

While scaling only the tooth crown results in an aesthetic result for the owner, it does not provide any measurable medical benefit for the treatment or prevention of periodontal disease. Complete treatment of established periodontal disease requires sub-gingival scaling and curettage. The term root planing is used to describe scraping the necrotic cementum from the root surface while curettage describes the removal of epithelial cells, endotoxins and accumulations from the epithelial wall lining the pocket.

Subgingival debridement and sub-gingival curettage can be performed using ultrasonic and sonic scalers (with proper subgingival tips) or hand instruments termed curettes.

Traditionally, human dentists have used hand instruments for root planning and sub-gingival curettage. There are two types of curettes, the Universal and the area-specific. The Universal type, which Columbia and Barnhart are examples, have two cutting surfaces, a rounded toe and a blade with cutting surfaces angled at 90 degrees to the handle. **FIG** The area-specific type, which Gracey is an example, has a rounded toe and a single sided cutting blade which is angled at 70 degrees to the shaft (the part of the instrument between the cutting blade and the handle). **FIG** In addition to the 70 percent offset angle, Gracey curettes also have an accessory bend at the shank which allows proper adaption to various teeth. These curettes come in a variety of angulations from 1-18. The higher the number, the greater the accessory bend and the further back in the mouth the instrument is designed to be used.

Instrument sharpening

It is mandatory that scalers and curettes are kept sharp. A blunt or dull blade will not remove accumulations and will burnish the calculus against the tooth root surface. Sharpening is a skill that takes time to master, and if one person in the clinic can sharpen well, your dentistry will improve. [Sharpening instructions should be referred to textbook or website]

Polishing

Polishing the tooth surface following scaling removes any microscopic plaque and calculus and provides a smooth tooth surface that retards the re-attachment of plaque and calculus. Supra-gingival scaling and root planing, even when done correctly, will leave a slightly roughened enamel surface that will encourage plaque reattachment. Polishing is performed by applying an

abrasive paste in a cup to the tooth surface. Pressure on the polishing cup will flare the edges, which can then be directed slightly under the gum to polish sub-gingivally. **FIG**

Generally speaking, there are two types of polishing actions. The traditional cup, which rotates continuously at 3,000 rpm and the newer type of cup with a reciprocating action, back and forward. The cups should not be applied to the tooth surface for greater than 3-5 seconds duration as the heat generated can cause an increase in dentine temperature and an irreversible pulpitis. Pastes are available in different flavours and grades. Fine grades produce a smoother finish, whereas course grades will remove more enamel and produce a rougher surface. It is also possible to purchase paste in a multi-use jar or individual caplets. The same prophy cup should not be repeatedly dipped into the multi-use jar during teeth polishing, as it will become contaminated. The paste can be placed into separate dappen dishes for each patient. A new cup should be used for each patient. There is also possibility to prepare the polishing paste chairside from of pumice powder and water.

Extractions/oral surgery

Tooth extraction is one of the most common surgical procedures performed by veterinarians in small animal practice. While repair of fractured jaws, closure of oro-nasal fistulas and removal of oral tumours are generally considered oral surgery, extraction of a tooth is a surgical treatment and procedure that should be perfected by all practitioners.

The ideal tooth extraction is the removal of the complete tooth and all roots with minimal trauma to the surrounding soft and hard tissues. This concept of minimally invasive surgery results in a wound that heals quickly and without complications. Tooth extraction requires the veterinarian to have a detailed knowledge of anatomy, wound healing and suturing, proper dental materials and equipment, as well as technique to accomplish the procedure. Every veterinarian should endeavour to make every tooth extraction an ideal one.

Oral surgery kit **FIG.**

Extraction instrumentation

1. An assortment of luxating elevators (luxators) for cutting the periodontal ligament. The luxator consists of a handle, shaft and a working end. The working end has a concave surface and opposing convex surface, straight sides and a sharp end perpendicular to the instrument long axis. The blade comes to a fine/sharp tip. **FIG.**
2. Elevators are used for tearing the periodontal ligament and elevating the tooth. The traditional elevator is termed 'straight'. It consists of a handle, shaft and working end. The working end consists of a blade with parallel sides, a concave and opposing convex surface with a rounded tip. The tip may be sharp or blunt. **FIG.**
3. Extraction forceps are used for removing the loosened tooth from the alveolus. Extraction forceps have two handles and two beaks, which are opposed when the handles are

squeezed together. The beaks are used to grasp the tooth crown in order to extract it from the alveolus. FIG.

A basic soft-tissue oral surgery kit includes:

1. Scalpel handle
2. Tissue forceps
3. Periosteal elevators
4. Tissue scissors
5. Suture scissors
6. Needleholder
7. Lip retractor

Note that a variety of sizes of the above equipment should be available for cats, medium and large breed dogs.

Tier 1 country should have:

1. Soft tissue oral surgery kit
2. Elevators or luxators
3. Extraction Forceps
4. Some method for sectioning teeth

Tier 2 & 3 should have the above plus:

1. High speed dental unit and handpiece with assorted burs
 - a. For sectioning teeth and cutting dental hard tissue

All equipment should be sanitized, disinfected and/or sterilized based on the category of each item's intended use (e.g., non-critical, semi-critical or critical) (Terpak and Verstraete 2012) (Figure)

FECAVA Key Recommendations for Hygiene and Infection Control in Veterinary Practice



PREVENT INFECTION

Effective implementation of hygienic measures is essential to prevent and contain the transmission of nosocomial infections to animals and humans both within veterinary settings and in the community.

<p>CLEAN AND DISINFECT HANDS</p> <p>The most important activity in the control of nosocomial infections is hygiene.</p> <p>WASH HANDS</p> <ul style="list-style-type: none"> At the start and end of the working day After visiting the toilet Before and after eating or smoking When visibly soiled After handling animal fluids and excretions Before aseptic or invasive procedures in combination with disinfection <p>DISINFECT HANDS (use alcohol based hand sanitizers 70-80%)</p> <ul style="list-style-type: none"> That are dry and clean Before and after handling each patient Before and after gloving Before touching equipment, door handles and keyboards <p>No jewelry (rings, bracelets, watches, nail polish) or false nails should be worn. Nails should be kept short and clean.</p>	<p>WEAR PROTECTIVE CLOTHING</p> <p>To ensure that fluids and excretions can be kept clean their short-sleeved lab coats or scrubs should be worn at all times when handling animals. Protective clothing should not be worn outside the working environment.</p> <p>ADDITIONAL PROTECTIVE CLOTHING</p> <p>Masks, hair caps, shoe covers and gowns should be used for surgical and invasive procedures.</p> <p>Plastic aprons, gloves and masks are required when handling:</p> <ul style="list-style-type: none"> Patients with known or suspected contagious disease Potentially contaminated fluids and excretions <p>Change the additional protective clothing:</p> <ul style="list-style-type: none"> Between patients When moving between rooms, isolation and intensive care units. 	<p>CLEAN AND DISINFECT PREMISES</p> <p>Use approved cleaning products and disinfectants for veterinary premises, and follow label instructions. Use gloves. For respiratory, follow the instructions from the manufacturer.</p> <p>SURFACES AND EQUIPMENT</p> <ul style="list-style-type: none"> Clean and disinfect before and after each patient and when visibly soiled or contaminated. Clean and disinfect door handles, keyboards, light switches and telephones on a daily regular basis. <p>COMMON AREAS (RECEPTION, WAITING ROOMS AND CORRIDORS)</p> <ul style="list-style-type: none"> Clean and disinfect daily and when visibly soiled or contaminated. <p>WARDS, ISOLATION AND INTENSIVE CARE UNITS</p> <ul style="list-style-type: none"> Clean and disinfect before and after each patient and when visibly soiled or contaminated. 	<p>TRAIN STAFF</p> <p>Train and encourage all staff to understand and comply with good hygiene practices. Correct hygiene is not difficult if everyone is aware of its importance.</p> <ul style="list-style-type: none"> Develop written hygiene protocols (checklist primary) and appoint a member of staff with responsibility for promoting and enforcing hygiene practices. Establish thorough in-house training of staff and encourage attendance at continuing education courses, or hygiene.
<p>USE GLOVES</p> <ul style="list-style-type: none"> When handling diseased or cancer animals with known or suspected contagious disease, including respiratory infections When handling animals with known or suspected zoonotically transmitted infections When handling all animals When contact with blood, body fluids, excretions, secretions and mucous membranes is possible During surgery or when asepsis is required (sterile gloves) Change gloves between each individual patient and when visibly contaminated Change gloves when moving from dirty to clean procedures on the same patient Change gloves before handling equipment, door handles and keyboards <p>Wearing gloves is not a substitute for hand hygiene!</p>	<p>SURGICAL PREPARATION</p> <ul style="list-style-type: none"> The operating room must only be used for surgical procedures. Clips don't touch surgical sites Temperature: maintain between 18°C and 22°C Wash preparation after clipping using antiseptic soap with water followed by alcohol 5% chlorhexidine Surgeon must scrub in with mild soap & alcohol based hand sanitizer (70% ISA) according to practice protocols Protective clothing ("sterile") must be used during surgery. Scrubs used in other areas must not be worn in the surgical suite Only use antiseptic disinfectants: Activated Povidone, Cold disinfection only under exceptional circumstances Prevent animal contact, movement or otherwise surrounding the surgical site Replace towels and bandage changes with clean or sterile linens 	<p>LAUNDRY CLOTHING AND DRESSING</p> <ul style="list-style-type: none"> Soiled and lab coats - daily and when visibly soiled or contaminated Washing and ironing on daily between each patient and when visibly soiled or contaminated Laundry should be done on the premises or by a professional company Remove any gross visible soiling contamination prior to washing (use gloves) Wash at 60°C and dry at high temperature to eliminate potential pathogens Minimize direct separation between dirty and clean areas in laundry room to avoid cross-contamination Store clean laundry in dedicated areas 	<p>EDUCATE PET OWNERS</p> <p>Use printed documentation (leaflets, posters) to focus these communications.</p> <ul style="list-style-type: none"> To ensure good hygiene practices during clinical visits and following referral with their animal in their homes To support veterinary efforts in improving hygiene and responsible use of antimicrobials with good adherence to prescribed therapies To convey better understanding of the public health importance of zoonotic and zoonotically resistant infections in pets.

FECAVA WORKING GROUP ON HYGIENE AND THE USE OF ANTIMICROBIALS IN VETERINARY PRACTICE © OCTOBER 2014

Suture Material

Absorbable suture is recommended for oral surgery because suture removal within the mouth is challenging to impossible. Monofilament suture is preferred to braided as it causes the least irritation and is associated with the least amount of infection. Polyglecapron 25 is the most popular material among veterinary dentists, but there are other options such as polyglactin 910 and chromic gut (where available).

As far as suture size, in general 4/0 to 5/0 is recommended for cats and 4/0 -3/0 for dogs. Suture needles for oral surgery must be the swaged-on type. Needle curvature is either 3/8 or 1/2 with the latter more indicated in the caudal part of the oral cavity. A reverse cutting needle is the best for suturing gingiva and mucosa but for friable mucosa, a taper point may be effective. The needle should be inserted into tissues perpendicularly to make the smallest possible entry wound and to avoid tearing of the mucosa.

Double layer suturing in major surgical procedures is preferred to one layer if possible. A distance of 2-3 mm between the wound edge and the suture entry point and a 2-3mm distance between interrupted sutures is recommended. A single interrupted suture is recommended in most oral procedures, although some authors suggest the use of continuous sutures after total extractions in stomatitis patients reduce the time of closure and decrease surgical time. Tension free sutures are of the utmost importance. The knot should not be placed directly over the incision. No area of denuded bone should be left uncovered and the suture line should not lie over the defect.

Key Points:

- All equipment as well as dental operatory should be sanitized, disinfected and/or sterilized on regular basis
- Dental/oral procedures require use of specific instruments and equipment
- The most common dental procedures (diagnostic, prophylaxis and extractions) cannot be properly performed without access to radiographic equipment

References

Martin-Flores M, Scrivani PV, Loew E, Gleed CA, Ludders JW (2014) Maximal and submaximal mouth opening with mouth gags in cats: implications for maxillary artery blood flow. *Vet J.*;200(1):60-4.

Scrivani PV, Martin-Flores M, van Hatten R, Bezuidenhout AJ. (2014) Structural and functional changes relevant to maxillary arterial flow observed during computed tomography and nonselective digital subtraction angiography in cats with the mouth closed and opened. *Vet Radiol Ultrasound.* 55(3):263-71.

Barton-Lamb AL, Martin-Flores M, Scrivani PV, et al (2013) Evaluation of maxillary arterial blood flow in anesthetized cats with the mouth closed and open. *Vet J.* 196(3):325-31.

Bellows J. *Small Animal Dental Equipment, Materials and Techniques* Blackwell, 2004

Crossley DA, Penman S. *Manual of Small Animal Dentistry* BSAVA 1995

Holmstrom SE, Frost P, Eisner ER. *Veterinary Dental Techniques for the Small Animal Practitioner*, 3rd ed. Philadelphia: WB Saunders, 2004.

Mulligan TW, Aller MS, Williams CA. *Atlas of Canine and Feline Dental Radiography*, Trenton. Veterinary Learning Systems, 1998.

Tutt C. *Small Animal Dentistry a manual of techniques* Blackwell Publishing 2006

Wiggs RB, Lobprise HB. *Veterinary Dentistry: Principles and Practice*, Philadelphia: Lippincott-Raven, 1997.